

# Pre-excitation of the Right Branch of the Bundle of His

## A NEW ELECTROCARDIOGRAPHIC SYNDROME

F. H. N. SPRACKLEN, A. C. WITHAM, W. BECK

### SUMMARY

A patient with an ECG exhibiting a short P-R interval followed by a QRS resembling complete left bundle-branch block (CLBBB) is presented. The Wolff-Parkinson-White (WPW) syndrome complicated by left bundle-branch block was suspected. The vectorcardiogram (VCG) closely approximated that of CLBBB but the characteristic delta segment of WPW conduction was absent. Subsequently, typical delta vectors appeared, and upon abolition of pre-excitation with procainamide, no LBBB was found. Evidence is assembled that a James bundle-like bypass was responsible for the accelerated atrioventricular (AV) conduction in the first tracings with transmission directly into the right bundle system causing functional LBBB; later, the impulse was re-routed either directly or via Mahaim fibres into septal muscle, creating a typical WPW-QRS loop. Six other possible mechanisms for the short P-R-CLBBB pattern are discussed.

*S. Afr. Med. J.*, 48, 1790 (1974).

According to Pick and Fisch,<sup>1</sup> the incidence of the pre-excitation syndrome with bundle-branch block should be expected in only about 0,0024% of routine ECGs. The association between these two conditions (one probably congenital and the other acquired) is usually assumed to be fortuitous. In a recent review, 14 examples of the Wolff-Parkinson-White (WPW) syndrome and left bundle-branch block (LBBB) were cited.<sup>2</sup> The case to be reported was thought to have this rare combination at first. Spontaneous and induced changes in the QRS complex, however, suggested that the apparent LBBB was due to direct pre-excitation of the right bundle.

### CASE REPORT

The patient was a 9-year-old Black girl with severe rheumatic mitral insufficiency who was first seen in the

Cardiac Clinic, Department of Medicine, Groote Schuur Hospital, Cape Town

F. H. N. SPRACKLEN, M.B. CH.B., M.D., M.R.C.P.

A. C. WITHAM, M.D., F.A.C.C., Professor of Medicine, Medical College of Georgia, Augusta, Georgia, USA

W. BECK, M.Sc., M.B. CH.B., M.MED., F.R.C.P.

Date received: 3 May 1974.

Reprint requests to: Dr F. H. N. Spracklen, Cardiac Clinic, Groote Schuur Hospital, Observatory, Cape.

Cardiac Clinic on 9 July 1969. She had been increasingly breathless on exertion from the age of 7 years. Recently there had been nocturnal dyspnoea. There was no history of paroxysmal tachycardia. The signs of severe mitral incompetence with a large left ventricle were found. Chest radiographs showed marked cardiomegaly mainly affecting the left atrium and left ventricle with pulmonary venous congestion. The patient was receiving digitalis. The initial ECG and Frank lead vectorcardiogram (VCG) are shown in Figs 1 and 2. The late negativity of the P wave in V1 was compatible with left atrial enlargement. Although the QRS complex was 0,16 sec in duration and strikingly resembled complete left bundle-branch block (CLBBB), the P-R interval was only 0,08 sec and there seemed to be delta waves best seen in aVF, V4, and V5. In view of their location, and the rS configuration of V1, the tentative interpretation was type B pre-excitation, possibly with CLBBB.

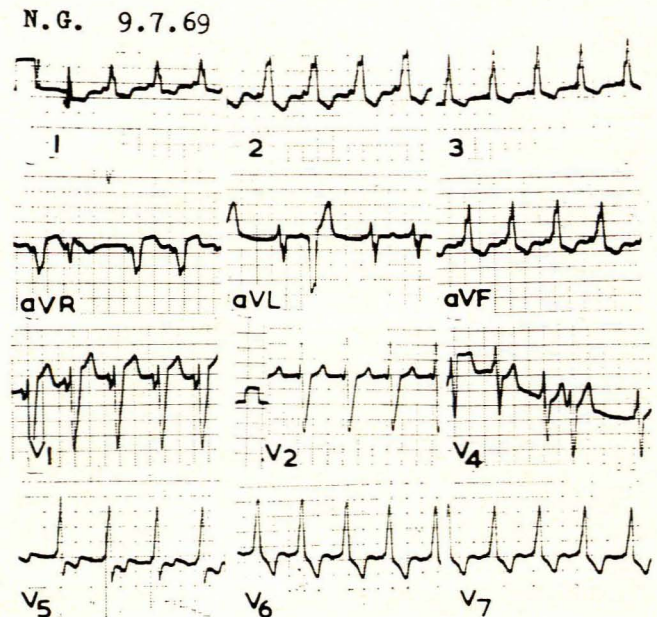


Fig. 1. ECG and VCG (Frank) at first visit (9 July 1969). The general appearance is that of CLBBB, but the P-R interval is 0,08 sec and delta waves (best seen in V4 and V5) are present. The premature beats, when present, usually resemble the other complexes.

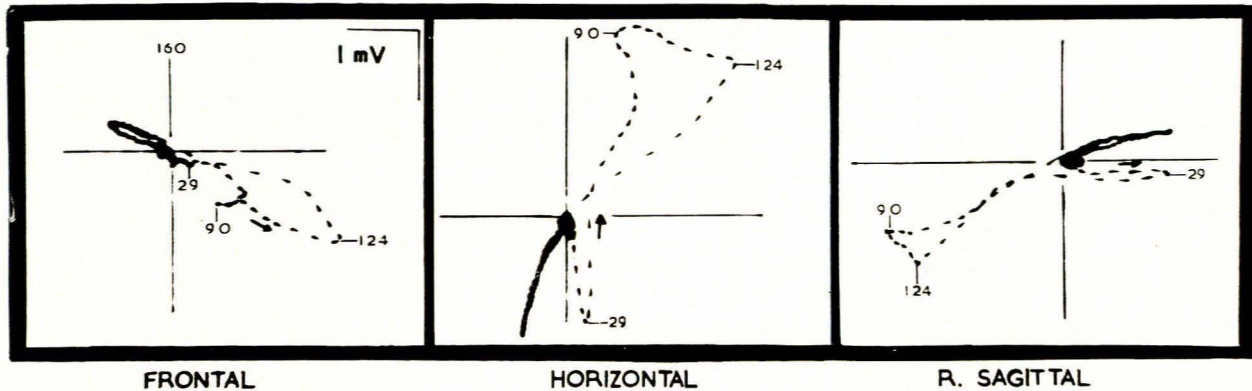


Fig. 2. Time breaks occur at 4 msec intervals. Total QRS duration is 160 msec. Important points on the loop are marked in msec. The features of CLBBB are present. The Q vector, however, is of unusually large voltage and duration. Initial slowing, typical of the conventional pre-excitation syndrome, is not present.

The VCG also resembled CLBBB. Horizontal and sagittal planes revealed the 4 cardinal features of this condition: (i) initial leftward anterior vector, followed by; (ii) rapid posterior movement; (iii) sharp slowing of inscription of loop near the maximum posterior excursion; and (iv) figure-of-eight configuration with a more rapid afferent limb.<sup>3</sup>

The diagnostic feature of WPW conduction, however, was absent. This finding is the identification of a true delta vector, a characteristic slowing of the initial QRS loop in the 3 planes.<sup>4</sup> The 'delta' waves in the ECG seemed to be artefacts of the position of the large first vector (Q) relative to the axes of leads aVF, V4, and V5. Initial slurring in left precordial leads is, of course, not rare in ECGs showing CLBBB. The Q vector in this first VCG was exaggerated, however, compared with typical CLBBB. In the horizontal plane it measured 1,45 mV and lasted 29 msec. Comparable average figures (Frank system) in CLBBB are 0,14 mV and 8 msec.<sup>3</sup> Thus, at this point, only a short P-R interval, followed by somewhat atypical left bundle-branch block complexes, was established.

ECGs remained stable until successful mitral annuloplasty was performed on 22 July 1969. The patient was seen for postoperative evaluation on 23 September 1969. She showed no signs of heart failure but was still receiving digitalis. The P-R interval was still 0,08 sec but the configuration of the P wave was quite different (Fig. 3). The P vector had shifted leftward and the P wave in V1 was entirely negative. The QRS complex was also slightly different and was shorter in duration (0,15 sec). The 'delta' wave was prominent only in V4. These changes were more evident in the VCG (Fig. 4). The first 100 msec were now slowly inscribed in all planes and characteristic of the delta vector of the conventional WPW syndrome. The timing of the Q vector in the horizontal plane remained at 28 msec but the voltage had halved (0,68 mV), indicating slower inscription. The Q vector in this plane had also moved 16° to the right. Following the Q vector, the second segment of the loop in the horizontal plane was now written more slowly and had shifted laterally. After 104 msec the loop was completed quite rapidly (seen best in the frontal plane),

and did not show the mid-loop slowing necessary for the diagnosis of high-grade left bundle block. In fact, the only remaining feature suggesting this entity was the non-specific figure-of-eight configuration in the horizontal plane.

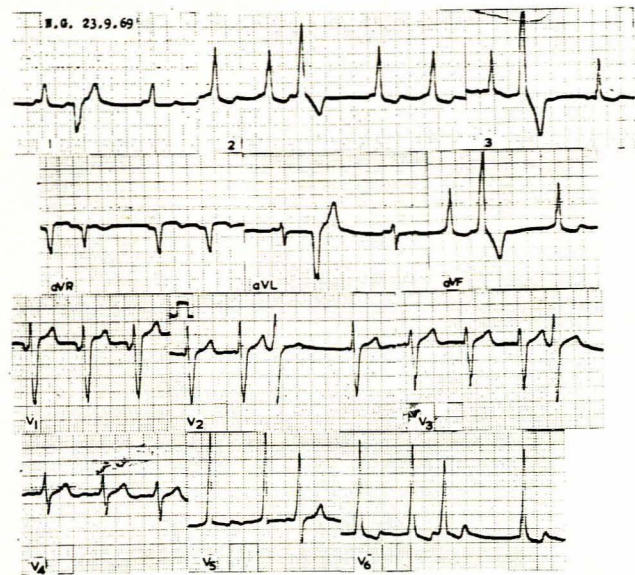


Fig. 3. ECG and VCG at second visit (23 Sept. 1969). The morphology of the P waves has changed but the P-R interval is the same (0,08 sec). The QRS complexes are less typical of CLBBB.

After receiving atropine, the patient's heart rate increased to 150 beats/min. The P-R interval remained at 0,08 - 0,09 sec. The QRS loop changed further (Fig. 5). The Q vector remained approximately the same, but the initial slowing or delta segment decreased to 76 msec and the body of the loop became even less posterior in position. Rotation in the horizontal plane was now completely normal and no evidence of CLBBB remained.

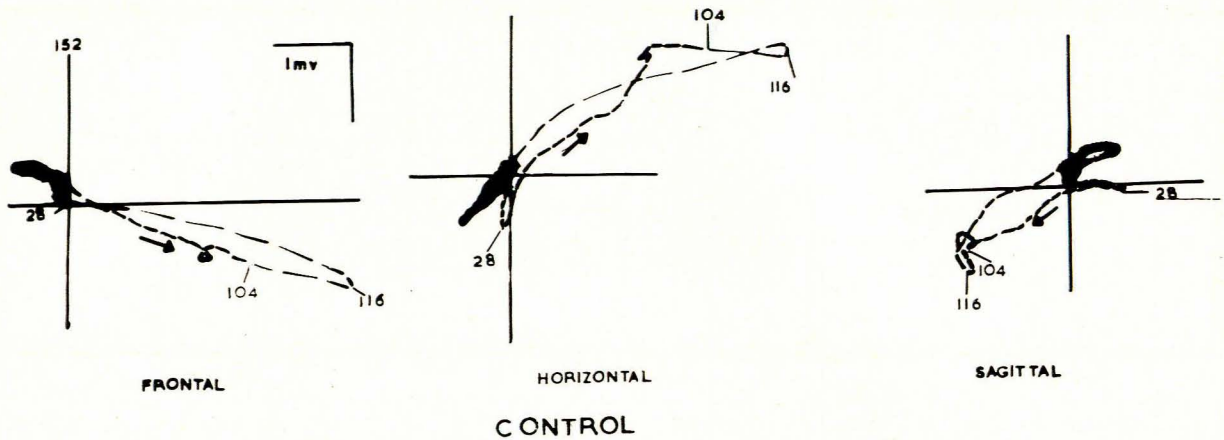


Fig. 4. Time intervals as in Fig. 2. Total QRS duration is 152 msec. The duration of the Q vector is unchanged. Q is of lower voltage, however, has shifted  $16^\circ$  to the right, and is part of a slow component lasting 104 msec consistent with the WPW syndrome. The only feature suggestive of CLBBB is the figure-of-eight configuration in the horizontal plane.

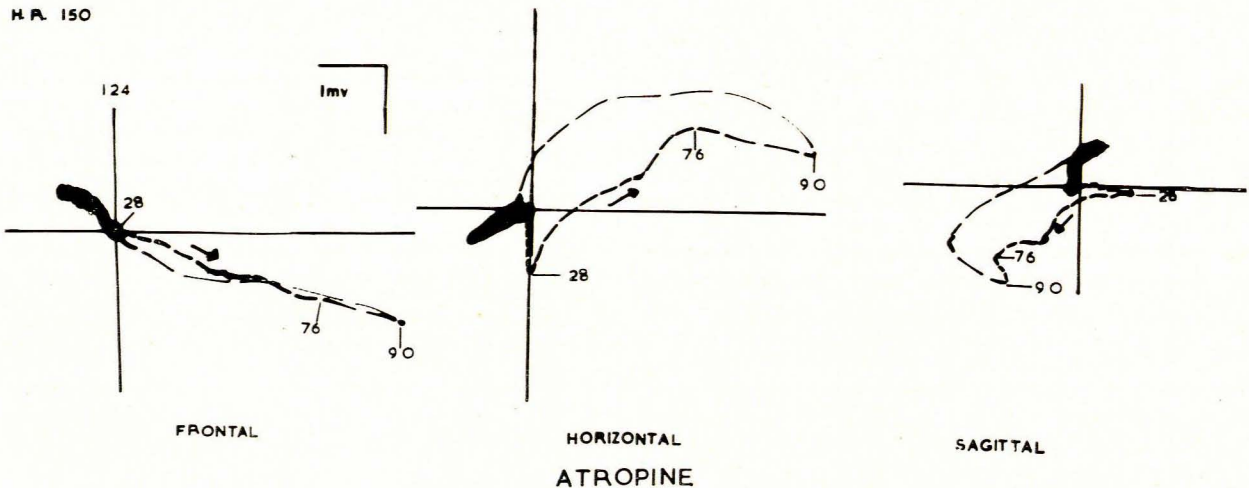


Fig. 5. After atropine the heart rate rose to 150/min and this VCG was recorded. The more rapid transnodal conduction has diminished the extent of pre-excitation but not abolished it. The QRS duration has shortened to 124 msec and the initial slow component now lasts only 76 msec. Rotation in the horizontal plane is normal. There is nothing to suggest an associated LBBB.

The patient was seen again on 23 February 1970. At this time the ECG and VCG had changed little from the control tracings of 23 September 1969 (Figs 3 and 4). The patient was given 300 mg of procainamide intravenously over a 5-minute period. This resulted in the temporary disappearance of any features suggesting either WPW conduction or LBBB. The tracings were typical of left atrial and left ventricular hypertrophy (Figs 6 and 7).

## DISCUSSION

The first ECGs and VCGs exhibited a short P-R interval followed by a broad QRS with features resembling LBBB.

This unusual combination suggests at least 7 possible interpretations. These will be mentioned, and their relevance in this case will be briefly discussed.

**Conventional pre-excitation of the WPW type.** This was the initial impression because of the apparent delta waves in the ECG, but the first VCG (Fig. 1) indicated that this was not true. A slowly transcribed initial (delta) segment is the diagnostic feature of WPW conduction in the VCG<sup>4</sup> and was not present. Its later appearance (Figs 4 and 5) makes it highly likely, however, that the short P-R interval was related to some type of pre-excitation.

**Pre-excitation of the WPW type with organic LBBB.** This possibility was excluded by the aforementioned absence of a typical delta vector and the subsequent

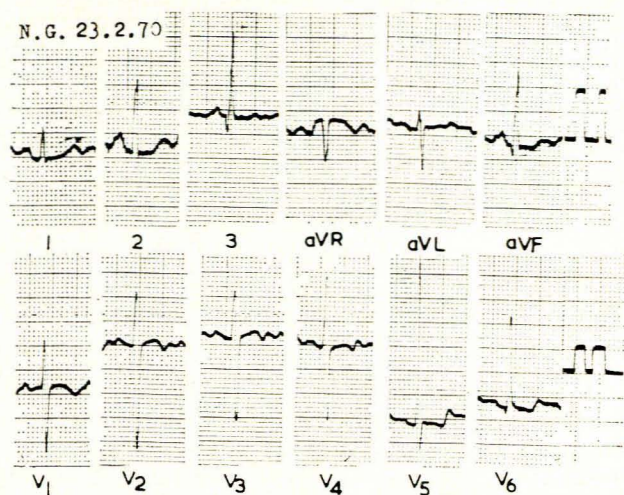


Fig. 6. ECG at third visit after procainamide. Marked left atrial and left ventricular enlargement. There is no evidence of pre-excitation or LBBB. Changes attributable to digitalis and procainamide are evident in ST segments and QT intervals.

finding that organic LBBB did not, in fact, exist (Figs 3-7). VCGs from patients proved to have this rare combination may retain features of both by exhibiting a typical delta segment followed by the mid- to late-loop delay characteristic of LBBB.<sup>5</sup>

**Pre-excitation of the Lown-Ganong-Levine (LGL) type associated with organic LBBB.** Although this syndrome ordinarily exhibits a normal QRS complex, its fortuitous occurrence with BBB might be expected occasionally, and an example (RBBB) was illustrated in the original description.<sup>6</sup> Although longitudinal dissociation of conduction velocity within the atrioventricular (AV) node cannot be excluded, recent studies combining atrial pacing and His bundle ECGs are compatible with the theory that the rapid AV conduction in the LGL syndrome is dependent upon a paranodal tract entering the lower AV node or upper His bundle.<sup>7,8</sup> The 'James bundle' fulfils the anatomical requirements for this route.<sup>9</sup> Although spontaneous transformation from the LGL to the WPW pattern, as might have happened in this case, must be very rare, increasing transnodal conduction time by rapid atrial pacing has unmasked an extranodal AV conduction route and produced typical WPW complexes in an occasional case.<sup>8</sup> This interpretation for the first ECG and VCG was not unreasonable, even though the LBBB was slightly atypical. It became untenable, however, when it was shown that organic LBBB was not present.

**Atrial rhythm with organic or rate-dependent left bundle block.** Massumi *et al.*<sup>5</sup> have described a patient who seemed to have the LGL syndrome in whom intracardiac ECGs indicated that the normally appearing P waves were apparently generated by a focus in the right atrial wall. The A-H interval responded normally to atrial pacing and the short P-R interval was due to the low atrial origin. LBBB aberration appeared with early induced beats. Although this explanation is unlikely, since an accessory pathway was later established by the appearance of WPW conduction, it is conceivable that the short P-R

intervals were caused by different mechanisms at different times.

**Sino-atrial delay, normal sinoventricular conduction and organic left bundle block.** This concept envisages that the short P-R interval is an artefact of a late P wave resulting from delayed escape of the impulse from the sinus node into the atrial muscle (sino-atrial block) coupled with a normal transmission time to the AV node via the specialised internodal conduction pathways.<sup>10</sup> There are retrospective arguments against this possibility. Incomplete sino-atrial block with normal sinoventricular conduction is usually temporary and has been established most convincingly in the presence of hyperkalaemia. This did not exist nor, of course, did organic LBBB.

**Two independent but synchronised pacemakers,** one in the sinus node or atrium, and the other either in the right ventricle (LBBB pattern) or in junctional tissue with either true LBBB or aberration, were suggested. This explanation seems far-fetched in that in nearly all cases of synchronisation, the ventricular beat triggers (or precedes) the atrial contraction rather than follows it, as in this case. None of the numerous ECGs recorded over many months exhibited any evidence of AV dissociation or block, which are the expected settings in which synchronisation tends to appear.<sup>11</sup>

**Pre-excitation of the right bundle.** This interpretation of the first ECG seems most consonant with subsequent records, for several reasons. Firstly, the short P-R interval is almost certainly due to pre-excitation because of the later appearance of delta vectors typical of the WPW syndrome coupled with the expected pharmacological responses of WPW, i.e. partial normalisation with atropine and restoration of normal AV and QRS conduction with procainamide. Secondly, the LBBB pattern must have been functional rather than organic since it was not present with normal AV conduction. Thirdly, the first VCG gave no indication that the rapidly conducted impulse entered the ventricular muscle directly. The slow transcription of the delta segment in WPW is considered to reflect non-Purkinje (fibre-to-fibre) conduction, but it was not seen. Fourthly, the proximity of the James bundle to the right bundle in James' reconstructions is noteworthy.<sup>9,12</sup> This tract, an extension of the posterior internodal pathway, has several possible functional connexions around the AV node and in the septum. His bundle ECGs and atrial pacing indicate that this route, or something very much like it, can account either for the short P-R normal QRS pattern (when it connects with the His bundle), or a WPW complex (if it delivers the impulse into the muscular septum directly or via the His bundle and a Mahaim fibre).<sup>7</sup> Fifthly, direct stimulation of the right bundle system would be expected to produce the LBBB pattern. Ventricular beats induced by endocardial pacing from the right ventricle regularly produce VCGs closely approximating those of CLBBB.<sup>13</sup> Most also have an initial slurring comparable to the delta segment of WPW beats and thus resemble pre-excitation with CLBBB. A few, however, lack the 'delta' segment, presumably due to a more direct stimulation of right bundle tissue. It is especially relevant that in such cases the simulation of organic LBBB is not perfect. The discrepancies are mainly in the

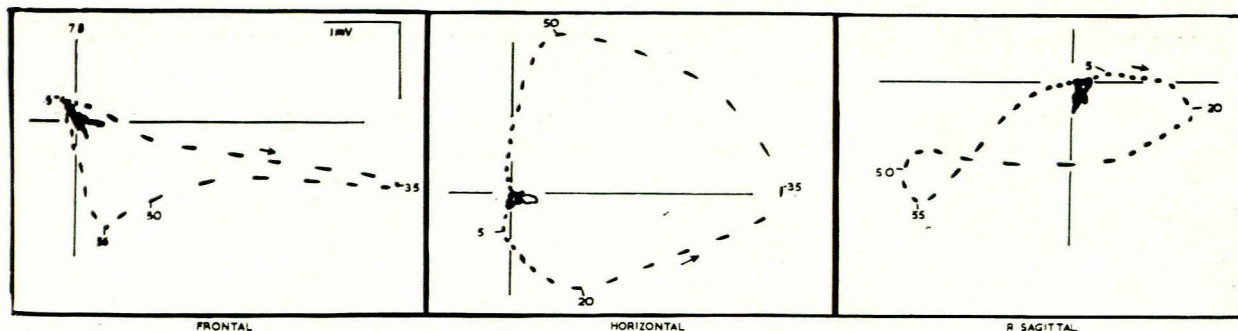


Fig. 7. VCG at third visit after procainamide.

details of the initial vector, possibly depending upon the exact point of entry into the right bundle system. The first VCG in this patient (Fig. 2) is also atypical for true CLBBS in the size and duration of the initial vector.

The exact anatomical bypass in this case cannot, of course, be proved. If His electrogram-atrial pacing techniques had been available, evidence for or against James bundle (in the electrophysiological sense) might have been obtained. The A-H interval (time between low right atrium and His spike) would have been short and not prolonged by rapid atrial pacing as occurs when the His bundle is activated by normal transnodal conduction. In contrast, if the pre-excitation was due to a bypass remote from the AV node (Kent-type bundle) which excited ventricular muscle directly, the normal lengthening of the A-H interval would be expected.<sup>7</sup>

Close comparison of the P waves preceding the QRS complexes exhibiting CLBBS, WPW, and normal conduction (Figs 1, 3 and 6) indicate different morphology in each instance. It is an old observation, recently reviewed, that some patients with intermittent WPW only show pre-excitation after P waves of a certain configuration.<sup>14</sup> A possible interpretation is that the WPW beats are, in fact, generated by a shift in position of the atrial (or sino-atrial) pacemaker which favours the posterior internodal-James tract conduction. Alternatively such an ectopic atrial focus might create an eccentric wave front emerging from the AV node which makes pre-excitation in a Mahaim fibre more likely. The frequency with which ectopic beats of clearly supraventricular origin are seen in WPW, as in this case, has been cited as circumstantial evidence supporting this theory.<sup>12,13</sup>

The true nature of an ECG exhibiting a short P-R interval and a QRS complex resembling CLBBS is not always immediately obvious. It may require vectorcardiography, His bundle recordings and/or atrial pacing; spontaneous or induced changes in AV and QRS conduction, however, may contribute significantly to its under-

standing, even without these special procedures. The electrogenesis of similar patterns in solitary tracings reported many years ago without any of the above aids or the benefits of recently acquired information concerning pre-excitation syndromes must be considered uncertain (e.g. case 1, ref. 1). The present case is considered to be an example of pre-excitation with spurious LBBB. There are two groups of patients with WPW conduction and proven LBBB. The first show scalar ECGs reminiscent of those in Figs 1 and 3, i.e. with apparent delta waves and terminal forces of LBBB. Both features are confirmed vectorcardiographically.<sup>5</sup> The second group does not exhibit the short P-R LBBB pattern, but serial tracings show either a normal P-R interval with typical LBBB or a short P-R followed by typical WPW conduction without evidence for LBBB (case 3, ref. 1). This is not surprising, since evidence for BBB sometimes disappears when pre-excitation of the blocked ventricle takes place.<sup>15</sup>

#### REFERENCES

- Pick, A. and Fisch, C. (1958): *Amer. Heart J.*, **55**, 504.
- Laham, J. (1969): *Le syndrome de Wolff-Parkinson-White*. Paris: Librairie Maloine.
- Wallace, A. G., Estes, E. H. and McCall, B. W. (1962): *Amer. Heart J.*, **63**, 508.
- Chou, T. C. and Helm, R. A. (1967): *Clinical Vectorcardiography*, p. 187. New York: Grune & Stratton.
- Castellanos, A., Mayer, J. W. and Lemberg, L. (1962): *Amer. J. Cardiol.*, **10**, 657.
- Lown, B., Ganong, W. F. and Levine, S. A. (1952): *Circulation*, **5**, 693.
- Castellanos, A., Castillo, C. A., Martinez, A. and Agha, A. S. in Schlant, R. C. and Hurst, J. W., eds (1972): *Advances in Electrocardiography*, pp. 249-258. New York: Grune & Stratton.
- Massumi, R. A., Vera, Z. and Ertem, G. in Schlant, R. C. and Hurst, J. W., eds (1972): *Ibid.*, pp. 275-295. New York: Grune & Stratton.
- James, T. N. (1961): *Amer. Heart J.*, **62**, 756.
- Bellet, S. and Jedlicka, J. (1969): *Amer. J. Cardiol.*, **24**, 831.
- Schubart, A. F., Marriott, H. J. L. and Gorten, R. J. (1958): *Amer. J. Med.*, **24**, 209.
- Sherf, L. and James, T. N. (1969): *Dis. Chest*, **55**, 127.
- Castellanos, A., Lemberg, L., Salhanick, L. and Berkovits, B. V. (1968): *Amer. Heart J.*, **75**, 6.
- Sherf, L. and James, T. N. (1966): *Henry Ford Hosp. Bull.*, **14**, 265.
- Gamboa, R., Peñalozza, D., Sime, F. and Bancharo, N. (1962): *Amer. J. Cardiol.*, **10**, 650.