

Tracheobronchomegaly: The Mounier-Kuhn Syndrome

E. M. BASS

SUMMARY

A case of tracheobronchomegaly (Mounier-Kuhn syndrome) is reported. The striking features are gross dilatation of the trachea and both main bronchi with associated chronic pulmonary disease. The world literature is reviewed and the possible aetiological factors discussed.

S. Afr. Med. J., 48, 1718 (1974).

Mounier-Kuhn,¹ in 1932, first described a unique syndrome characterised by striking dilatation of the trachea and major bronchi, and since then 57 further cases have been reported in the world literature.² Katz *et al.*³ logically named the condition tracheobronchomegaly. It is now a distinctive clinicoradiological condition and the associated respiratory tract disease that accompanies tracheobronchomegaly covers a wide spectrum, from minimal disease with good preservation of pulmonary function to disabling and fatal pulmonary disease. This article reports a case in which the diagnosis was accidentally but fortuitously made on the patient's admission to hospital for a totally unrelated illness.

CASE REPORT

A Cape Coloured male aged 28 years, was admitted to Groote Schuur Hospital in January 1974 with a 3-week history of gradual and progressive abdominal swelling and associated right upper quadrant pain. Considerable weight loss had occurred over the previous few months.

The patient had previously been in hospital in June 1973 with pneumonia, but had made an uneventful recovery. There was no history of contact with tuberculosis. Systematic interrogation revealed a previous history of productive cough for many years, but without haemoptysis or dyspnoea.

On physical examination he was found to be cachectic with gross ascites. A 4-finger hepatomegaly was present. There was no cyanosis, finger clubbing, jaundice or pendant oedema. The supraclavicular and inguinal lymph nodes were enlarged. Further findings included: pulse rate 112/min; blood pressure 110/80 mmHg; jugular venous pressure elevated 2 cm; no cardiomegaly and normal heart

sounds. On auscultation of the chest scattered rhonchi and crepitations at the right base were found.

Special investigations showed a haemoglobin concentration of 13 g/100 ml; the white cell count was 6 000/mm³ with lymphocytes 36%; the erythrocyte sedimentation rate was 123 mm/h (Westergren); total bilirubin was 0.4 mg/litre and alkaline phosphatase 326 units.

A lymph node biopsy specimen showed tuberculous granulomatous inflammation. Peritoneoscopy suggested tuberculous peritonitis and from cultures of the peritoneal fluid acid-fast bacilli were grown.

Routine chest X-ray films (Figs 1 and 2) showed a widened mediastinum initially thought to be due to mediastinal lymphadenopathy, but tomography demonstrated gross distension of the trachea and main bronchi (Fig. 3). A bronchogram confirmed the diagnosis of

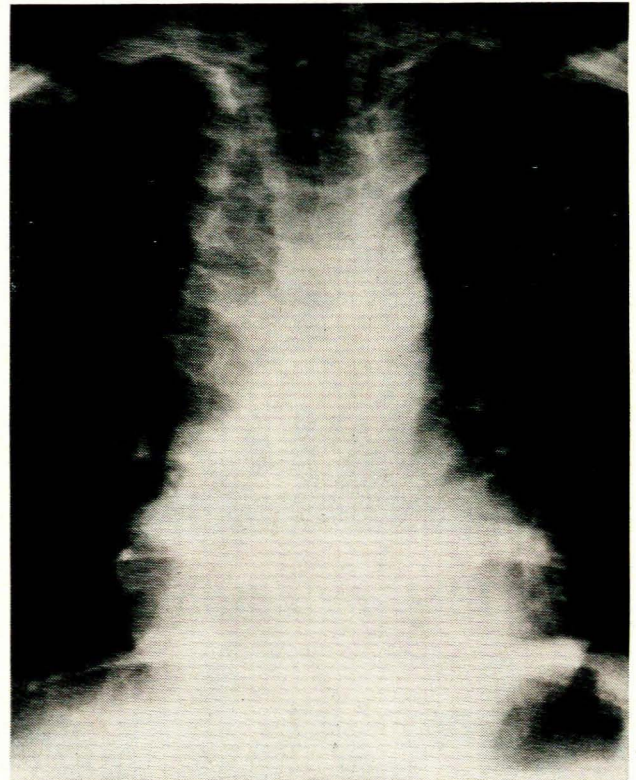


Fig. 1. Postero-anterior radiograph of the chest showing bilateral widening of the superior mediastinum simulating lymphadenopathy.

Department of Radiodiagnosis, Groote Schuur Hospital, Cape Town

E. M. BASS, M.B. CH.B., D.M.R.D.

Date received: 16 April 1974.

cessive vocal or pulmonary effort. However, the degree of dilatation seen in tracheobronchomegaly is much more marked than in these instances.

Bronchography reveals the dilatation with the lumen bulging between the cartilage rings. Diverticulae of the trachea are present in about one-third of cases² and occasionally in the major bronchi. These tracheal diverticulae are wide-mouthed and vary markedly in size and number,⁵ arising predominantly in the right posterior wall. They are considered to be herniations of tracheal mucosa between cartilagenous rings. In addition, any coexisting bronchiectasis and chronic bronchitis can be seen on bronchography.

The diagnosis is usually made during bronchoscopy when the cavernous dilatation of the tracheobronchial tree, redundant mucous membrane with saccular pouches and pooled secretions are seen. The tip of the bronchoscope may easily enter a diverticulum. However, the redundant tracheobronchial wall may superficially simulate a normal lumen in diameter to an unsuspecting endoscopist⁶ and the diagnosis is most frequently made on radiographic studies.

The clinical features are those of bronchiectasis with cough and production of purulent sputum, occasionally with haemoptysis and recurrent attacks of fever. Subsequently dyspnoea and cyanosis occur and finger clubbing may develop. Examination of the chest may reveal signs of bronchiectasis, with consolidation during episodes of acute infection. Respiratory function tests^{7,8} demonstrate an enlarged dead space and increased tidal volume and there may be evidence of obstructive airway disease.

The pathogenesis of tracheobronchomegaly is uncertain. Most authors now accept that it is primarily a connective tissue disorder with a congenital defect of the elastic and muscle tissue in the walls of the trachea and main bronchi. This is further borne out by the reported association of tracheobronchomegaly with generalised connective tissue disorders such as the Ehlers-Danlos syndrome⁹ and in a child with cutis laxa.⁷ The coexistence of chronic pulmonary infections with repeated paroxysms of coughing may raise the intratracheal pressure and increase the liability to bronchial and tracheal dilatation. Diaz¹⁰ noted that the subglottic portion of the trachea was normal and in this area there was an absence of the myenteric plexus in his case. He therefore postulated that tracheobronchomegaly could be of the same nature as Hirschsprung's disease and achalasia of the cardia—this has not been substantiated by others.

However, Bateson and Woo-Ming,² on reviewing the world literature, stated that about 50% of cases present after the age of 29 years, and that this is not the age of presentation of a condition due solely to a congenital abnormality. It has also been suggested that tracheobronchomegaly may be secondary to chronic pulmonary disease, but the wide spectrum of associated pulmonary disease argues against this. Infection is, rather, a consequence of the structural abnormality, and not the cause. Perhaps the best evidence against claims that tracheobronchomegaly is acquired is its apparent rarity, compared with the wide prevalence of chronic pulmonary disease of all types.

There may be a racial predisposition to tracheobronchomegaly, since a significant proportion of those cases reported in the USA (9 out of 19) were of the Negro race. In addition, Johnston and Green¹¹ suggested that tracheobronchomegaly may be inherited as an autosomal recessive, since 2 of their cases were siblings.

The presence of bronchiectasis in the majority of cases suggests a relationship to tracheobronchomegaly. However, the clinical presentation of bronchiectasis occurs at a much younger age.² The later presentation of bronchiectasis in cases of tracheobronchomegaly suggests that it may be a result of faulty removal of secretions from the lobar and more distal bronchi due to the abnormality of the main bronchi and trachea; or that the two conditions are the result of the same pathological process.

Whatever the aetiological factors, the pooling of secretions in the airways, with some diminution in the effectiveness of coughing, plays an important role in producing the repeated chest infections to which these patients are prone.

Treatment is directed towards prompt control of chest infections and long-term application of antibiotics. Postural drainage may be indicated.

REFERENCES

1. Mounier-Kuhn, P. (1932): *Lyon méd.*, **150**, 106.
2. Bateson, E. M. and Woo-Ming, M. (1973): *Clin. Radiol.*, **24**, 354.
3. Katz, I., Levine, M. and Herman, P. (1962): *Amer. J. Roentgenol.*, **88**, 1084.
4. Shanks, S. C. and Kerley, P. (1954): *A Textbook of X-ray Diagnosis*, 2nd ed., vol. II, p. 283. Philadelphia: W. B. Saunders.
5. Suprenant, E. Z. and O'Loughlin, B. J. (1966): *D.s. Chest*, **49**, 345.
6. Zizmor, J., Naiberg, D. and Noyet, A. M. (1965): *Arch. Otolaryng.*, **82**, 194.
7. Wanderer, A. A., Ellis, E. F., Goltz, R. W. and Cotten, E. K. (1969): *Pediatrics*, **44**, 709.
8. McKerron, C. G. and Hewett, M. (1966): *Brit. J. Dis. Chest*, **60**, 200.
9. Aaby, G. V. and Blake, H. A. (1966): *Ann. Thorac. Surg.*, **2**, 64.
10. Diaz, C. J. (1940): *Rev. clin. esp.*, **1**, 432.
11. Johnston, R. F. and Green, R. A. (1965): *Amer. Rev. Resp. Dis.*, **91**, 35.