

# Bilateral Retrobulbar Air after Surgical Emphysema

## A CASE REPORT

R. M. FISHER

### SUMMARY

A case of very widespread emphysema, causing bilateral retrobulbar orbital air, is described in a 5-month-old Cape Coloured child with bronchopneumonia.

*S. Afr. Med. J.*, **48**, 1619 (1974).

Gross surgical emphysema after pneumomediastinum has been frequently seen; and pneumomediastinum resulting

---

**Department of Radiology, Red Cross War Memorial Children's Hospital, Cape Town**

R. M. FISHER, M.B. CH.B., D.M.R.D.

---

Date received: 10 April 1974.

from bronchopneumonia is known to occur. A remarkable extent of spread of surgical emphysema is shown in the following case. This is the first report of retrobulbar orbital air resulting from such a course.

### CASE HISTORY

A 5-month-old Cape Coloured male was admitted with gastro-enteritis and bronchopneumonia. There had been swelling of the face and neck for 24 hours preceding admission.

On examination there was gross surgical emphysema of the chest wall, neck, scalp and face with involvement of the eyelids. Slight bilateral proptosis was also present.

### Radiographic Findings

An X-ray film of the chest showed bilateral patchy bronchopneumonia and an associated pneumomediastinum, with gross surgical emphysema of the chest wall and neck (Fig. 1). Lateral X-ray film of the skull demonstrated

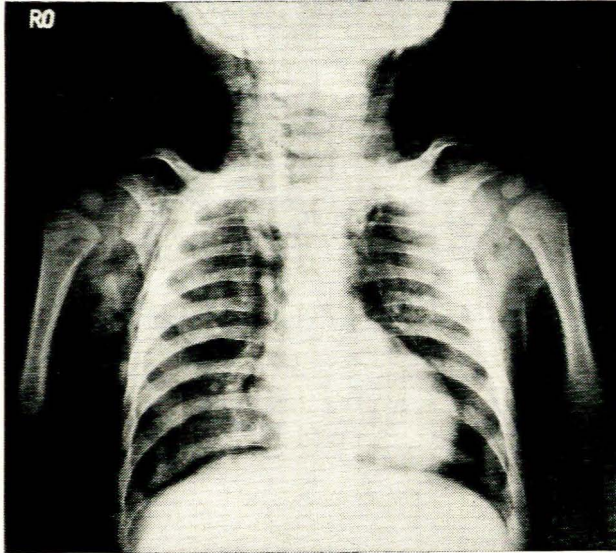


Fig. 1. Bilateral bronchopneumonia, pneumomediastinum and surgical emphysema.

surgical emphysema extending along the fascial planes in the neck to the base of the skull anteriorly and posteriorly. The scalp was elevated, and air was seen in the face and upper eyelids (Fig. 2). On the antero-posterior view of the face and skull, bilateral crescents

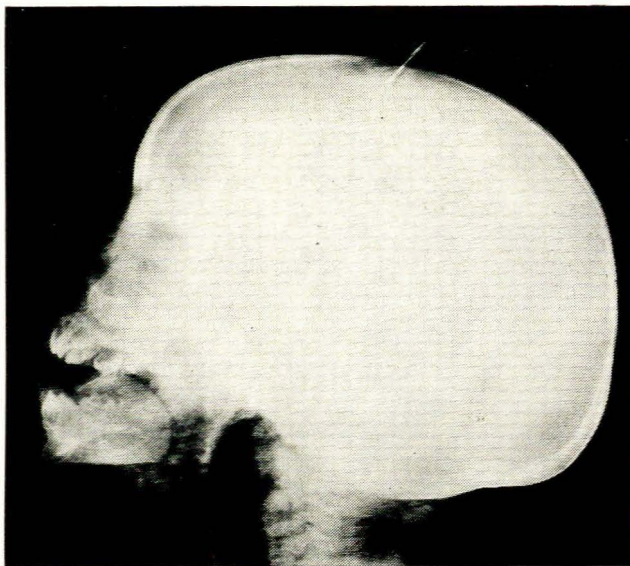


Fig. 2. Surgical emphysema in neck, face, orbit and skull.

of retrobulbar air were present. On the right the trochlea for the superior orbital oblique was delineated (Fig. 3).

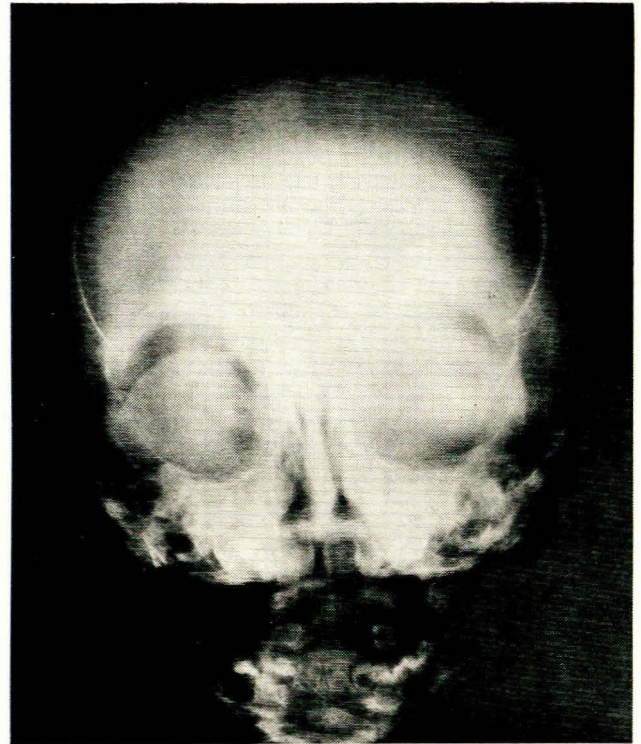


Fig. 3. Bilateral retrobulbar air showing trochlea on right.

The child recovered rapidly on treatment, and all the surgical emphysema resolved in a few days.

### DISCUSSION

Bronchopneumonia may be accompanied by segmental areas of atelectasis. In a young child the pores of Kohn are not developed, and the atelectasis cannot be relieved by perfusion of air from adjacent aerated regions. Thus hyperinflation of segments surrounding the atelectasis occurs. The smaller the areas of atelectasis, the more localised is the area of compensatory overdistension. This creates an increased pressure gradient, and alveolar rupture with pulmonary interstitial emphysema results. The escaped air tracks along pulmonary vascular sheaths to the hila and mediastinum. From here it can follow an easy path to the soft tissue planes of the neck and more distal regions, as it did in our case. We believe that it must also have tracked along the vascular sheaths to the base of the skull and through the inferior orbital fissures to reach the loose alveolar tissues surrounding the eyeballs.

### REFERENCE

1. Macklin, M. T. and Macklin, C. C. (1944): *Medicine*, 23, 281.