

A South African Indian Hermaphrodite

H. J. GRACE, J. K. G. LIGHT

SUMMARY

The clinical and genetic features of an intersexual Indian infant, found to be a hermaphrodite, are described. The parents insisted on rearing the child as a male, and so the internal female genitalia and the right ovarian gonad were removed and the left scrotal testis retained. The karyotype was a mosaic of 46, XX and 47, XXY cell lines. The dermatoglyphs were grossly normal.

S. Afr. Med. J., 48, 1349 (1974).

Hermaphroditism is an extremely rare occurrence in Caucasian races, and in South Africa it has apparently not yet been reported in an Indian. South African Indians are descended from immigrants who came here about a century ago from, principally, the Madras, Calcutta and Bombay districts of India. This article describes the finding of hermaphroditism in an Indian child.

CASE REPORT

A baby was born during December 1971 to healthy, unrelated parents. At the time the mother was 19 and the father 22 years of age. This was their first baby. The pregnancy ran a normal course and there was no contributory family or medical history.

At birth the baby had episcene external genitalia but no other abnormalities. The baby was registered as a male and reared accordingly. After 18 months the parents sought medical advice about their child's unusual genitalia. The external genitalia consisted of a penile phallus, 4 cm long, with a dimpled glans and prepuce. The shaft was bound down by chordae and so obscured the single perineal urogenital meatus. The scrotum was bifid; on the left it was well developed and contained a gonad, but the right side was hypoplastic and empty. The perineal raphe was well developed. An indirect inguinal hernia was present on the right side.

Bimanual palpation failed to detect any internal genitalia. Cystoscopy revealed a urogenital sinus into which the urethra opened; a verumontanum was seen but there was

no obvious cervix uteri. Contrast radiography showed the bladder outline to be normal, lying anterior to the vagina. No uterus was demonstrated. Urinary excretion of 17-oxo- and 17-oxygenic steroids, and of pregnanetriol, was normal at 0,8 mg, 0,4 mg, and 1,0 mg per day, respectively.

Two cell lines were identified in the peripheral blood lymphocytes; 75% were 46, XX and the balance, 47, XXY. Dermatoglyphic features were grossly normal (Table I, Fig. 1), although the total ridge count (TRC) was lower than the mean counts of normal males and females.

TABLE I. DERMATOGLYPHIC ANALYSIS

Finger patterns		TRC	a-b	atd	Palmar patterns	
L	R				L	R
v-i	i-v					
WWWL	LWWW	120	72	98	t,IV	t,IV
Normal males*		153	75	83		
Normal females		134	75	89		

* Mean values in South African Indians.¹

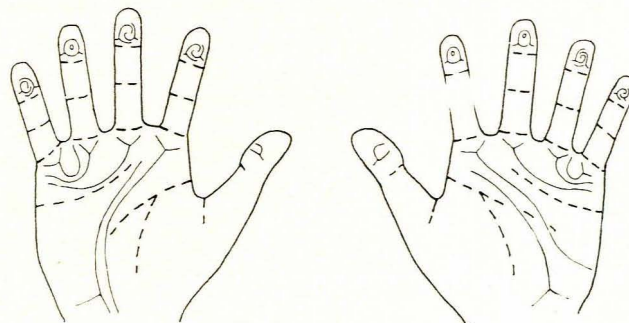


Fig. 1. Diagram showing patterns and flexion creases of the hands.

Laparotomy disclosed a small ovoid gonad, about 8 mm long, in the position of the right ovary. This was joined by a 3-cm-long tube to a rudimentary unicornuate uterus, which measured 1 cm in length. Frozen sections of the right gonad showed it to be an ovary (Fig. 2); it was removed together with its adnexa. Longitudinal biopsy of the left scrotal gonad was done, and on histological examination it proved to be a testis (Fig. 3) with seminiferous tubules lined by a single layer of cells, and marked hypoplasia of the interstitial cells. Histological examination confirmed that the right Fallopian tube led to a small hypoplastic uterus. No cervical tissues were seen.

Department of Genetics, Natal Institute of Immunology, Durban

H. J. GRACE, M.Sc.

Durban

J. K. G. LIGHT, M.B. B.Ch., F.C.S. (S.A.), Urologist

Date received: 31 January 1974.

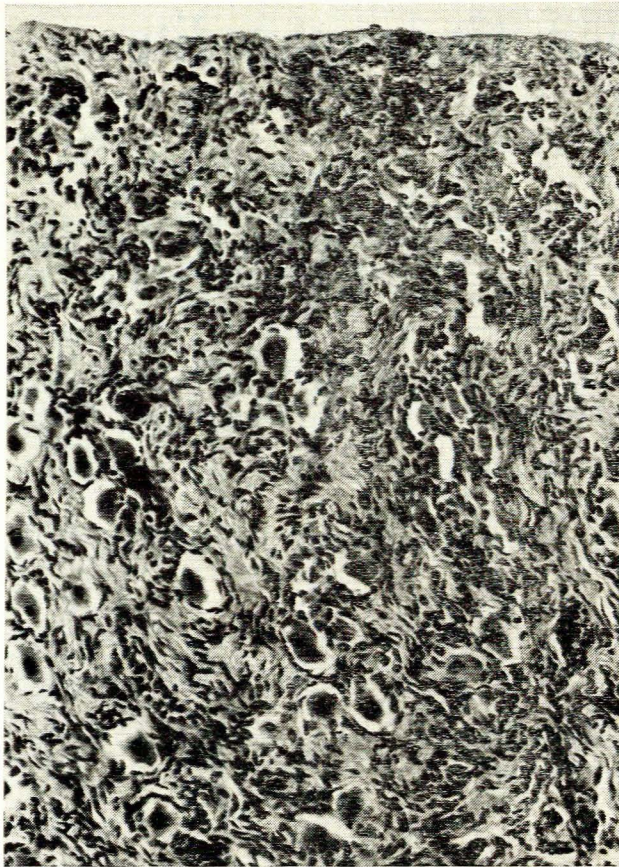


Fig. 2. Portion of right gonad showing numerous ovarian follicles.

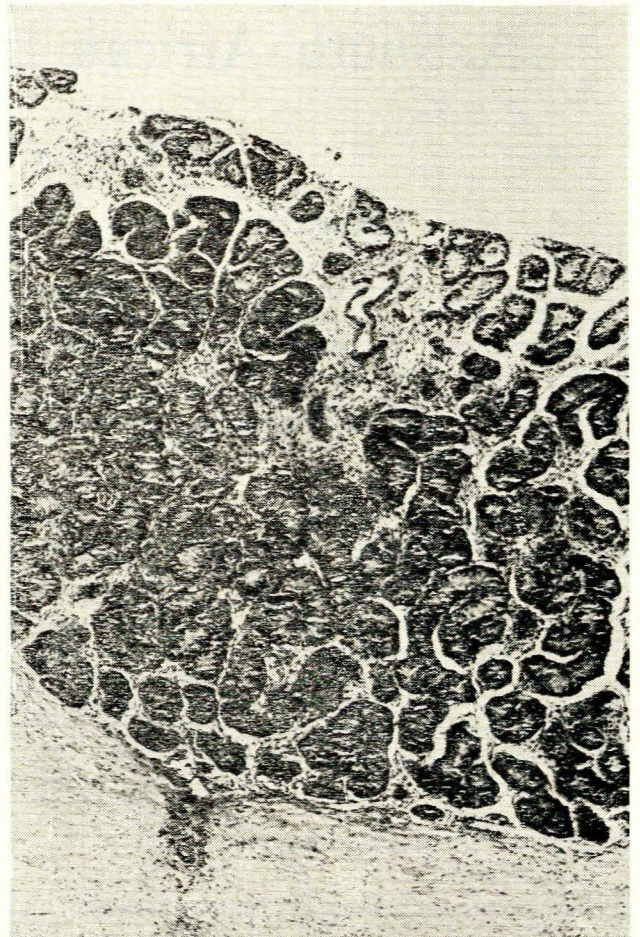


Fig. 3. Section of left testis. Note interstitial cell hypoplasia.

DISCUSSION

Hermaphroditism is not unknown in Indians but it is not common, and its prevalence in India has not been established. In the South African Indian community intersexuality is quite uncommon; in a 6-year survey only 2 of some 20 000 Indian babies had ambiguous genitalia (this does not include the present case).

In the present case the parents are adamant that the child be reared as a male, and so treatment is planned to reinforce the male features. However, in hermaphroditism the testicular tissue is usually hypotrophic; virilisation is unlikely and sterility is inevitable.

REFERENCE

1. Grace, H. J. and Ally, F. (1972): *S. Afr. Med. J.*, **46**, 1175.