

# The Detection of Visual Defects in Infants

P. STEVEN

## SUMMARY

The early warning signs for the detection of visual defects in infants are emphasised. The simple tests which can be carried out by the general practitioner are considered, and the more sophisticated ophthalmic investigations are discussed.

*S. Afr. Med. J.*, 48, 1261 (1974).

The early detection of visual defects in infants is of great importance. Usually, the mother, fearing that her infant has a visual defect, approaches the doctor.

These infants take no apparent visual interest in their surroundings, and may well demonstrate abnormal spontaneous searching movements of the eyes or ocular nystagmus. The normal infant should show an ability to fixate a light and to follow it, even although these periods of fixation or following are brief.<sup>1</sup>

All infants suspected of having poor vision should have a full ocular examination, including an examination of the fundus under general anaesthesia.

Infants suspected of having visual defects are considered under 2 groups: firstly those where the cause is established on clinical examination, e.g. corneal opacities, cataracts or fundal disease; and secondly those where the diagnosis is not obvious on clinical examination alone.

The following examinations are suggested: history; pupillary response to light; the appearance of the optic disc and fundus; optokinetic nystagmus response; extra-ocular movements and the detection of squint; X-ray film of skull; electroretinogram; and the visual-evoked cortical response.

## History

A detailed history with special reference to a family history of defective vision and blindness is taken. The majority of cases of defective vision found in infants will be of an hereditary or congenital nature, including congenital cataracts, macular degeneration and tapeto-retinal degeneration.<sup>2</sup> Of the remainder the majority are secondary to disease of the posterior segment of the eye.

## Pupillary Response to Light

The normal pupil should react to direct and consensual light stimulation and accommodation at birth. The pupillary responses should be brisk and equal on both sides.

## Optic Disc and Retinal Appearance

The colouration of the optic disc should be noted. Pallor suggests pathology, and, when present, inadvertent pressure on the eye must at first be avoided.<sup>3,4</sup>

The vasculature of the fundus may be helpful and marked thinning and attenuation of the arterioles is especially important in the diagnosis of tapeto-retinal degeneration. Macular degeneration may be noted, or the cherry-red spot in Tay-Sachs disease.

## Optokinetic Nystagmus

This is a normal phenomenon of ocular movement.<sup>5</sup> The common example is a nystagmus produced by fixation and refixation when looking through the window of a moving vehicle, when the eyes follow an object until it passes out of the field of vision, then refixate on a new object and follow this again.

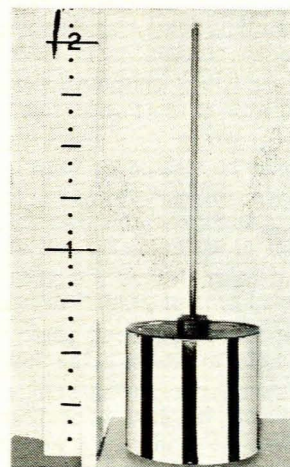


Fig. 1. Drum with black and white vertical lines used to detect the optokinetic nystagmus response.

It is tested by a revolving drum on which alternate vertical black and white stripes are painted (Fig. 1). The

Neuro-Ophthalmology Clinic, Department of Ophthalmology,  
Groote Schuur Hospital and University of Cape Town

P. STEVEN

Date received: 10 January 1974.

normal infant has the ability to fixate an object and to follow it even although these periods of fixation and following may be very brief.

Optokinetic nystagmus is noted in the newborn, and its presence indicates a high probability of normality in vision, but its absence does not necessarily imply poor vision. The test is repeated, and if successive responses are negative the finding is significant. In addition optokinetic nystagmus can be used to assess the visual acuity of the infant, and with this method it has been established that the visual acuity at 5 months of age is 6/18, at 9 months 6/12, at 2 years 6/9 and at 3 years 6/6.<sup>6</sup>

### Ocular Movements

These movements have a supranuclear, a nuclear and an infranuclear pathway. The nuclear and infranuclear pathways are clinically indistinguishable.

Ocular movements in a newborn are often dysjunctive, so that transient strabismus may be seen. Persistence of a particular abnormality necessitates treatment.

Strabismus is diagnosed by noting the decentration of the corneal light reflection. The corneal light reflection is nasal to the centre of the pupil due to the temporal position of the fixating macula. When this reflection is displaced towards the nasal side a divergent strabismus is suggested, whereas deviation towards the temporal side indicates a convergent strabismus.

In suspicious cases this test must be followed up by the cover test. Here the eyes fixate an object and both eyes in turn are occluded. Movement is then noted in the uncovered eye, and if the eye moves inwards a divergent strabismus is present, while outward movement indicates a convergent strabismus.

All patients with a fixed manifest strabismus should be examined under anaesthesia, again with a fully dilated pupil, so as to exclude a local ocular cause. An eye which is deviated either convergent or divergent, will have its image suppressed, which, if continued, leads to amblyopia exanopsia or amblyopia from disuse. Examination of such an eye will show no evidence of local disease of the eye.

Strabismus should be treated as soon as possible so as to maintain equal visual acuity and to establish and develop binocular single vision. In the assessment of strabismus, the full range of ocular movements should be noted. Paralysis of movement of the extra-ocular muscles may indicate involvement of cranial nerves 3, 4 or 6.

With an unco-operative patient passive head rotation horizontally will help to identify the muscles which are involved. These doll's eye movements are independent of vision<sup>7</sup> and indicate integrity of the vestibular system, pontine paramedian reticular formation, the medial longitudinal fasciculus and the oculomotor nuclei subserving horizontal gaze.

### X-Ray Film of Skull

When the history suggests an acquired cause for the poor vision, a skull X-ray film may prove helpful in

demonstrating fractures and suprasellar calcification may be noted with craniopharyngiomas.

### Electroretinogram

When a visual defect is suspected and the pupillary responses are normal, and the discs not obviously pathological, then electrodiagnostic tests are used.

The electroretinogram (ERG) is a record of the electrical processes occurring in the external layer of the retina. It is a measure of the mass electrical responses of the retinal receptors and bipolar cells to a bright flash of light. In children general anaesthesia is required, and a contact lens, which is the active electrode, is applied to the cornea and an earth electrode to the forehead. A light is then flashed into the eye resulting in a characteristic tracing. With a large area of retina damaged or diseased, a subnormal ERG is recorded, and when almost the entire retina is involved no ERG is obtained.

Diseases which affect the ganglion cell layer of the retina, i.e. the innermost layer of the retina, such as in glaucoma, will have a normal ERG. Congenital tapeto-retinal degeneration, e.g. retinitis pigmentosa, affects children early in life, resulting in little or no useful vision from birth. Fundus changes may be nil or minimal early on, but the ERG is extinguished. As the child grows older the characteristic features of this condition are noted, such as pigmentary dystrophy, vessel attenuation more marked in the arterioles, and a yellow atrophic disc.

Thus by means of clinical examination and electrodiagnostic investigations, most conditions of poor vision may be diagnosed.

Where no pupillary abnormality can be elicited and the fundus is normal, a cortical cause for the poor vision should be suspected. Here visually evoked cortical responses (VER) may be helpful in establishing the diagnosis. These are electrical changes, which occur in the occipital cortex in response to light stimulation, and are reduced where there is macular disease or optic atrophy.<sup>8</sup>

Apparent blindness may be due to severe mental retardation. Difficulty may be found in differentiating this clinically from cortical blindness. However, in apparent blindness the pupillary reflexes will be normal, as will be the ERG and VER responses.

Compressive lesions of the anterior visual pathways are uncommon in infancy, but should always be borne in mind when there is a definite history of an acquired defect, e.g. meningitis.

### REFERENCES

1. Brazelton, T. B., Scholl, M. B. and Robey, J. S. (1966): *Paediatrics*, **37**, 284.
2. Sevel, D. and Shochet, S. (1972): *S. Afr. Med. J.*, **46**, 295.
3. Khodadoust, A. A., Ziai, M. and Biggs, S. L. (1968): *Amer. J. Ophthalmol.*, **66**, 502.
4. Hosaka, A. (1963): *Jap. J. Ophthalmol.*, **7**, 77.
5. Brain, W. R. (1962): *Disease of the Nervous System*, 6th ed., p. 69. London: Oxford University Press.
6. Catford, G. V. and Oliver, A. (1973): *Arch. Dis. Childh.*, **48**, 47.
7. Bird, A. C. and Sanders, M. D. (1970): *Trans. Ophthalm. Soc. U.K.*, **90**, 417.
8. Harcourt, R. B. (1969): *Brit. Orthopt. J.*, **26**, 1.