

# Right Bundle-Branch Block Associated with Transient Left Posterior Hemiblock in a Case of Acute Myocardial Infarction

JEANNE DE KOCK, L. SCHAMROTH

## SUMMARY

The intraventricular conduction defect of left posterior hemiblock is very uncommon. Its occurrence as a transient phenomenon during the course of acute myocardial infarction, as described in this report, is exceptionally rare. The presentation revealed a planar reorientation of QRS forces, and demonstrated the masking effect of left posterior hemiblock on the parameters of anterolateral myocardial ischaemia.

*S. Afr. Med. J.*, 48, 1237 (1974).

The term hemiblock was coined by Rosenbaum *et al.*<sup>1</sup> and refers to a delay or block in conduction through one of the divisions of the left bundle branch. The concept has received much emphasis during recent years,<sup>1-32</sup> and has important diagnostic, clinical and prognostic implications.

The left bundle branch divides into two major divisions or fascicles—the anterosuperior division, and the postero-

inferior division—which together with the right bundle branch constitute a trifascicular conducting system (Fig. 1 A). Conduction through both the divisions of the left bundle branch occurs simultaneously, resulting in a mean QRS vector which is directed downward and to the left (Fig. 1 A). If conduction is blocked in the anterosuperior division—a left anterior hemiblock—activation of the left ventricle will occur primarily through the postero-inferior division of the left bundle branch, thereby resulting in a left axis deviation (Fig. 1 B).

Conversely, if conduction is blocked within the postero-inferior division—a left posterior hemiblock—activation of the left ventricle will occur primarily through the anterosuperior division, thereby resulting in a right axis deviation (Fig. 1 C). These hemiblocks are thus expressions of an intraventricular conduction defect. The hemiblocks may be associated with right bundle-branch block (as illustrated in Fig. 1). When this occurs, the initial QRS forces are usually unchanged by the advent of the right bundle-branch block, which merely results in the addition of a terminal QRS vector (dotted lines in Fig. 1), which is directed anteriorly and to the right. The association of right bundle-branch block with a hemiblock is one of the expressions of bilateral bundle-branch block.

The postero-inferior division of the left bundle branch is far more resistant to disease processes than the anterosuperior division. This is because the postero-inferior division has, *inter alia*, a double blood supply whereas the anterosuperior division has but a single blood supply. A left posterior hemiblock therefore usually connotes a severely compromised myocardial circulation; and whereas left anterior hemiblock is a common intraventricular conduction disturbance, left posterior hemiblock is rare.<sup>1</sup>

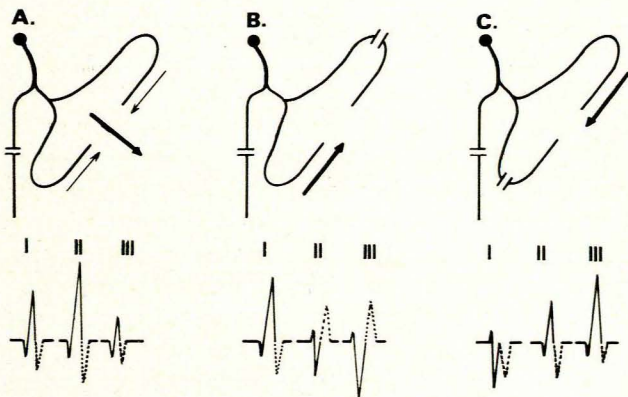


Fig. 1. Diagrams illustrating right bundle-branch block with: A—normal left bundle-branch conduction; B—left anterior hemiblock; and C—left posterior hemiblock.

H. F. Verwoerd Hospital and University of Pretoria, Pretoria  
JEANNE DE KOCK, M.B. CH.B.

Baragwanath Hospital and University of the Witwatersrand,  
Johannesburg

L. SCHAMROTH, M.D., D.S.C., F.R.C.P., F.R.S.(S.A.F.)

Date received: 27 December 1973.

## CASE REPORT

The electrocardiograms in Fig. 2 were recorded from a 56-year-old man who presented with the classic clinical features of acute myocardial infarction. He remained in the coronary care unit for 3 days and was then transferred to a general medical ward. He died suddenly 2 days later.

Electrocardiogram A of Fig. 2 was recorded on the day of admission to the coronary care unit (2 October 1973), and shows the features of acute antero-septal myocardial infarction complicated by right bundle-branch block. The antero-septal infarction is reflected by the deep and wide pathological Q waves in leads V1 to V4, and the coved and elevated S-T segments with the inverted T

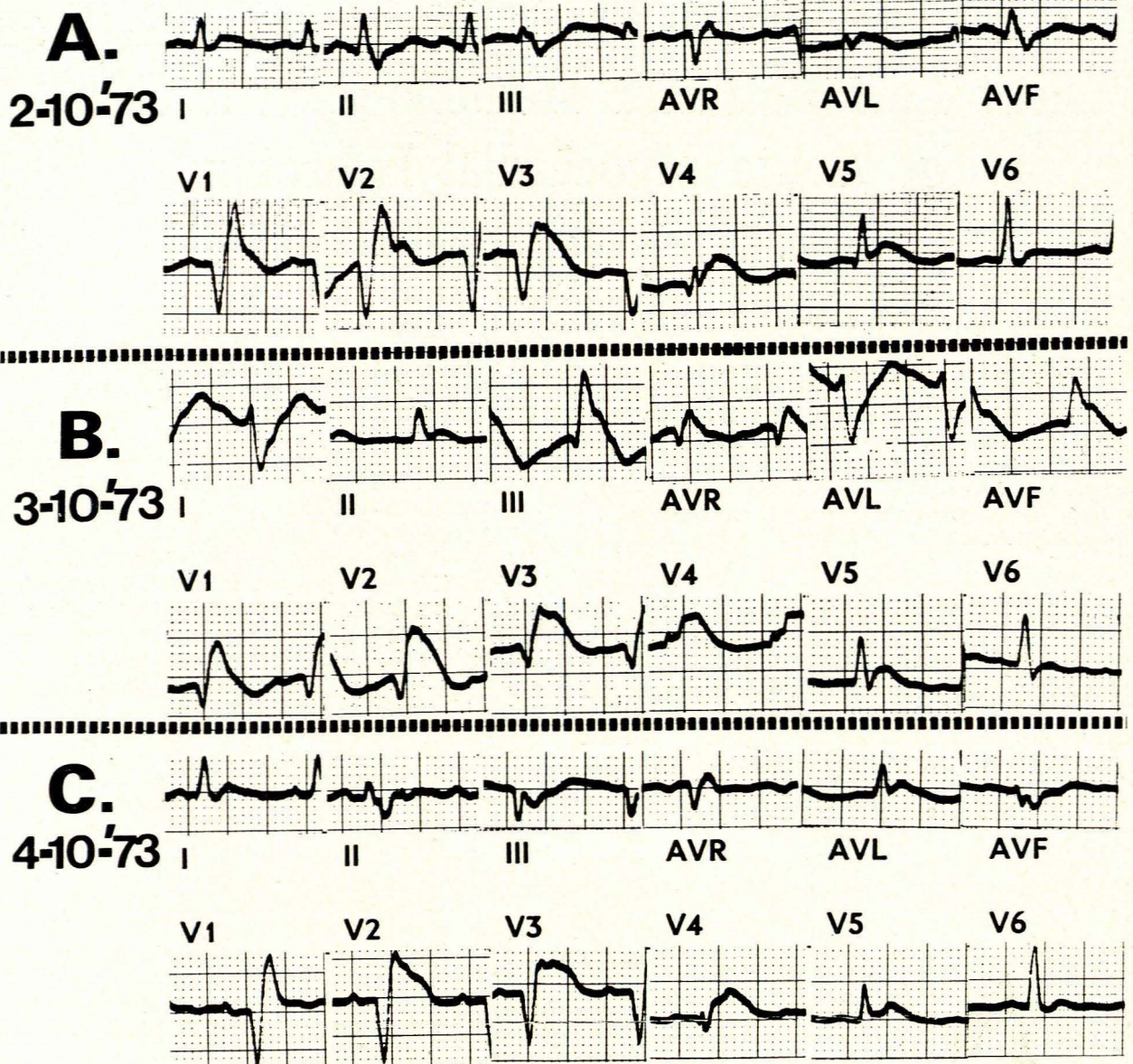


Fig. 2. Electrocardiograms illustrating acute anteroseptal myocardial infarction complicated by right bundle-branch block—electrocardiograms A and C; and right bundle-branch block in association with left posterior hemiblock—electrocardiogram B.

waves in leads V1 to V5. The anterolateral extension of the myocardial ischaemia is reflected by the low to inverted T waves in standard lead I, and leads AVL and V6. The right bundle-branch block is reflected by the slurred terminal S waves in standard leads II and III, and leads AVF and V6, and the terminal R' deflection in leads V1 to V3. Note that the right bundle-branch block does not mask or distort the abnormal initial QRS forces of the myocardial infarction. These initial dominant QRS forces (excluding the forces of the right bundle-branch block) are directed at +50 degrees on the frontal plane hexaxial reference system.

Electrocardiogram B of Fig. 2 was recorded on the

second day and reflects the same features of the acute anteroseptal infarction as are depicted in electrocardiogram A. The infarction pattern is now, however, associated with the following changes:

The mean manifest dominant frontal plane QRS axis (excluding the terminal force of the right bundle-branch block) is now directed at +110 degrees. This is reflected empirically by the tall R wave in standard lead III and lead AVF, and the deep terminal S wave in standard lead I and lead AVL. This right axis deviation represents the development of a left posterior hemiblock.

The QRS deflections in the horizontal plane leads (leads V1 to V6) show a general diminution in amplitude,

and are now smaller than the QRS deflections of the frontal plane leads (standard leads I, II and III, and leads AVR, AVL and AVF) which show a general increase in amplitude (compare with electrocardiogram A).

The T waves are now upright in standard lead I and lead AVL.

Electrocardiogram C of Fig. 2 was recorded on the third day in hospital (4 October 1973). The dominant QRS force (excluding the terminal QRS force of the right bundle-branch block) is now directed at  $-10$  degrees on the frontal plane hexaxial reference system. This consequently represents a regression from the right axis deviation shown in electrocardiogram B. The regression has, however, so-to-say overcompensated, since the dominant QRS force now reflects a slight left axis deviation. Furthermore, it is of interest to note that the QRS amplitude of the horizontal plane lead deflections is now once again of greater magnitude than the QRS amplitude of the frontal plane lead deflections.

This direction of the dominant QRS force now remained stable throughout the evolution of the infarction, and no further episodes of left posterior hemiblock occurred. Furthermore, the patient did not develop any evidence of second- or third-degree atrioventricular block.

## DISCUSSION

Left posterior hemiblock rarely complicates acute myocardial infarction. Marriott and Hogan,<sup>8</sup> in a review of 250 consecutive patients with acute myocardial infarction, noted 38 cases with left anterior hemiblock, and only 2 cases with left posterior hemiblock. Both these cases occurred in association with right bundle-branch block. One of these patients was admitted with the left posterior hemiblock, the other acquired it after admission. One of these cases was associated with both inferior and anterior myocardial infarction; the other with anterolateral myocardial infarction.

De Sousa and Cerqueira-Gomes<sup>9</sup> reported an example of left posterior hemiblock which occurred during the second day of acute anteroseptal myocardial infarction, and which was later complicated by right bundle-branch block.

Scanlan *et al.*<sup>10</sup> in an 11-year study, reported 6 cases of left posterior hemiblock with right bundle-branch block, which occurred in association with acute myocardial infarction. All but one had the pattern on admission to hospital. None of these cases progressed to complete atrioventricular block.

When left posterior hemiblock develops as a result of coronary artery disease, it tends to be permanent. Examples of transient left posterior hemiblock as a result of coronary artery disease are very rare indeed. Rosenbaum *et al.*<sup>7</sup> reported one case of left posterior hemiblock which presented in association with right bundle-branch block, and which occurred as a transient phenomenon during acute anteroseptal myocardial infarction. Their case also developed transient complete right bundle-branch block. Transient left posterior hemiblock has also been reported as a response to the exercise test.<sup>11,12</sup>

Two cases of transient, pure, left posterior hemiblock which occurred during the course of acute lateral infarction, were recently reported by Wagner and Rosenbaum.

Two features of the electrocardiographic presentation of our case are worthy of special comment. These are considered below.

### Masking Effect of ECG Manifestations of Anterolateral Ischaemia by Left Posterior Hemiblock

As with other forms of intraventricular conduction disturbance, such as right and left bundle-branch block, the Wolff-Parkinson-White syndrome and ectopic ventricular beats, the T wave may reflect secondary changes, i.e. changes which do not represent primary myocardial involvement, but are secondary to the abnormal intraventricular conduction. This results in a T-wave vector that is opposite in direction to the main QRS vector. The principle is illustrated in Fig. 3—A reflects normal intraventricular conduction with the frontal plane QRS and T-wave vectors similarly directed; B illustrates left anterior hemiblock, with the QRS vector directed superiorly and to the left, whereas the T-wave vector is directed inferiorly and to the right; C illustrates left posterior hemiblock, with the QRS vector directed inferiorly and to the right, whereas the T-wave vector is directed superiorly and to the left, i.e. towards standard lead I and lead AVL. The T waves will consequently be upright in these leads.

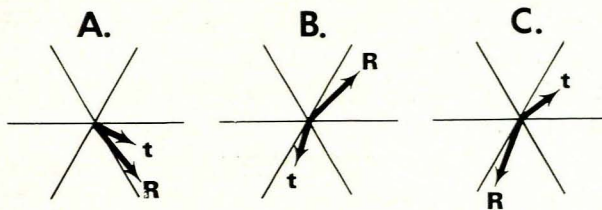


Fig. 3. Diagrams illustrating frontal plane QRS-T vector relationship with normal intraventricular conduction—diagram A; left anterior hemiblock—diagram B; and left posterior hemiblock—diagram C.

The advent of left posterior hemiblock may thus normalise the low to inverted T waves of anterolateral myocardial ischaemia in standard lead I and lead AVL. This is clearly evident in this case. Electrocardiograms A and C of Fig. 2 show the low to inverted T waves in standard lead I and lead AVL of anterolateral myocardial ischaemia. Electrocardiogram B shows the normalisation of this manifestation with the advent of the left posterior hemiblock.

### Planar Reorientation of QRS Forces

It is evident, from the tracings of this case, that when right bundle-branch block is complicated by left posterior hemiblock, there is a planar reorientation of QRS forces from the horizontal plane to the frontal plane. The QRS

forces of uncomplicated intraventricular conduction tend to be dominantly orientated in the horizontal plane, so that the deflections of the horizontal plane leads tend to be of greater amplitude than those of the frontal plane leads. The proximity effect of the precordial electrodes also play a role in this phenomenon. With the advent of left posterior hemiblock, there is a reorientation of the QRS forces so that they tend to be dominantly orientated in the frontal plane. As a result, the deflections of the frontal plane leads tend to be of greater amplitude than those of the precordial leads; compare electrocardiograms A and C of Fig. 2 with electrocardiogram B.

## REFERENCES

1. Rosenbaum, M. B., Elizari, M. V. and Lazzari, J. O. (1968): *Los Hemibloqueos*. Buenos Aires: Paidos.
2. Kulbertus, H. and Colignon, P. (1969): *Brit. Heart J.*, **31**, 435.
3. Rosenbaum, M. B., Elizari, M. V. and Lazzari, J. O. (1969): *Amer. Heart J.*, **78**, 4.
4. Rosenbaum, M. B., Elizari, M. V., Lazzari, J. O., Nau, G. J., Levi, R. J. and Halpern, M. S. (1969): *Ibid.*, **78**, 306.
5. Rosselot, E., Ahumada, J., Spoerer, A. and Sepulveda, G. (1970): *Amer. J. Cardiol.*, **26**, 6.
6. Sepulveda, G., Rosselot, E., Prieto, M. E., Mordoh, I. and Ahumada, J. (1971): *Geriatrics*, **26**, 124.
7. Goldberg, L. H. and Schamroth, L. (1972): *J. Electrocardiol.*, **5**, 395.
8. Marriott, H. J. L. and Hogan, P. (1970): *Chest*, **4**, 342.
9. De Sousa, M. and Cerqueira-Gomes, M. (1970): *O Medico*, **18**, 565.
10. Scanlan, P. J., Pryor, R. and Blount, S. G. (1970): *Circulation*, **42**, 1135.
11. Kulbertus, H. E. and Humblet, L. (1972): *Amer. Heart J.*, **4**, 574.
12. Bobba, P., Salerno, J. A. and Casari, A. (1972): *Circulation*, **46**, 931.