

Variant (Prinzmetal's) Form of Angina Pectoris Manifesting in Complicating Ventricular Extrasystoles

L. SCHAMROTH, J. H. LEVENSTEIN

SUMMARY

A case of the variant (Prinzmetal's) atypical form of angina pectoris is presented. Secondary and primary changes affecting the S-T segment and T wave are discussed.

The features were also present, and indeed more marked, in complicating ventricular extrasystoles, one of which reflected the infarction pattern.

S. Afr. Med. J., 48, 1146 (1974).

In 1959 Prinzmetal *et al.*^{1,2} focused attention on an unusual form of angina pectoris, which has been termed the variant or atypical form of angina pectoris.

The distribution of the pain is identical with the classic form of angina pectoris, being substernal with radiation to the jaw and down the ulnar surfaces of the arms and being oppressive in character. Unlike the classic form of angina pectoris, however, the pain frequently occurs

spontaneously and is not necessarily related to effort or emotion. The pain is usually severe and of longer duration. It usually presents with a series of attacks which tend to be cyclical, recurring every few minutes with peaks of remarkable constancy, and frequently at the same time or times of each day. The waxing and waning periods of chest pain are often of equal duration, unlike the typical form of angina pectoris where the waning period is shorter and more abrupt than the waxing period. The attacks frequently progress to myocardial infarction, and it is noteworthy that the severe angina pectoris frequently disappears dramatically after such an infarction. The condition is usually associated with a grave prognosis. Recent reports have indicated that the variant angina pectoris with the typical electrocardiographic changes may also be precipitated by effort.³

Electrocardiographically, the variant form of angina pectoris has the following characteristics. There is transient elevation of the S-T segment in leads orientated to the apex and the adjacent anteroapical region, viz. leads V2 to V6, particularly leads V4 and V5. Occasionally, and especially with vertical hearts, the manifestation appears particularly in standard leads II, III and lead AVF. The associated T waves are usually upright, but may be inverted. When the T wave is upright, the elevated S-T segment will have a concave-upward or upward sloping appearance. This manifestation is similar to the hyperacute early injury phase of acute myocardial infarction. When the associated T wave is inverted, the elevated S-T

Baragwanath Hospital and University of the Witwatersrand,
Johannesburg

L. SCHAMROTH, M.D., D.S.C., F.R.C.P., F.R.S. (S.A.F.)

Cape Town

J. H. LEVENSTEIN, M.B. CH.B., M.F.G.P. (S.A.)

Date received: 24 January 1974.

segment will tend to have a convex-upward appearance. The R wave of the QR complex may become taller than normal. This is most probably an expression of early acute 'injury' block.

Other electrocardiographic features of coronary insufficiency may be associated with the changes of the variant form of angina pectoris. These include U-wave inversion, ventricular extrasystoles, and even ventricular tachycardia.³ Varying degrees of A-V block have also been reported.

The S-T segment elevation is the result of epicardial injury affecting the anterior epicardial surface of the left ventricle. And since the S-T segment vector is always directed towards the surface of injury, it will be directed towards the anterior surface of the left ventricle, resulting in elevated S-T segments in leads orientated to this surface, particularly leads V4 to V6. This contrasts with the classic form of angina pectoris which is an expression of subendocardial injury, and where the S-T segment vector is consequently directed towards the injured endocardium—resulting in depressed S-T segments in the left lateral leads.

The variant form of angina pectoris, although not uncommon in clinical practice, has nevertheless been poorly reported in the literature, there being only 51 cases until 1970.⁴ This is probably due to the fact that it is difficult to document the attacks since they usually

occur spontaneously. Indeed, sporadic reports⁵ had appeared before the description by Prinzmetal and his associates.

In the majority of cases, the disorder of variant angina pectoris is due to marked narrowing of a major coronary artery or one of its branches.⁶⁻⁸ The condition may also be due to a severe spasm of a major coronary artery and, indeed, two recent reports reflected normal or near-normal coronary arteries on a coronary angiogram.^{9,10} Most of the available evidence supports the concept that the variant angina pectoris constitutes presumptive evidence that there is a single severe obstruction in a major coronary artery or one of its branches.

The following case illustrates the typical electrocardiographic features of the variant form of angina pectoris. These features were also present and indeed more marked in the complicating ventricular extrasystoles, one of which reflected the infarction pattern.

The electrocardiograms in Fig. 1 were recorded from a 59-year-old woman who presented with a history of having had a severe retrosternal pain lasting 35 minutes, 12 hours before consultation. She had suffered from coronary artery disease for 12 years, having had a previous myocardial infarction and angina pectoris. Over the few weeks before consultation she had become increasingly more tired and her attacks of angina pectoris

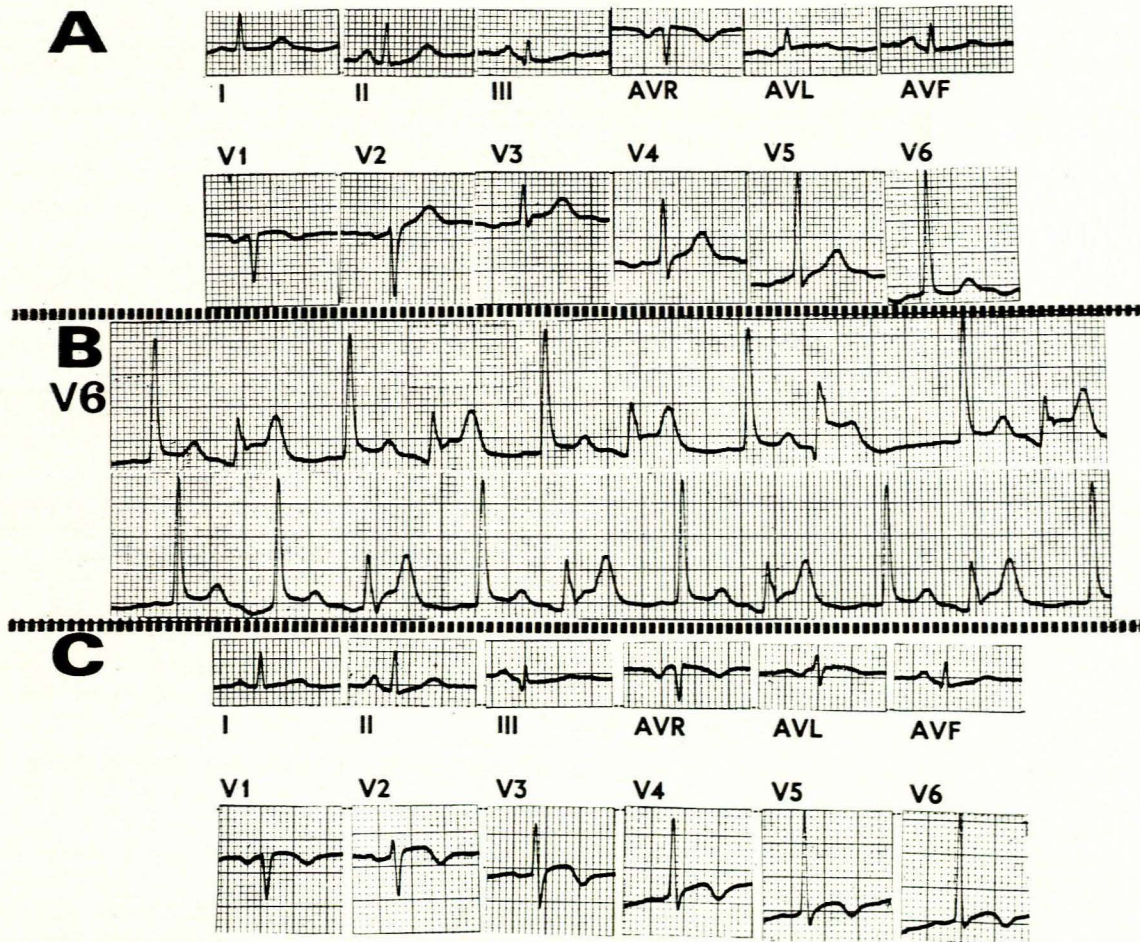


Fig. 1. Electrocardiograms. A—tracing recorded at rest with patient asymptomatic; B—tracing recorded during spontaneous chest pain; and C—tracing recorded the following day (see text).

more frequent and severe. On examination she had a pulse rate of 84 beats/min and her blood pressure was 140/80 mmHg.

Electrocardiogram A of Fig. 1 was recorded at rest while the patient was asymptomatic. The tracing is equivocal. The T waves tend to be a little symmetrical in standard leads I and II, and leads V2 to V6. There is also a tendency to horizontality of the S-T segment in standard lead I and lead V6. The normal initial small Q waves are absent in the left lateral leads—leads V4 to V6 and standard lead I—suggesting the possible presence of early incomplete left bundle-branch block. Electrocardiogram B (a continuous strip of lead V6) was recorded a few seconds later and concomitant with the development of severe spontaneous substernal chest pain. The pain had, in fact, begun when lead V6 of electrocardiogram A was being recorded. The sinus rhythm is now complicated by ventricular extrasystoles. The conducted sinus beats now clearly show a 1.5-mm S-T segment elevation. The associated T waves maintain their symmetry, perhaps a little more marked than in electrocardiogram A. The ventricular extrasystoles reflect these changes—as primary S-T segment and T-wave changes (see below)—more clearly. The S-T segments are markedly elevated to about 3 mm. The S-T segment configuration is clearly horizontal with a very sharp-angled ST-T junction. The associated T waves are tall and very symmetrical. No ensuing U wave is visible, thereby indicating a flattening of the U wave. In fact, there may be an ensuing depression, indicating some U-wave inversion.

The fourth ventricular extrasystole is slightly different. It has a shorter coupling interval (0.42 s as compared with the coupling interval of 0.49 s of the other ventricular extrasystoles). The S-T segment reflects a greater elevation of 4 mm. The ensuing T wave is less marked. The ensuing U wave reflects a clear inversion. The most striking feature, however, is the development of a small initial Q wave, followed by a tall R wave, taller than those of the other ventricular extrasystoles. These abnormal changes regressed within a few seconds to that of the pattern shown in electrocardiogram A.

Electrocardiogram C was recorded the next day, and reflects coved and elevated S-T segments with inverted symmetrical T waves in leads V2 to V6. The QRS complexes reflect a slightly lower R wave in lead V6 than in either electrocardiogram A or electrocardiogram B, but otherwise reflect no change from that of tracing A. The patient experienced several further attacks of angina pectoris and the electrocardiogram evolved to the typical appearance of an anterior wall myocardial infarction.

DISCUSSION

Electrocardiogram A was equivocal and suggested the possible presence of coronary insufficiency as evidenced by the slight horizontality of the S-T segments in standard lead I and lead V6, the absence of initial Q waves in the left lateral leads, and the rather symmetrical T waves in the left lateral leads. Electrocardiogram B reflects the classic electrocardiographic features of the variant—Prinzmetal's atypical angina. These features are evident in both the conducted beats and the ventricular extrasystoles (see below), and represent the onset of severe coronary insufficiency. Electrocardiogram C reflects the parameters

of epicardial 'injury' and 'ischaemia', and represents an anterolateral subepicardial infarction.

When an electrocardiogram reflects the presence of complicating ventricular extrasystoles or other forms of ectopic ventricular rhythm, the presence of primary myocardial disease, such as coronary insufficiency and myocardial infarction, may be evident from the morphology of the ectopic beats. In myocardial infarction, for example, the abnormal electrocardiographic parameters of the in-

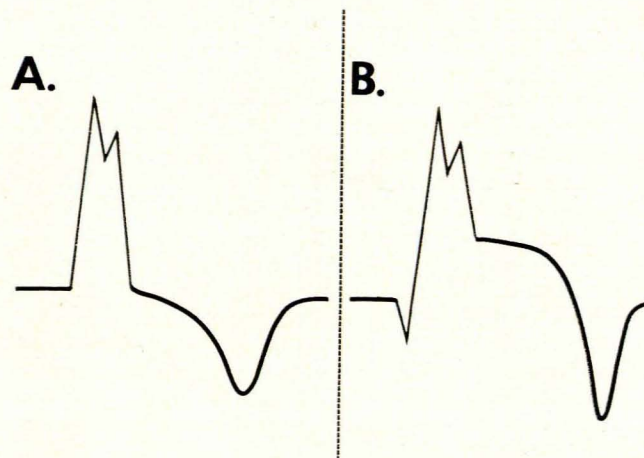


Fig. 2. A—an uncomplicated ectopic ventricular beat with secondary S-T segment and T-wave changes; and B—an ectopic ventricular beat with primary S-T segment and T-wave changes (see text).

farction may affect the QRS complex, the S-T segment and the T wave, and may be more obvious and more definitive in the ectopic beats than in the conducted sinus beat.¹¹⁻¹²

The necrosis of myocardial infarction is suggested when an ectopic ventricular beat with a dominantly positive QRS complex is preceded by an initial Q wave, no matter how small (Fig. 2B). The initial Q wave may of course be of considerable magnitude.

The injury and ischaemia of acute myocardial infarction are suggested when the ectopic ventricular beat reflects primary S-T segment and T-wave changes. In the presence of abnormal intraventricular conduction, as occurs for example with bundle-branch block, Wolff-Parkinson-White syndrome and ectopic ventricular beats, the associated segment and T wave reflect changes which are merely secondary to the abnormal intraventricular conduction, there being no primary myocardial abnormality. These secondary changes affect the direction of the S-T segment and T-wave vectors, the shape of the S-T segment, and the shape of the T wave, and are considered below.

SECONDARY CHANGES AFFECTING THE S-T SEGMENT AND T WAVE

Direction of the S-T Segment and T-Wave Vectors

The S-T segment and T wave are normally deviated opposite in direction to the major QRS deflection or, more accurately, opposite in direction to the terminal QRS deflection (Fig. 2A). Thus, when the terminal QRS

deflection is positive or upright, the S-T segment and T wave will be negative or depressed, and vice versa. This may be expressed vectorially in the following manner. The angle between the terminal QRS vector and the S-T segment vector is greater than 110° on the frontal plane hexaxial reference system, and may be as wide as 180° . The T-wave vector, too, is separated from the terminal QRS vector by an angle greater than 110° . Note that the S-T segment and T-wave vectors are roughly parallel on the frontal plane hexaxial reference system, i.e. they have nearly the same direction.

Shape of the S-T Segment

The S-T segment usually has a straight downward slope, or a downward slope that is slightly convex upward. The S-T segment does not 'hug' the baseline appreciably, i.e. it is not iso-electric, in most cases beginning its downward course from the QRS complex almost blunt (Fig. 2A).

Shape of the T Wave

The T wave of an uncomplicated ectopic ventricular complex is asymmetrical with a shallow proximal limb and a steeper distal limb. The apex tends to be somewhat blunt (Fig. 2A).

PRIMARY CHANGES AFFECTING THE S-T SEGMENT AND T WAVE

The diagnosis of myocardial infarction or acute myocardial injury is suggested when the S-T segment and/or T wave manifest primary changes, i.e. changes which are not merely secondary to the abnormal intraventricular conduction of the uncomplicated ventricular extrasystole, but reflect a primary abnormality of repolarisation. These primary changes are as follows.

Elevation of the S-T Segment

The S-T segment deviates in the same direction as the terminal or dominant QRS deflection. Thus, in the case of an ectopic ventricular beat with a dominantly positive QRS deflection, the S-T segment will be elevated (Fig. 2B). This may be expressed vectorially as an angle of less than 110° between the terminal QRS vector and the S-T segment vector. Note that the normal S-T segment vector very nearly has the same direction as the T-wave vector, i.e. the two vectors are roughly parallel on the frontal plane hexaxial reference system. Thus, when in the presence of marked QRS prolongation due to either bundle-branch block or ventricular ectopy, the S-T segment vector is not more or less in the same direction as the T-wave vector, a primary S-T segment change is suggested, and may represent the injury pattern of acute myocardial infarction.

Coving of the S-T Segment

The S-T segment may, in addition to elevation, reflect the characteristic upward coving of the myocardial in-

farction 'injury' pattern (Fig. 2B). In other words, the normal, almost straight downward slope of the S-T segment of uncomplicated ventricular extrasystole is changed to an upward convexity.

Symmetry and Sharpening of the T Wave

The T wave tends to become sharply pointed, and its limbs more symmetrical. This may be the earliest or only sign suggestive of infarction. When this occurs, the S-T segment need not be elevated, but nevertheless hugs the baseline, having an appreciable iso-electric period in contrast with the negligible iso-electric period in the uncomplicated ectopic ventricular beat.

Slope Elevation of the S-T Segment

The ectopic ventricular beat may, at times, reflect marked elevation of the S-T segment, whose configuration is straight and horizontal, or straight with a slightly upward slope. This is analogous to the slope elevation of the hyperacute injury phase of myocardial infarction. This manifestation is clearly evident in the ventricular extrasystoles of this case, which show horizontal or slope elevation of the S-T segment with a sharp-angled ST-T junction and symmetrical T waves. The fifth ventricular extrasystole not only reflects the variant form of Prinzmetal's angina pectoris, but clearly reflects all the parameters of acute myocardial infarction—the initial Q wave, the elevated S-T segment, and the inverted T wave. This ventricular extrasystole is recorded with a shorter coupling interval, and thus indicates that a ventricular extrasystole which occurs very early during incomplete recovery of the ventricular myocardium and during the attack of the variant form of angina, may actually reflect the parameters of myocardial infarction. It is well known that these parameters—necrosis, injury and ischaemia—do not necessarily parallel the pathological parameters of necrosis, injury and ischaemia, but rather represent biochemical change within the myocardial cell. This case indicates that these biochemical changes may be present in the incompletely recovered cell in the absence of the manifest electrocardiographic changes of myocardial infarction, true or permanent myocardial infarction merely reflecting a prolonged state of this biochemical abnormality.

REFERENCES

1. Prinzmetal, M., Kennamer, R., Merliss, R., Wada, T. and Bor, N. (1959): *Amer. J. Med.*, **27**, 374.
2. Prinzmetal, M., Ekmekci, A., Kennamer, R., Kwoczynski, J. K., Shubin, H. and Toyoshima, H. (1960): *J. Amer. Med. Assoc.*, **1**, 794.
3. Schamroth, L. and Jaspán, J. B. (1973): *Heart and Lung*, **2**, 431.
4. Ruser, H. R. (1970): *Z. Kreislauf-Forsch.*, **9**, 849.
5. Kroop, I. G., Jaffe, H. L. and Master, A. M. (1949): *Bull. N.Y. Acad. Med.*, **25**, 465.
6. Fortuin, N. J. and Friesinger, G. C. (1970): *Amer. J. Med.*, **49**, 459.
7. MacAlpin, R. N. and Kattus, A. A. (1967): *Circulation*, **35-36** (suppl. 2), p. 176.
8. MacAlpin, R. N. (1970): *N. Engl. J. Med.*, **282**, 1491.
9. Gianelly, R., Magler, F. and Harrison, D. C. (1968): *Calif. Med.*, **108**, 129.
10. Whiting, R. B., Klein, M. D., van der Veer, J. and Lown, B. (1970): *New Engl. J. Med.*, **282**, 709.
11. Bisteni, A., Medrano, G. A. and Sodi-Pallares, D. (1961): *Brit. Heart J.*, **23**, 521.
12. Sodi-Pallares, D., Cisneros, F., Medrano, G. A., Bisteni, A., Testelli, M. R. and Micheli, A. D. (1963): *Prog. Cardiovasc. Dis.*, **6**, 107.
13. Levenstein, J. H. and Schamroth, L. (1974): *Heart and Lung* (in press).