

Pathology of Gaucher's Disease

L. B. KAHN

SUMMARY

A review of the pathology of 12 cases of non-neuropathic type Gaucher's disease, diagnosed over a 38-year period, 1935 to 1973, is presented. One of these patients is described in detail and an unusual association with a splenic epidermoid cyst in an unaffected sibling is documented. Histochemical studies have confirmed the presence of an abundance of acid phosphatase in the cytoplasm of the Gaucher cells, while ultrastructural examination has confirmed the presence of single membrane-bound sacs containing tubular structures with a right-handed helical twist.

S. Afr. Med. J., 48, 1098 (1974).

PATIENTS AND METHODS

Cases included in this study were those diagnosed from 1935 to 1973 in the Department of Pathology at the University of Cape Town Medical School (Groote Schuur and Red Cross Hospitals). There were 12 such patients, in 2 of whom detailed clinical information was unobtainable.

For light microscopy, sections from the spleen, bone marrow, liver and lymph nodes were stained with haematoxylin and eosin, PAS, PAS-diacetate and Perl's Prussian blue reaction. For enzyme histochemistry, fragments of fresh spleen from 2 patients were immediately frozen in liquid nitrogen, frozen sections prepared and these stained for acid and alkaline phosphatase activity (Gomori method) and non-specific esterase activity (Gomori method).¹

For electron microscopical examination, minced fragments of fresh spleen from 2 patients were transferred to phosphate-buffered glutaraldehyde and postfixed in Palade's solution. They were then dehydrated in graded alcohols and embedded in resin (Spurr's). Thin sections were stained with aqueous uranyl nitrate and lead citrate and examined with an electron microscope. For ultrastructural examination with a negative staining technique,² splenic tissue that had been fixed in 10% formaldehyde solution as well as fresh splenic tissue that had been deep-frozen were each ground up in 1% ammonium acetate. The suspensions were mixed with equal volumes of 1% phosphotungstic acid and a drop of each placed on Formvar carbon-coated grids. The drops were then removed with filter paper and the grids allowed to dry before being examined with an electron microscope. A shadowing technique was also

used in which the material was ground up in 1% ammonium acetate and then placed on a grid and dried as above. The dried grid was examined in a vacuum-coating unit at an angle of 50°.

REVIEW OF CLINICOPATHOLOGICAL FEATURES

The 12 patients include 8 adults and 4 children (Table I). The absence of neurological manifestations in any of them indicates that none were of the neuropathic type. All patients were White. Four were atypical in their clinical presentation in that they had evidence of severe disease necessitating splenectomy between the ages of 1 year 5 months and 6 years. None of these 4 patients were Jewish. At least 5 of the 8 patients, who presented in a more typical way, were Ashkanazi Jews; one was a non-Jew and the ethnic group of the remaining 2 patients was not known.

The commonest mode of presentation was splenomegaly with hypersplenism. At least 4 patients had radiological evidence of bony involvement and this caused severe disability in 2 of them. One patient also developed restrictive lung disease, presumably on the basis of infiltration by Gaucher cells. A sister of the patient (case 11), whom we report in detail, had a splenectomy for an epidermoid cyst of the spleen, but had no evidence of Gaucher's disease. Other manifestations of the disease include pin-pingulacae and skin pigmentation.

DETAILED REPORT OF CASE 11

A 59-year-old White male was found to have had an enlarged spleen about 17 years previously. In January 1965 he suddenly developed tinnitus and impaired hearing in his left ear. In 1968 he had a transurethral resection of a hyperplastic prostate gland and was also found to have an elevated serum acid phosphatase of non-prostatic origin. The urologist suggested the diagnosis of Gaucher's disease. Early in 1971 he developed petechiae and ecchymoses of his hands and feet, and was found to have a low platelet count. A bone marrow aspirate and trephine biopsy confirmed the diagnosis of Gaucher's disease. He was admitted to hospital in September 1971 for a splenectomy. At that time his spleen was palpable 3 cm below the left costal margin and he had a few purpuric spots on his hands and feet. His haemoglobin concentration was 14.5 g/100 ml, white cell count 7 600/mm³ and platelet count 65 000/mm³. The serum acid phosphatase was 6.3 King-Armstrong units (normal < 3) and the alkaline phosphatase 7.2 King-Armstrong units (normal 3 - 13). X-ray films of the chest, spine and pelvis showed no abnormality. A spleen weighing 872 g was removed

Department of Pathology, Groote Schuur Hospital and University of Cape Town

L. B. KAHN, M.B. B.CH., M.MED. (PATH.)

Date received: 14 January 1974.

TABLE I. REVIEW OF CASES OF GAUCHER'S DISEASE DIAGNOSED IN THE DEPARTMENT OF PATHOLOGY

Case	Age/ Sex	Ethnic groups*	Clinical features	Pathology			
				Spleen (splenectomy)	Bone marrow	Liver	Lymph nodes
1.	2 yrs M	NJ	?	565 g and 12 g spleniculus		+	
2.	1 yr 5 mo. F	NJ	Anaemia and hepatosplenomegaly.	552 g			+
3.	4 yrs F	NJ	Progressive splenomegaly since age of 5 mo.; pancytopenia (Hb 5,8 g/100 ml, WCC 3 500/mm ³ ; platelets 43 000/mm ³); hepatomegaly; X-ray (flask-shaped deformity of femora); blood picture reverted to normal post-splenectomy.	± 1200 g	+		
4.	15 yrs F	NJ	Splenectomy at age of 6 yrs; involvement of femora and right humerus with pathological fractures of the latter; recently cyanosed with evidence of restrictive lung disease (pO ₂ 50 mmHg); hepatomegaly.	Not available.	+		
5.	44 yrs M	?	Pancytopenia (platelets 80 000/mm ³) and splenomegaly.	Massive enlargement and large spleniculus.			
6.	32 yrs M	?	Pancytopenia and splenomegaly.	3 300 g	+		
7.	23 yrs M	NJ	Pancytopenia (Hb 6 g/100 ml, WCC 1 600/mm ³ , platelets 96 000/mm ³); X-ray (area of sclerosis in ileum near right sacro-iliac joint); well several years post-splenectomy.	Not available.	+		
8.	21 yrs F	J	?	1 896 g			+
9.	42 yrs M	J	Gaucher's disease diagnosed at age of 8 yrs; at age 42 yrs presented in severe congestive cardiac failure, predominantly right heart failure, resulting from severe kyphoscoliosis and probable pulmonary infiltration by Gaucher cells; massive splenomegaly and hepatomegaly, pingueculae and yellow-brown skin pigmentation; severe bony involvement of dorsal and lumbar vertebrae, pelvis and femora; elevated serum phosphatase; platelets 62 000/mm ³ ; developed acute peripheral vascular insufficiency with gangrene of feet and fingers and died.		+		
10.	23 yrs M	J	Brother of case 9; diagnosed as Gaucher's disease at age 6 yrs on basis of hepatosplenomegaly, bony changes in lower femora and upper tibia, and Gaucher cells in marrow aspirate; died during attempted removal of large spleen.	8 500 g			
11.	59 yrs M	J	Tip of spleen for about 15 years; raised acid phosphatase found at time of prostatectomy for hyperplasia; petechiae and ecchymoses 3 yrs later; platelets 50 000/mm ³ ; well 2 yrs post-splenectomy.	872 g	+	+	
12.	32 yrs	J	Bruises easily, mild thrombocytopenia (platelets 60 000 - 114 000/mm ³); hepatosplenomegaly; no further therapy.		+		

* NJ = Non-Jew; J = Jew.

+ Biopsied and Gaucher cells demonstrated.

(Fig. 1) and a wedge biopsy of the liver performed. Postoperatively the platelet count rose rapidly to about 350 000/mm³ and eventually settled at 100 000/mm³.



Fig. 1. Enlarged spleen from case 11 showing multiple pale, coalescing nodules resulting from the accumulation of Gaucher cells.

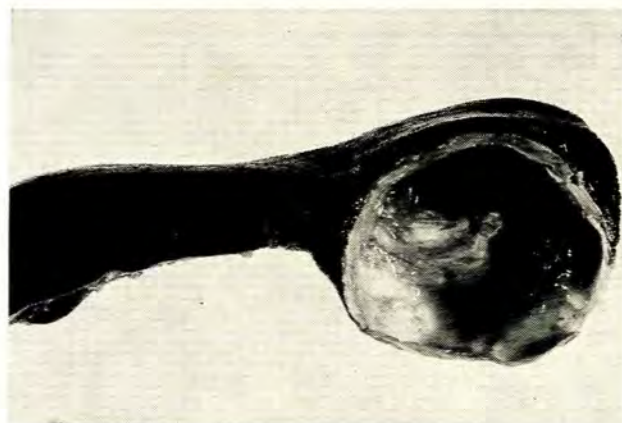

Fig. 2. Epidermoid cyst of the spleen.

His 60-year-old sister had had a splenectomy in 1955. She had noticed a lump in the left hypochondrium for the preceding 18 years and it had not changed in size. The resected spleen weighed 240 g and contained a cyst at the lower pole (Fig. 2). The cyst measured 6.0 cm in diameter and was filled with fluid containing many cholesterol crystals. The lining of the cyst was composed of simple cuboidal and stratified squamous epithelium and there was dystrophic calcification of the surrounding fibrous tissue. These features were typical of an epidermoid cyst of the spleen.³ Multiple sections from the splenic parenchyma showed no infiltration by Gaucher cells. This case has been reported previously as a calcified cyst of the spleen.⁴ This sibling is still alive and well. A second sister died of a subdural haematoma. The patient has 7

other siblings, one of whom is said to have an enlarged spleen. Estimations of β -glucosidase on lymphocytes from several members of this family have been reported.⁵

PATHOLOGICAL FEATURES OF NON-NEURONOPATHIC TYPE GAUCHER'S DISEASE

Light Microscopical and Histochemical Features

The accumulation of glucocerebroside in histiocytic cells of the reticulo-endothelial system results in the formation of the typical Gaucher cell. Progressive accumulation of Gaucher cells causes enlargement of the spleen, liver and lymph nodes, but these cells may be found in many tissues and organs. The splenic enlargement may be massive, as in patient 10, whose splenic mass was 8 500 g. Appel and Markowitz⁶ recorded a splenic mass of 8 910 g in a 22-year-old female patient, probably the largest mass yet recorded in Gaucher's disease. Accumulation of Gaucher cells also causes progressive replacement of the bone marrow and is associated with bone resorption and expansion with resultant pathological fractures. This infiltration results in the typical flask-shaped deformity of the femora.

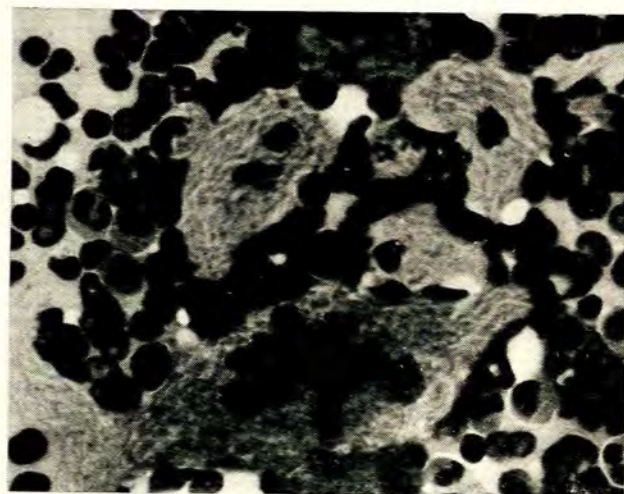


Fig. 3. Bone marrow aspirate showing a cluster of uninucleate and multinucleate Gaucher cells. The delicate cytoplasmic striations are well shown (H. and E. \times 640).

The Gaucher cell measures between 20-100 μ in diameter and may be uninucleate or multinucleate (Figs 3 and 4). It has a small round or oval nucleus and abundant, pale-pink cytoplasm when stained with haematoxylin and eosin. The most distinctive feature is the presence of delicate cytoplasmic striations; these impart to the cytoplasm the so-called 'wrinkled tissue paper' or 'crumpled silk' appearance. Red blood cells may occasionally be seen within the cytoplasm, and degradation of these cells may be a major source of the stored gluco-




Fig. 4. Photomicrograph of spleen showing clusters of pale-staining Gaucher cells. The cytoplasmic striations and intensity of cytoplasmic staining are enhanced by the PAS stain shown in the inset (H. and E. $\times 200$; inset (left) PAS $\times 200$).

cerebroside.⁷⁻⁹ In most cases some positive staining is observed in the Perl's Prussian blue reaction, and this may also be a result of red cell degradation.⁸ The Gaucher cells stain positively with the PAS stain and this is not abolished by prior treatment with diastase (Fig. 4, inset). The cells are rich in esterase and in acid phosphatase activity, which are localised within the intertubular matrix of the lysosomes.^{10,11} Histochemical studies in 2 patients in our series have confirmed these observations. The Gaucher cells are almost certainly the source of the raised acid phosphatase noted in the blood of patients with Gaucher's disease. Heterozygotes are found to have a normal level of this enzyme in the serum.¹⁰ By light microscopical examination cells similar to those of Gaucher's disease have been observed in the marrow in chronic myeloid leukaemia.¹²⁻¹⁴ Their formation is believed to be the result of an increased turnover of glucocerebroside resulting from the breakdown of white blood cells. These cells differ from true Gaucher cells in that they contain an excess and not an absence of β -glucosidase; the increased enzyme activity is, however, insufficient to metabolise the substrate excess. High resolution electron microscopical examination demonstrated distinct differences between the inclusions in these cells as compared with those in Gaucher's disease.

Ultrastructural Features

The ultrastructural appearance of the Gaucher cell is quite characteristic. The cytoplasm contains numerous elongated and tapering single membrane-bound sacs (Fig. 5). These are considered to be lysosomes because of their acid phosphatase activity.⁹ They contain tubular structures arranged in more or less parallel arrays (Fig. 5). Individual tubules measure between 120 and 750Å in diameter but are fairly constant in each cell. They may measure up to 5 μ in length.¹⁵ On cross-section they appear to have an electron-lucent central core surrounded




Fig. 5. Electron photomicrograph showing part of a Gaucher cell containing numerous elongated and tapering membrane-bound sacs. Tubular structures sectioned longitudinally and transversely are seen within these sacs (aqueous uranyl nitrate and lead citrate $\times 30\ 000$).

by a wall composed of fine fibrils. Isolated and purified glucocerebroside has been shown to have a similar ultrastructural appearance.⁸

Negative staining of these tubular structures has shown that the surrounding filaments twist around the long axis of the tubule as a right-handed helix.^{2,16} Our studies with negatively stained material and using a shadowing technique confirmed the right-handed twist, but examination of fortuitously fractured tubules suggests that these may be composed of twisted laminar or membranous structures rather than peripherally arranged filaments (Fig. 6). Similar tubular structures have also been demonstrated in Krabbe's disease, a storage disease resulting from a deficiency of galactose cerebrosidase.^{17,18} In negatively stained preparations, the fibrils of Gaucher's disease have



Fig. 6. Negatively stained preparation showing spiral structure of Gaucher tubules. The pattern at a fractured extremity of one of these suggests a laminar rather than a filamentous structure (arrow) (phosphotungstic acid $\times 165\ 000$).

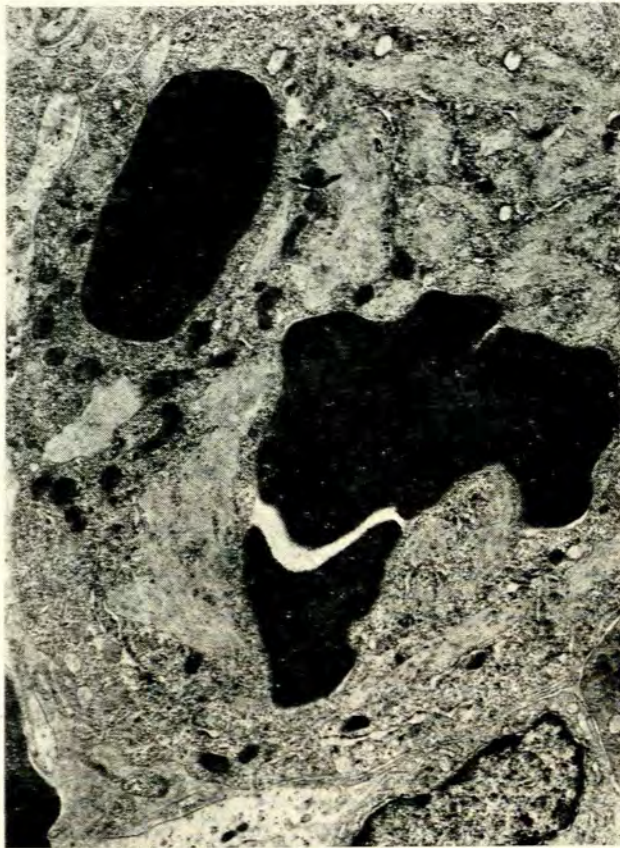

Fig. 7. Electron photomicrograph showing red blood cells within the cytoplasm of a Gaucher cell (aqueous uranyl nitrate and lead citrate $\times 9000$).

an 80Å periodicity, compared with a 40-60Å periodicity in Krabbe's disease. In addition, a second type of tubule with angular profiles on cross-section is seen in Krabbe's disease.

Similar inclusions have also been observed in storage cells resembling Gaucher cells in chronic myeloid leu-

kaemia. By high-resolution electron microscopical examination, however, the linear densities within the cytoplasmic sacs do not have a clearly identifiable tubular structure, and the fibrils comprising them do not twist.¹³

Structures resembling ingested red blood cells have been demonstrated ultrastructurally within the cytoplasm of Gaucher cells in juxtaposition to the tubular structures.^{7,9} We confirmed the presence of red blood cells surrounded by a single membrane within the cytoplasm of the Gaucher cells (Fig. 7). It has therefore been suggested that ingested red blood cells may be the major source of the stored glucocerebroside. Green *et al.*¹⁹ demonstrated intact platelets within Gaucher cells by electron microscopical examination and suggested that the Gaucher cell may play an important role in the pathogenesis of the thrombocytopenia. We have been unable to corroborate this finding. Vogel and Beres²⁰ attribute the thrombocytopenia to a shift of platelets from the intravascular to a splenic pool composed of partially collapsed side passages communicating with the sinuses by 3- μ m openings in the basement membrane. Platelets pass readily through such openings and are thus more easily sequestered than red blood cells.

REFERENCES

1. Bancroft, J. D. (1967): *An Introduction to Histochemical Technique*, pp. 187, 188, 190-192. London: Butterworths.
2. Brooks, S. E. H. and Audretsch, J. J. (1973): *Arch. Path.*, **95**, 226.
3. Tsakraklides, V. and Hadley, T. W. (1973): *Ibid.*, **96**, 251.
4. Schrire, T. (1956): *Med. Proc.*, **2**, 67.
5. Losman, M. (1974): *S. Afr. Med. J.*, **48** (in press).
6. Appel, M. F. and Markowitz, A. M. (1971): *J. Amer. Med. Assoc.*, **217**, 343.
7. Schneider, E. L., Brady, R. O. and Epstein, C. J. (1972): *J. Pediat.*, **81**, 1134.
8. Lee, R. E., Balcerzak, S. P. and Westerman, M. P. (1967): *Amer. J. Med.*, **42**, 891.
9. Pennelli, N., Scaravilli, F. and Zacchello, F. (1969): *Blood*, **34**, 331.
10. Crocker, A. C. and Landing, B. H. (1960): *Metabolism*, **9**, 341.
11. Hibbs, R. G., Ferrans, V. J., Cipriano, P. R. and Tardiff, K. J. (1970): *Arch. Path.*, **89**, 137.
12. Kettlove, H. E., Williams, J. C., Gaynor, E., Spivack, M., Bradley, R. M. and Brady, R. O. (1960): *Blood*, **33**, 379.
13. Lee, R. L. and Ellis, L. E. (1971): *Lab. Invest.*, **24**, 261.
14. Von Albrecht, M. (1966): *Blut*, **13**, 169.
15. Stanbury, J. B., Wyngaarden, J. B. and Fredrickson, D. S. (1972): *The Metabolic Basis of Inherited Disease*, 3rd ed., pp. 736-738. New York: McGraw-Hill.
16. Lee, R. E. (1968): *Proc. Nat. Acad. Sci. (Wash.)*, **61**, 484.
17. Yunis, E. J. and Lee, R. E. (1969): *Lab. Invest.*, **21**, 415.
18. *Idem* (1970): *Science*, **169**, 64.
19. Green, D., Battifora, H. A., Smith, R. T. and Rossi, E. C. (1971): *Ann. Intern. Med.*, **74**, 727.
20. Vogel, J. M. and Beres, P. (1971): *Amer. J. Clin. Path.*, **55**, 489.