

# Ruptured Cervical Aneurysm with Neurofibromatosis

M. A. P. SMITH, J. A. M. WHITE

## SUMMARY

A case is presented of spontaneous rupture of an aneurysm of a lateral branch of the right thyrocervical trunk in a patient suffering from diffuse neurofibromatosis. The operative findings are reported.

*S. Afr. Med. J.*, 48, 945 (1974).

## CASE REPORT

On 17 January 1973 a 65-year-old White male was admitted with a rapidly increasing swelling of the right lower neck developing within a few hours. The swelling was acutely painful immediately after the initial acute pain which occurred while the patient was resting. The pain radiated down the right arm accompanied by tingling and weakness of the whole arm, the patient experiencing a sense of impending doom. The patient's previous health had been good, although he had had neurofibromatosis for many years. One daughter had died from a dissecting aneurysm of the aorta at the age of 30 years.

On examination the patient was thin, asthenic and in obvious pain. His skin was pale, moist and cold, with temperature 35,5°C, pulse 120/min and blood pressure 130/85 mmHg. Chest and abdominal examination showed no abnormality. Examination of the central nervous system demonstrated decreased power in all muscles of the right shoulder girdle and arm, without sensory change. The cranial nerves were normal.

Local examination showed a single, smooth, oval, tender swelling on the right side of the neck, extending from the supraclavicular fossa into the posterior triangle and medially behind the sternomastoid muscle. The swelling was hard and non-pulsatile and did not transilluminate, and in some areas the tenderness was acute. No bruit was audible. An X-ray film of the chest (Fig. 1) showed a soft tissue shadow in the right lower neck.

Under conservative management the patient's condition deteriorated, with increasing local pain and slight increase in the size of the local swelling. The paresis of the muscles of the shoulder girdle and arm progressed to almost complete paralysis. Hoarseness and dysphagia were progressive and associated with the development of a right Horner's syndrome. On the sixth day after admission the

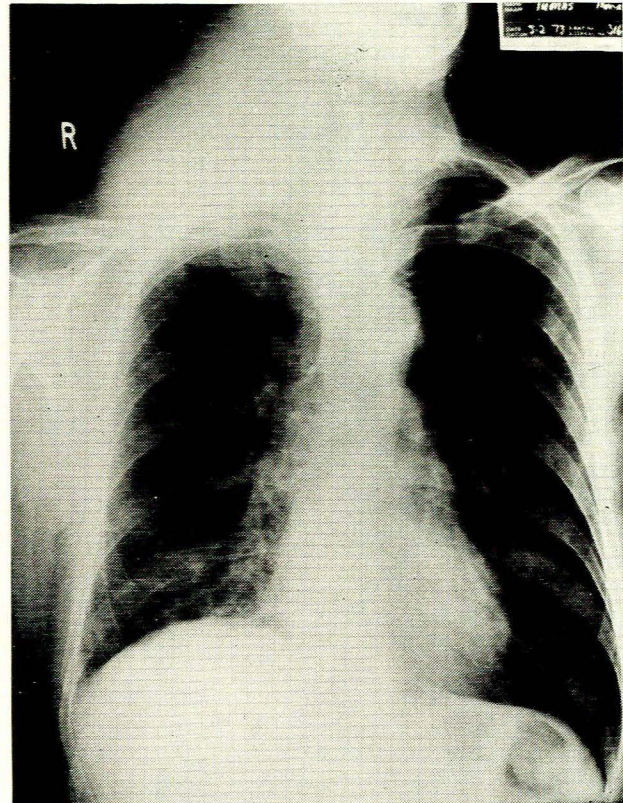


Fig. 1. Radiograph of chest on admission.

haemoglobin had fallen to 10,7 g/100 ml with a packed cell volume of 31%. The Wassermann reaction was negative. Indirect laryngoscopy showed a right recurrent nerve palsy. Screening of the diaphragm showed a normal range of movement on both sides. An arch aortogram showed no significant changes other than features of atherosclerosis. A transfusion of three pints of packed cells was administered.

## Operative Findings

Under general anaesthesia with endotracheal intubation, the cervical swelling was exposed through a long supraclavicular incision. On incising the tense deep cervical fascia a large quantity of altered blood clot was evacuated. Removal of these clots was followed by brisk arterial haemorrhage, controlled by digital pressure. The bleeding

Department of Surgery, Addington Hospital, Durban

M. A. P. SMITH  
J. A. M. WHITE

Date received: 3 December 1973.

was traced to the lateral aspect of the thyrocervical trunk, coming from the transverse cervical or supraclavicular branches. Formal control of the bleeding by suture was effected. A small aneurysmal sac, about the size of a garden pea, was removed.

Histological examination of the wall of the sac showed smooth muscle partly replaced by granulation tissue without specific histological features.

Further postoperative progress was uneventful. The Horner's syndrome disappeared in 3 weeks, with recovery of function of the right recurrent laryngeal nerve after 3 months. After 5 months there was residual paresis of the muscles of the right shoulder girdle and arm, but complete recovery of the intrinsic muscles of the hand. Wasting of the deltoid muscle with winging of the scapula (Fig. 2) remains obvious. Chest X-ray films are normal.

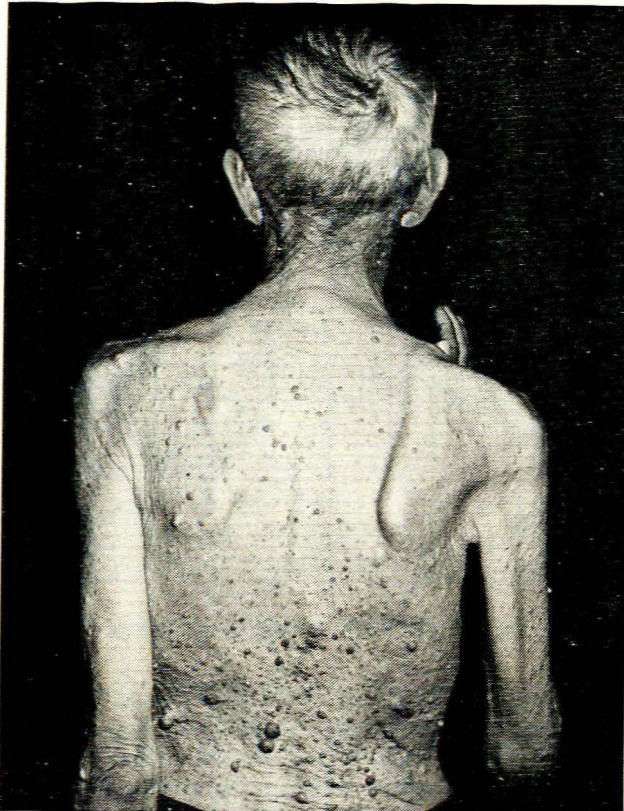

Fig. 2. Muscle wasting and winging of the scapula.

## DISCUSSION

The initial presentation strongly suggested the formation of a false aneurysmal sac from a major vessel in the

root of the neck. The relative normality of the arch aortogram was taken to exclude an aneurysm originating in either the subclavian or common carotid arteries. The lack of filling of the right thyrocervical trunk with contrast medium was attributed to technical factors. Alternatively the haemorrhage was thought to be possibly associated with bleeding into the soft tissues from a neurofibromatous tumour or neurofibrosarcomatous lesion associated with his generalised disease. The relentless progress of the cervical mass dictated the need for exploration.

Aneurysms of the abdominal and thoracic aorta are not uncommon in this patient's age group, but are rarer in peripheral arteries other than in primary and secondary divisions of the aorta. Spontaneous cervicomedial haematoma are rare disorders, first described by Capps,<sup>1</sup> who reported a fatal case of haemorrhage from a parathyroid adenoma. Masuelli and Della-Beffa<sup>2</sup> reported a case in a patient with hypertensive nephropathy, with spontaneous recovery. Beneditti-Valentini *et al.*<sup>3</sup> reported a case of spontaneous cervical haemorrhage in a patient with a goitre, who recovered. Epstein and Klassen<sup>4</sup> reported two cases of spontaneous cervicomedial haemorrhage in patients whose X-ray films showed calcification of the root of the neck. One patient survived.

Sandor and Cooke<sup>5</sup> described two further cases who bled from anomalous branches of the aorta. Both patients recovered. Further instances where bleeding originated from a dissecting aneurysm of the inferior thyroid artery and the patient recovered,<sup>6</sup> and two further cases,<sup>7,8</sup> one associated with thyroiditis of unknown aetiology, both of whom recovered, are reported in the literature.

Histological examination of the aneurysmal sac in our patient showed no specific features, but the features of the aortogram suggest that the patient suffered from diffuse arteriosclerosis. Cases of neurofibromatosis associated with aneurysms of the Circle of Willis<sup>9</sup> and of the renal artery<sup>10</sup> have been reported.

No common aetiology can be found in previously reported cases of spontaneous cervicomedial haematoma, or for an aetiological relationship with neurofibromatosis in the present case. The possibility of degenerative arterial disease causing rupture of a small artery in the neck with severe compression of adjacent structures should be remembered as a cause of this rare syndrome.

## REFERENCES

1. Capps, R. B. (1934): *Amer. J. Med. Sci.*, **188**, 800.
2. Masuelli, L. and Della-Beffa, A. (1953): *Haematologica*, **37**, 113.
3. Beneditti-Valentini, S., Corratu, M. and Rossi, F. (1958): *Minerva chir.*, **13**, 647.
4. Epstein, A. M. and Klassen, K. P. (1960): *J. Thorac. Cardiovasc. Surg.*, **39**, 740.
5. Sandor, F. and Cooke, R. T. (1964): *Brit. J. Surg.*, **51**, 682.
6. Golby, M. G. S. and Kay, J. M. (1965): *Ibid.*, **52**, 389.
7. Huber, J. P. (1970): *J. franc. Oto-rhino-laryng.*, **19**, 665.
8. Hennessy, T. P. J. and Martinez, J. A. (1970): *J. Irish Med. Assoc.*, **63**, 298.
9. Gibbons, J. R. P. and Brookes, J. P. C. M. (1967): *Brit. J. Clin. Pract.*, **21**, 360.
10. Martensson, O. (1970): *Nord Med. Ark.*, **84**, 1343.