

The Brachmann-De Lange Syndrome

REPORT OF TWO CASES

A. CICORIA

SUMMARY

Two patients with the Brachmann-De Lange syndrome are described. The condition is not uncommon and is characterised by mental retardation, a distinctive facies, synophrys of the eyebrows, a thin down-turned upper lip, hirsutism, growth failure and variable abnormalities of the extremities. The cause of the syndrome has not been identified.

S. Afr. Med. J., 48, 919 (1974).

A syndrome consisting of mental retardation and a characteristic physical appearance was described independently by Brachmann¹ in 1916 and by Cornelia de Lange in 1933.¹ The patients are strikingly similar in appearance, with bushy confluent eyebrows, an antimongoloid slant of the eyelids, thin lips with down-turned mouth angles, and variable skeletal abnormalities. Up to 1971 over 200 patients with this syndrome have been reported,² but the incidence is probably much higher. In most cases features are so characteristic on physical examination that diagnosis presents no difficulty. There are no specific laboratory tests to confirm the diagnosis. Although chromosomal abnormalities have been reported, most patients have a normal karyotype. Two additional cases encountered recently are presented.

CASE REPORTS

Case 1

A Black female patient aged 17 months was admitted to hospital because of failure to thrive, bronchopneumonia and kwashiorkor. The parents, 3 older sisters and 2 older brothers were physically and mentally normal. There was no history of significant family illness or exposure to drugs during pregnancy and the young parents were not related. The patient was the product of a full-term pregnancy and normal delivery. Fetal movements, however, had been feeble compared with previous pregnancies. Body weight at birth was 2 000 g.

After birth there were three episodes of respiratory infection with difficulty in sucking and the child did not take feeds well during the whole of the first year. She smiled for the first time at the age of 4 months, sat up at 10 months and was not yet able to crawl.

On examination the state of nutrition was poor, the body weight being 5,2 kg, length 65 cm and head circumference 38 cm. Most of the important physical features are shown in Fig. 1. The scalp hair was confluent with lanugo over the forehead and temporal area and there was a low hairline at the nape of the neck. There was hirsutism of the maxillary area, a slight moustache and her neck was short. The eyebrows were bushy, the eyelashes long and curly. The nose had anteverted nostrils, a depressed bridge and there was a wide upper lip. The lips were thin and curved downwards at the angles of the mouth ('carp-like' mouth). The teeth had not erupted. Both elbows could not be completely extended. The hands, small, with a single transverse palmar crease, had the characteristic appearance, with fingers in semiflexion and the thumbs short and hidden in the palms due to more proximal implantation than normal. There was clinodactyly of the right fifth finger with single flexion creases of both fifth fingers (Fig. 2).

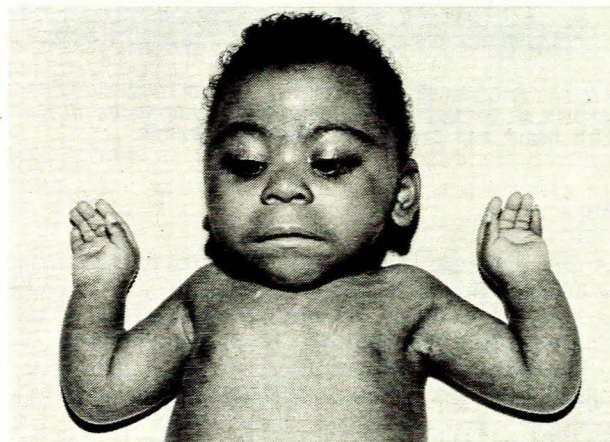


Fig. 1. Typical facial features. Bilateral micromelia with fingers in semiflexion and elbows in flexion.

Routine laboratory tests and chromosomal analysis revealed no abnormalities. The radiological bone age was between 9 and 12 months. There was hypoplasia with pointing of the proximal ends of both radii as well as hypoplasia of the first metacarpals. The clinodactyly of the right fifth finger was due to hypoplasia of the middle phalanx. The patient remained severely retarded and failed to thrive in spite of an adequate diet.

Department of Paediatrics, University of Pretoria
A. CICORIA, M.B. CH.B.

Date received: 3 December 1973.

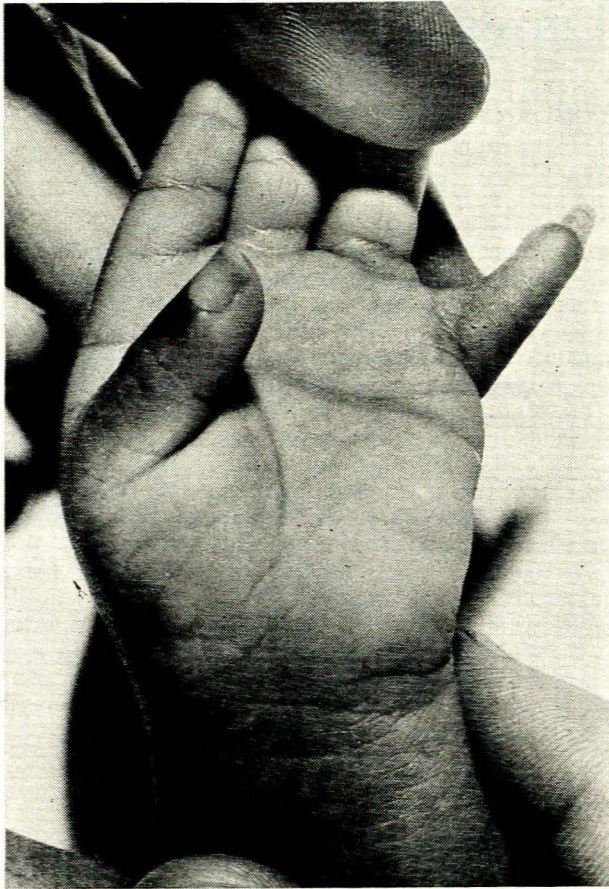


Fig. 2. Left hand demonstrating simian creases, clinodactyly of the fifth finger, only one flexion crease of the fifth finger and proximally implanted thumb.

Case 2

A Black female patient was delivered in hospital by Caesarean section after a full-term pregnancy. The mother had 3 normal children, all delivered by Caesarean section, owing to pelvic disproportion. Both parents were young and phenotypically normal. There was no family history of mental retardation or congenital abnormalities. The parents were not related and there was no exposure to irradiation or drugs during pregnancy.

The patient's birth weight was 1 900 g, skull circumference 29,5 cm, and body length 46 cm. The scalp hair was long, extending into the forehead and neck. The following features were also noticed: eyebrows bushy and confluent with ptosis, nasal bridge depressed with nostrils anteverted, the lips thin and down-curved at the angles of the mouth (Fig. 3). The chest had a minimal pectus excavatum and the areolae were widely spaced. There was micromelia of both upper extremities, the elbows fixed in flexion could not be extended owing to webbing of the skin of the cubital fossa. The left forearm, terminating in a single digit, was shorter than the right forearm, terminating in two digits. The patient's cry was low-pitched. A grade

3/6 systolic murmur was audible along the left sternal border and a small umbilical hernia was present. Routine laboratory studies, electrocardiography and chromosomal analysis did not reveal any abnormalities. The patient thrived poorly, with frequent episodes of vomiting and pneumonia. She died later of an attack of severe gastroenteritis. Permission for a postmortem examination was refused.

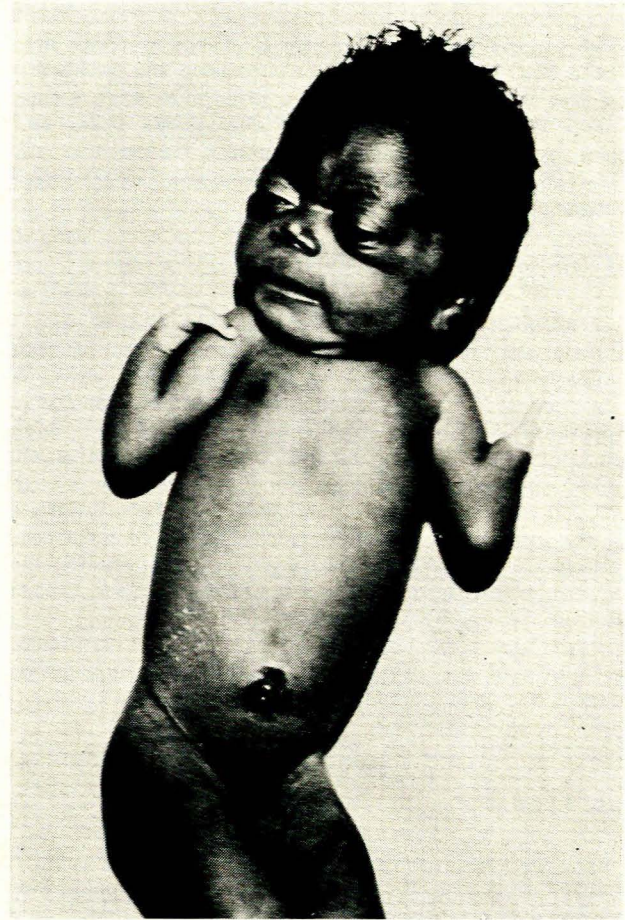

Fig. 3. Bushy eyebrows and synophrys, ptosis, small nose with anteverted nostrils, thin lips with downward curving at the mouth angles, micromelia of both upper extremities.

DISCUSSION

Unaware of Brachmann's 1916 report, Cornelia de Lange of the University of Amsterdam described 2 female cases in 1933 and called the syndrome *typus degenerativus Amstelodamensis*.¹ Opitz *et al.*² proposed the eponym Brachmann-De Lange syndrome and stressed the strikingly similar facial appearance of these patients, due to the antimongoloid slant of the eyes, ptosis, bushy confluent eyebrows (synophrys) and long curly eyelashes. Other features are a brachycephalic or microcephalic skull, low forehead covered with fine lanugo, small, upturned nose with

anteverted nostrils and depressed bridge, and the distance between the upper lip and the nose is increased. The scalp hair extends low in the nape of the neck and the forearms and back display marked hirsutism. The thin lips curve downwards at the angles of the mouth; the mandible is small, frequently with a midline spur. The ears are often low-set and the neck short. The low-pitched, weak cry (growling) is characteristic in all cases. The teeth may be normal or small and peg-like, eruption usually delayed, and there may be overcrowding. The skeletal abnormalities include micromelia, phocomelia, oligodactyly, proximally placed thumbs, short, tapered fingers, flexion contractures of the elbows, and short toes with syndactylism of the second and third toes. Congenital heart lesions have frequently been reported, the most common being a ventricular septal defect. Additional features include extreme hirsutism, cutis marmorata, hypoplastic nipples, deficient epidermal ridges and a simian line in the palms. In males, the testes may fail to descend and hypospadias be present. The intellectual performance

is usually limited. The pregnancies are of normal duration although in many cases fetal movements are described as feeble. The patient's birth weight is low, and both height and weight values are well below the 3rd percentile.

Confusion exists about the genetics of the Brachmann-De Lange syndrome. The inheritance has been described as autosomal dominant, autosomal recessive or multifactorial. The aetiology remains undetermined⁴ and consanguinity has been mentioned. Excessive parental age does not appear to play a role and the majority of patients appear to have normal chromosomal number and morphology.¹

REFERENCES

1. McArthur, R. G. and Edwards, J. H. (1967): *Canad. Med. Assoc. J.*, **96**, 1185.
2. Opitz, J. M. in Gellis, S. S., ed. (1971): *Year Book of Pediatrics*, p. 489. Chicago: Year Book Medical Publishers.
3. Opitz, J. M., Segal, A. T., Lehrke, R. L. and Nadler, H. L. (1965): *Birth Defects*, **12**, 22.
4. Lieber, E., Glaser, J. H. and Thaveri, R. (1973): *Amer. J. Dis. Child.*, **125**, 717.


Blokiesraaisel Nr. 14

DWARS

- 4. Geestesversteuring se opsig. (7)
- 8. Gesigskerptegeelykheid. (6)
- 9. Vroue-eiegeslagontugtig. (7)
- 10. As volitantes dan sweefvlieënsien. (6)
- 11. Soms -kop gewoonlik met oog. (6)
- 12. Vinnige umbilikale verettering? (8)
- 18. Hersenskimme. (8)
- 20. Horingvliesbevatng. (6)
- 21. Râle stel teleur. (6)
- 22. Vrugdraend en aansluitend reseptief. (7)
- 23. Hulle lê streng selfdissipline aan die dag. (6)
- 24. As dit behoort ons een die ander te beskou. (7)

AF

- 1. Kleurstof meng pit. (7)
- 2. Die braaier se tydtafel? (7)
- 3. Uiteindelik ter afsluiting. (6)
- 5. Klink na opdrag maar is 'n medikament. (8)
- 6. Voortgebring soos alle soogdiere. (6)
- 7. Raamwerk van been. (6)
- 13. Agterrandmiddelpunt. (8)
- 14. Swawelbevattend soms in blaas versteen. (7)
- 15. Wegneem uit omgewing. (7)
- 16. 'n Oplossing vir kinders. (6)
- 17. Klinkend plek baie ver maak. (6)
- 19. U eer as ureum-afbreker. (6)



Solution Crossword No. 13

Across: 1, Heterocyclic; 7, Pentosuria; 9, Reils band; 10, Ale; 11, Croton; 12, Enter; 13, Drinking; 15, Step; 17, Italian; 19, Be; 21, Concentrate.

Down: 1, Hyperacidity; 2, Tendinosis; 3, Rootstock; 4, Crural; 5, Children; 6, Interrupted; 8, Lactate; 14, Nylon; 16, Pair; 18, Tic; 20, It.