

# Radiology of Acute Toxic Megacolon

L. WERBELOFF, B. NOVIS, S. BANK, I. N. MARKS

## SUMMARY

A case is described in which the transition from acute idiopathic ulcerative colitis to acute toxic megacolon was followed radiologically, and the features which indicate the development of this dangerous complication are identified.

*S. Afr. Med. J.*, 48, 912 (1974).

## CASE REPORT

A 70-year-old White male was admitted on 28 February 1973, having complained for some weeks of severe intractable diarrhoea, as well as the passage of some blood, but no mucus, for a few days. He was diabetic, and had had a previous myocardial infarct and a gastric ulcer. A week earlier his haemoglobin was 13,5 g/100 ml, packed cell volume 45%, mean corpuscular haemoglobin concentration 30%, platelets were adequate, and white cells 9 000/mm<sup>3</sup> with 77% polymorphs and 21% lymphocytes. Stool cultures had shown neither salmonella nor shigella organisms.

On admission he was pyrexial, 38°C, with pulse 92/min and blood pressure 120/70 mmHg; jugular venous pressure normal; haemoglobin 11,5 g/100 ml, erythrocyte sedimentation rate 65 mm/hour; blood sugar 272 mg/100 ml; urine clear. He was mentally confused and the diarrhoea was still present. The abdomen was distended and hyper-resonant; no tenderness or rigidity was present, nor was any mass palpable. The stool was positive for occult blood. Proctoscopy showed superficial ulceration and a diffuse polypoid appearance; no amoebae were found in a scrape specimen.

A barium enema performed on 13 February 1973 showed total ulcerative colitis, shortening of the left colon, almost total absence of haustration and a backwash ileitis. Colonic measurements (without air insufflation) were ascending 4,0 cm, transverse 4,2 cm and descending 6,0 cm in diameter.

On admission plain X-ray films of the abdomen showed severe dilatation of the whole colon, the ascending colon measuring 8,5 cm, transverse colon 10,5 cm, and descending colon 10,0 cm. The walls were much thickened and pseudopolypi present. Some small bowel distension was also present, as well as a pneumoperitoneum.

Department of Radiology and Gastro-Intestinal Clinic, Grootte Schuur Hospital, Cape Town

L. WERBELOFF, M.B. CH.B., D.M.R.E.

B. NOVIS, M.B. CH.B., M.R.C.P.

S. BANK, M.B. CH.B., F.R.C.P.

I. N. MARKS, B.Sc., M.B. CH.B., F.R.C.P.

Paper presented at the 49th South African Medical Congress (MASA), held in Cape Town on 23-27 July 1973.

As his general condition deteriorated rapidly, a laparotomy was done. This confirmed the presence of a very dilated colon and showed a small perforation in the upper descending colon. The peritoneal cavity was not soiled. A total colectomy was done.

The surgical specimen showed extensive ulceration. Multiple areas of polypoid mucosal sequestration with mucosal bridging and subserosal fibrosis were seen in areas where the submucosa was involved.

Two days later bleeding occurred from the ileostomy. The abdomen was reopened and it was confirmed that the haemorrhage was coming from the gastric ulcer. A Bilioth I partial gastrectomy was done. His subsequent progress was poor and he died on the 22nd day after admission.

## DISCUSSION

Toxic dilatation of the colon is a condition with a high morbidity and mortality. As the name implies, there are marked dilatation of the colon and features of toxicity. Usually the abdomen is distended and diffusely tender, with decreased or absent peristalsis.

This condition is usually found complicating idiopathic ulcerative colitis or amoebic colitis, and more recently, Crohn's disease and ischaemic necrosis of the colon. Very rarely it may occur during the violent toxic phase of typhoid fever, cholera and acute dysentery. Other causes of megacolon, such as idiopathic megacolon, colonic obstruction and Hirschsprung's disease, do not fall within the definition of acute toxic megacolon.

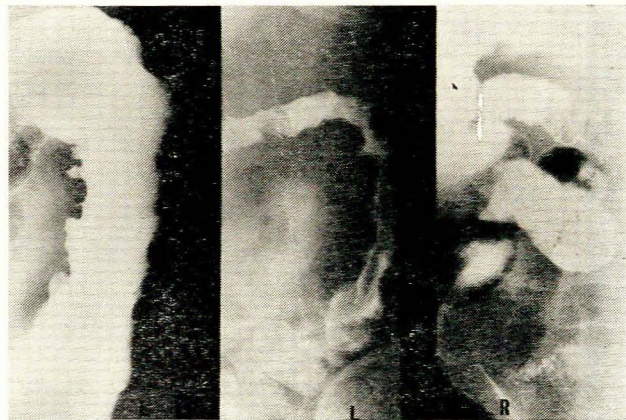


Fig. 1: 13 February 1973. Ulcerated colon, shortening, absence of haustration and backwash ileitis.

Meteorism and dilatation of the toxic megacolon type are different entities, and the diameter of the colon in

the latter is only one important feature. The basic destruction or impairment of the muscular coats is the essence of this condition, but there are also submucosal oedema, deep ulceration, destruction of Auerbach's plexus and involvement of the serous coat.<sup>1,2</sup>

The degree of dilatation is of great importance. Measurements of the ascending, transverse and descending colon of 30 adults having routine barium enemas, were made with the patient supine and with the colon insufflated. This was done initially with the patient erect to facilitate siphoning off of the barium, and insufflation was done under screen control. When tolerable distension of the colon had been achieved, the patient was tilted supine again. The ascending colon was measured at the level of the 4th lumbar vertebra, the transverse colon in the midline and the descending colon at the level of the left iliac crest, in a film taken in the postero-anterior direction. The measurements are shown in Table I and are compared with those of Jones and Chapman<sup>3</sup> under similar conditions.

TABLE I. DIAMETERS (in cm) OF NORMAL COLON (INSUFFLATED)

	Average	Range	SD
Ascending colon	6,3	3,5 - 8,4	± 1,2
Jones and Chapman <sup>3</sup>	6,0	4,0 - 8,0	± 1,5
Transverse colon	5,4	2,0 - 8,0	± 0,9
Jones and Chapman <sup>3</sup>	4,9	3,5 - 8,0	± 0,8
Descending colon	3,7	2,9 - 4,7	± 0,9
Jones and Chapman <sup>3</sup>	3,5	2,0 - 5,0	± 1,7

In the normal colon the ascending portion is usually the widest and the descending colon the narrowest. Dilatation of the transverse colon in excess of 6,5 cm in the plain X-ray film is required for the diagnosis, but it seems as if the average case presents a diameter in the plain films of 8,0 cm or more.

In ulcerative colitis toxic megacolon usually occurs during the acute fulminating attack, and where most of the colon is diseased. This may be with the first attack (42%), during a relapse of established and known ulcerative colitis, or even in the chronic continuous type of disease. A small number are relapses after a previous fulminating attack. In our experience, the incidence is 25% of fulminating ulcerative colitis cases, and only between 4% and 5% of all degrees of ulcerative colitis.

In Crohn's disease the recognition of toxic dilatation is recent and the incidence quoted as 16% of cases.<sup>4</sup> It has been noted as early as 7 months after the onset of the disease but more usually within 4 years of onset.<sup>5</sup> Two cases are reported where toxic dilatation was confined to the ileum without associated colonic dilatation.<sup>6</sup>

A plain film of the abdomen is usually all that is needed for the X-ray diagnosis.<sup>7</sup> The transverse colon is mostly affected, probably because it is the most mobile portion and always uppermost in both supine and erect postures.<sup>8</sup> The ascending colon is the next most common site. Where the disease is limited to the rectum or rectosigmoid, toxic megacolon is not to be expected. A further finding in the plain film may be a cobblestone appearance of

the gas-filled colon, which is produced by pseudopolypi as a result of oedema of the bowel wall. These pseudopolypi occur alongside ulcers in the mucosa. The wall appears thicker than normal and this is best identified as the increased width of soft tissue between the gas-filled lumina of adjacent coils of bowel. Some haustration in the dilated areas is not unusual, which is unexpected in areas of acute colitis. In a few cases small bowel distension of a degree that can be confused with obstruction is seen. Ascites is seen occasionally and perforation with pneumoperitoneum has been noted. Distal obstruction has not been found.

The duration of the dilatation varies from 5 to 60 days, averaging 12,7 days, and subsidence can be abrupt or slow.<sup>9</sup>

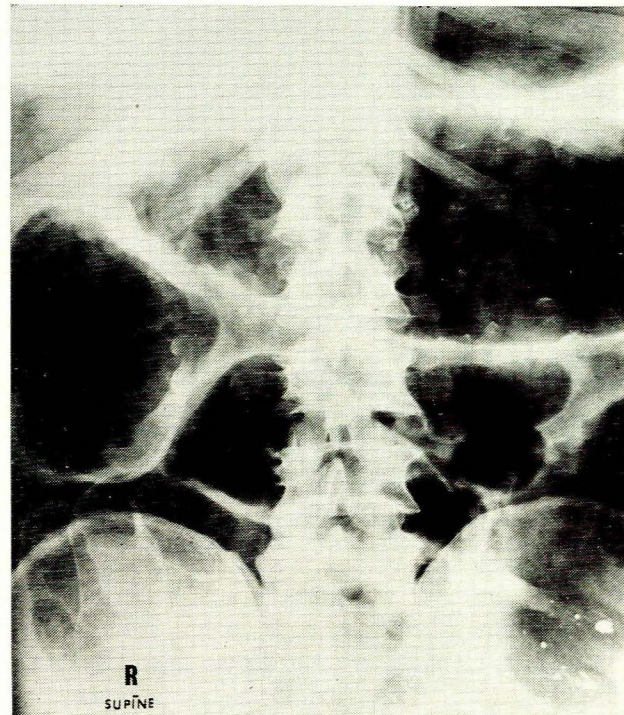
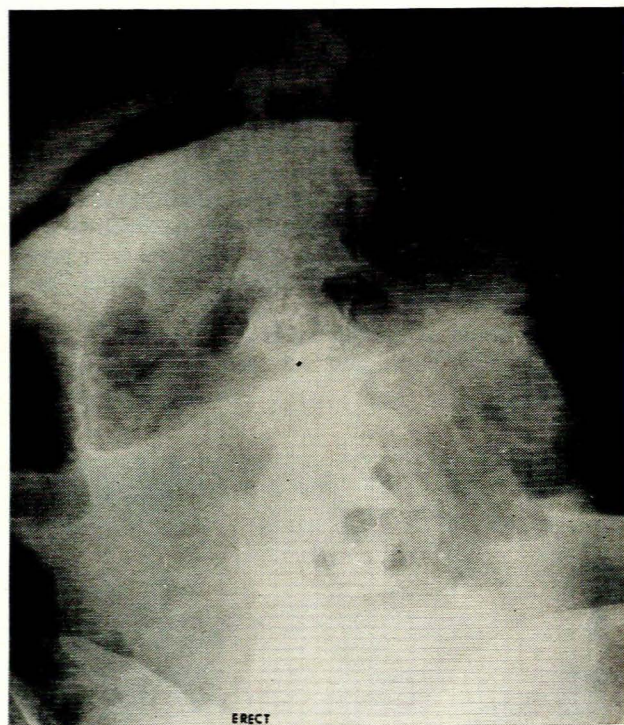


Fig. 2. 28 February 1973. Dilated colon with very thick walls and pseudopolypi coated with barium from the first examination of 13 February 1973.

A thin translucent stripe in the bowel wall represents gas in the subserosa.<sup>10,11</sup> Evidence of this has so far been noted only in cases of toxic megacolon due to amoebic colitis. No case of gas in the portal venous circulation has been reported, possibly because the course of the disease is too rapid.

Barium enema findings before colonic dilatation usually show the features of the causative disease. Preparation of the colon for barium enema requires that the use of purgatives and drastic colon lavage be avoided. Withholding food (including liquid) with too much residue for 24 hours is all that is needed while the patient has diarrhoea. In some cases, however, a barium enema is



**Fig. 3. 1 March 1973. Pneumoperitoneum has appeared.**

given unknowingly in a stage of marked colonic dilatation during an acute phase of ulcerative colitis. This may result in greater colonic dilatation and the patient's clinical condition may deteriorate. Some suggest that the barium enema can precipitate colonic dilatation because the intraluminal pressure is enough to retard the flow of blood in a diseased colon. Narcotics, anticholinergics and hypo-

kalaemia are considered as other precipitating factors. A pneumoperitoneum may also be present.

Surgical specimens obtained in the phase of toxic megacolon show extensive ulceration, usually of large areas of bowel. Even 50% of the mucosal surface can be replaced by granulation tissue. In these areas the bowel wall is friable and may not exceed 2-3 mm in thickness, and the pericolic fat is oedematous. Pseudopolypi are likely to be present. The histology in this phase reveals the important factor of transmural inflammation with muscle destruction and serosal inflammation. The latter is not a feature of ulcerative colitis itself. The myenteric and Auerbach's plexuses may be involved, and this is possibly a causative factor of toxic megacolon. Perforation, either intra- or extraperitoneally, is sometimes present.

The disease has a high mortality even with intensive initial care, and the absence of improvement and deterioration certainly justify colectomy. Daily X-ray film examinations of the abdomen, without contrast media, are valuable, since progressive dilatation and pneumoperitoneum are significant in the prognosis.

We should like to thank Dr J. Heselson, under whose care the patient was admitted, and Mrs R. S. Henderson who kindly prepared the illustrations.

#### REFERENCES

1. Norland, C. C. and Kirsner, J. B. (1969): *Medicine (Baltimore)*, **48**, 229.
2. McInerney, G. T., Sauer, W. G., Baggenstoss, A. H. and Hodgson, J. R. (1962): *Gastroenterology*, **42**, 244.
3. Jones, J. H. and Chapman, M. (1969): *Gut*, **10**, 562.
4. Hawk, W. A. and Turnbull, R. B. (1966): *Ibid.*, **51**, 802.
5. Papp, J. P. and Pollard, H. M. (1970): *Amer. J. Dig. Dis.*, **15**, 1105.
6. Greene, L., Kresch, L. and Held, B. (1972): *Ibid.*, **17**, 439.
7. Annotation (1973): *Lancet*, **2**, 192.
8. Marshak, R. H., Korelitz, B. T., Klein, S. H., Wolf, B. S. and Janowitz, H. D. (1960): *Gastroenterology*, **38**, 165.
9. Roth, J. L. A., Valdes-Dapena, A., Stein, G. N. and Bockus, H. L. (1959): *Ibid.*, **37**, 239.
10. Simon, M., Shapiro, J. H., Parker, J. G., Schein, C. J. and Weingarten, B. (1962): *Ibid.*, **87**, 655.
11. Faegenburg, D., Chiat, H., Mandel, P. R. and Ross, S. T. (1967): *Amer. J. Roentgenol.*, **99**, 74.