

# Communication between Paranasal Sinuses and Meninges after Trauma

## A RADIOLOGICAL EXERCISE USING SPIRAL TOMOGRAPHY

N. L. HURST

### SUMMARY

Two cases are presented, both demonstrating the value of the painstaking use of pleuridirectional spiral tomography to map out the exact situation and extent of defects where a communication exists between the paranasal sinuses and the meninges.

*S. Afr. Med. J.*, **48**, 909 (1974).

### CASE REPORTS

#### Case 1

A middle-aged White woman presented with continuous right-sided frontal headache after a head injury a few weeks previously.

---

X-ray Department, Garden City Clinic, Johannesburg

N. L. HURST, D.M.R.D., M.MED. (RAD.D.)

---

Date received: 19 November 1973.

A routine X-ray examination of the skull demonstrated a hairline fracture in the frontal region, difficult to localise to a particular side. In addition there was intracranial air in the frontal area (Fig. 1).

Spiral tomographic views were done using large angle (thin cut) and small angle (thick cut) sections. These were done in the anteroposterior, lateral and half-axial projections, until a thin linear fracture in the right frontal region passing along the floor of the anterior fossa into a small frontal sinus air cell was established. This air cell was situated in relation to the lateral aspect of the right frontal sinus air cells (Fig. 2).

At operation we pointed out to the neurosurgeon that the fracture was situated at a point approximately 3 cm lateral and 2 cm anterior to the right anterior clinoid process.

#### Case 2

An Indian woman in her early thirties presented with severe cerebrospinal fluid rhinorrhoea from her left nostril.

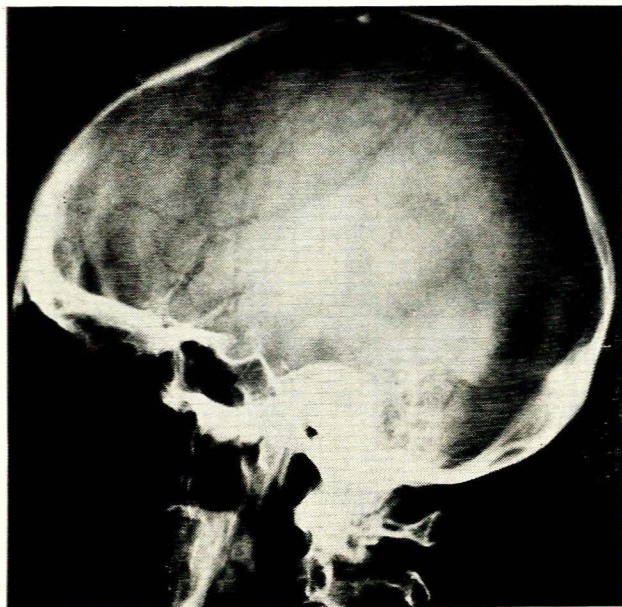


Fig. 1. Hairline fracture in the frontal region, extending from above downwards and associated with a blob of intracranial air which appears to be lying in apposition to the floor of the anterior fossa.

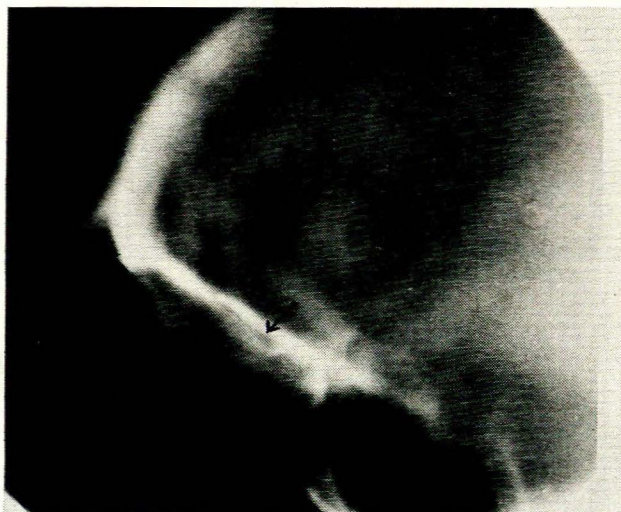

Fig. 2. A broad-cut spiral tomograph demonstrating the linear fracture passing from the anterolateral wall in the frontal region downwards and coursing along the floor of the anterior fossa into a small frontal sinus air cell (indicated with an arrow).

after surgical drainage of her left sphenoid sinus 2 years previously.

On routine X-ray examination of her skull there appeared to be a large polyp in the left sphenoid sinus. Basal spiral tomography demonstrated a well-defined polypoidal tumour with some irregularity of the posterolateral wall of this sinus (Fig. 3).

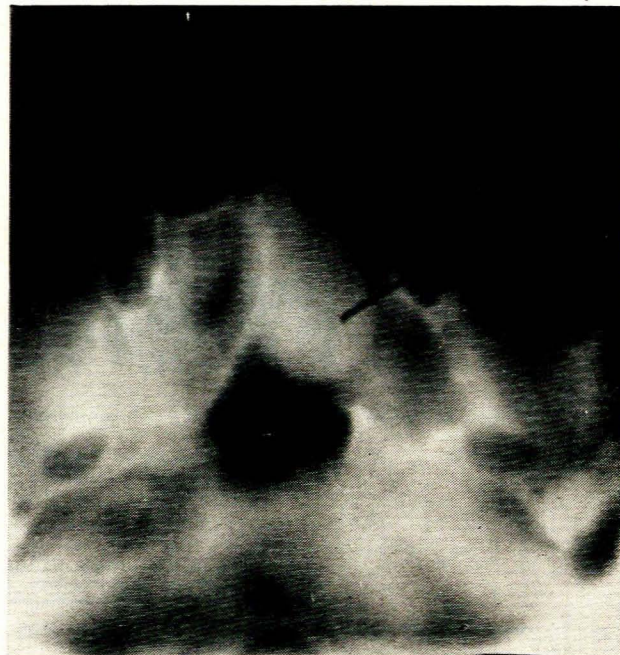


Fig. 3. A polypoidal tumour in the left sphenoid sinus is demonstrated on this basal tomograph. Note also the slight irregularity and erosion of bone on the lateral and posterior aspect of the left sphenoid sinus; also that the left sphenoid sinus is much larger than the right one. It seems likely that this tumour undergoes a variation in size at times which would account for the erosive changes.

Spiral tomography in the frontal projection demonstrated a large defect in the roof of the left sphenoid sinus with the polypoidal tumour herniating downwards from the intracranial area through this defect (Fig. 4).

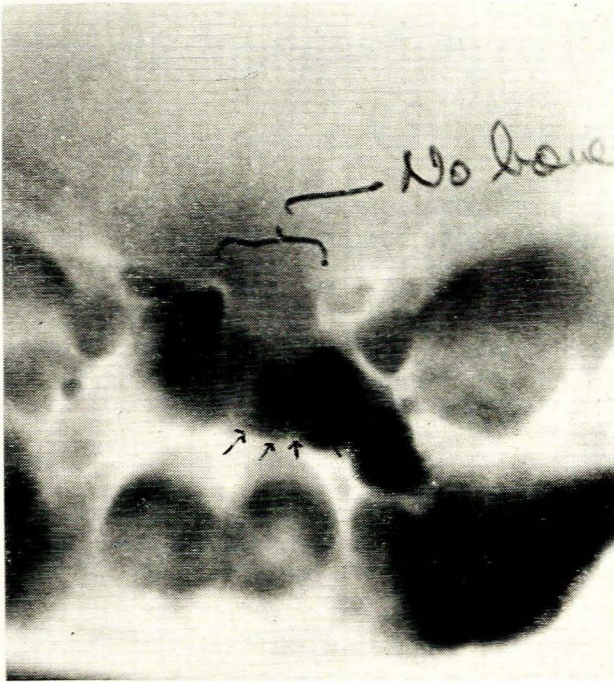
From our various tomographic cuts we could establish the following limits of the defect: (a) up to the level of the optic canal laterally; (b) just across the midline medially, limited by the septum between left and right sphenoid sinuses; (c) up to the level of the anterior clinoid processes posteriorly; and (d) that it was mainly the planum sphenoidale which was involved since there was no abnormality in the posterior ethmoid sinuses.

In this case we used large-angle (thin cut) tomography, 1 mm apart, which was a further guide to the exact localisation of the defect. Once again the exact limits as described above were confirmed at operation when a meningeal sac containing cerebrospinal fluid and brain tissue was found.

## DISCUSSION

Fractures involving the frontal sinuses and leading to 'pneumocephalus' have been described previously.<sup>1-4</sup> In most cases the fractures have been much more extensive and more easily visible on routine views and ordinary linear tomography.

We use the CGR Stratomatic tomographic apparatus, which is completely automated and versatile, so that we



**Fig. 4.** The roof of the left sphenoid sinus is absent. There is also some encroachment on the optic canal on the left side and the polypoidal tumour can be seen projecting downwards into the cavity of the left sphenoid sinus (indicated with arrows).

can easily vary depth of cut and cut-thickness to suit the particular need. We prefer spiral tomography in cases where fine delineation of the defect or other pathology is required.

'Pneumocephalus' takes from 10 days to 3 weeks after the occurrence of the fracture to become radiologically visible, since initially there is haematoma formation which prevents air from entering the cranium.<sup>4</sup> Penetrating injuries of the skull may lead to the introduction of gas-forming organisms which lead to the presence of intracranial gas or an aerocele, which is basically an abscess. Patients suffering from orbito-ethmoidal osteomas with intracranial complications may also present with 'pneumocephalus'.

Patients with spontaneous cerebrospinal fluid rhinorrhoea have also been described,<sup>5</sup> suffering from severe long-standing or intermittent hydrocephalus with pressure exerted on the cribriform plate by the anterior horns of the lateral ventricles. In most of these cases there was obstruction of the third ventricle.

Tumours in or near the pituitary fossa, such as pituitary adenomas or meningiomata, may bulge into the sphenoid sinus and produce a similar appearance as in our case 2.<sup>6</sup> The main radiological difference is that in tumours the surrounding bone shows hyperostosis and that the defect in the bone is not so clear-cut. The patient's clinical picture will obviously also be different.

I wish to thank Dr R. Plotkin for permission to publish reports of his cases.

#### REFERENCES

1. Samuel, E. (1952): *Clinical Radiology of Ear, Nose and Throat*. London: H. K. Lewis.
2. British Authors (1969): *Textbook of X-Ray Diagnosis*, vol. I, pp. 146, 151 and 153. London: H. K. Lewis.
3. Du Boulay, G. H. (1965): *Principles of X-Ray Diagnosis of the Skull*, pp. 315 - 319. London: Butterworths.
4. Taveras, J. M. and Wood, E. H. (1964): *Diagnostic Neuroradiology*, pp. 769 - 770. Baltimore: Williams & Wilkins.
5. Schechter, M. M. (1969): *Brit. J. Radiol.*, **42**, 619.
6. Gifford, R. D., Goree, J. A. and Jimenez, J. P. (1971): *Amer. J. Roentgenol.*, **112**, 324.