

# X-Linked Deafness in a South African Kindred

P. THORPE, S. SELLARS, P. BEIGHTON

## SUMMARY

The X-linked deafness of Nance is present in a South African kindred. Recognition of the familial pattern of the disorder, together with the characteristic clinical and audiometric features, permits diagnostic precision, thereby facilitating accurate genetic counselling and rational management. Linkage studies indicated that the loci for the Xg blood group and the deafness gene are unlikely to be very close to each other.

*S. Afr. Med. J.*, 48, 587 (1974).

More than 70 forms of congenital deafness have been recognised.<sup>1</sup> Of these, the majority are inherited autosomal recessive or autosomal dominant traits. However, Nance *et al.*<sup>2</sup> have recently delineated a condition of X-linked mixed deafness which is characterised by congenital fixation of the stapedial foot-plate and profuse perilymphatic otorrhoea on attempted stapedectomy.

This article concerns a South African White family in which the X-linked deafness of Nance has passed through 5 generations and affected 8 males. Xg blood group studies indicate that the respective genes are unlikely to be closely linked in this kindred.

## PATIENTS AND METHODS

### Case Reports

**Patient 1:** The propositus (V-1), a 24-year-old student, was born after a full-term, uneventful pregnancy and a normal delivery. His birth mass was 3 kg and no abnormality was apparent. There had been no known maternal rubella or exposure to potential mutagenic agents.

At the age of 2½ years he was found to have bilateral deafness. He had had no preceding otitis media or exposure to undue noise. Since that time there has been neither progression nor remission, and no vertigo, tinnitus or other paraphenomena. Hearing aids of various types have been used in the right ear since the age of 7. These have been of considerable benefit, comprehension and speech being virtually normal. Apart from the deafness, general health has always been good.

Medical School, University of Stellenbosch  
P. THORPE, *Medical Student*

Department of Otolaryngology, University of Cape Town  
S. SELLARS, M.A., F.R.C.S., F.C.S. (S.A.), *Senior Lecturer*

Department of Human Genetics, University of Cape Town  
P. BEIGHTON, M.D., M.R.C.P., D.C.H., *Professor of Human Genetics*

Date received: 5 September 1973.

A left tympanotomy, performed as a diagnostic procedure in 1971, demonstrated fixation of the stapedial foot-plate. Upon mobilisation, perilymph gushed into the middle ear. The ear was packed and the operation abandoned. Audiometry performed before and after this procedure showed no change in the severe mixed hearing loss which was present in both ears.

### PURE TONE AUDIOGRAM

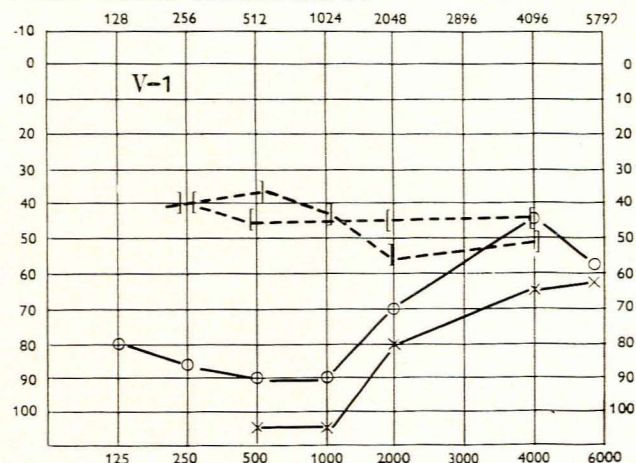


Fig. 1. Pure tone audiogram of the propositus showing marked bilateral conductive and perceptible deafness, worse in the frequencies 500 and 1 000 cps. There is near closure of the air-bone gap at 4 000 (and 8 000) cps. Air conduction: right o, left x; bone conduction: right [ , left ].

### PURE TONE AUDIOGRAM

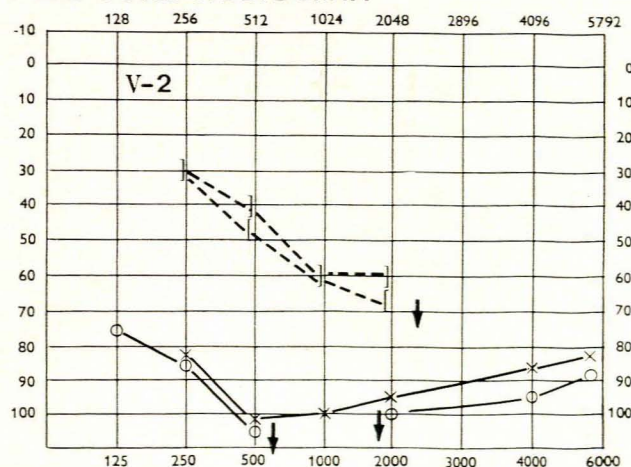


Fig. 2. Pure tone audiogram of the brother of the propositus showing bilateral conductive and perceptible deafness, worse at 500, 1 000 and 2 000 cps.

Clinical examination in 1973 revealed a healthy, intelligent young man wearing a transistor hearing aid in his right ear. He was 1,83 m in height, mass 61 kg, with normal bodily proportions. The external ears, auditory canals and tympanic membranes were apparently normal, as were the facies, eyes, hair, skin and nails. No abnormality was detected in the nose, mouth, pharynx or neck. Reflexes were intact and nystagmus could not be elicited. The abdomen and cardiovascular, respiratory and musculo-skeletal systems were unremarkable.

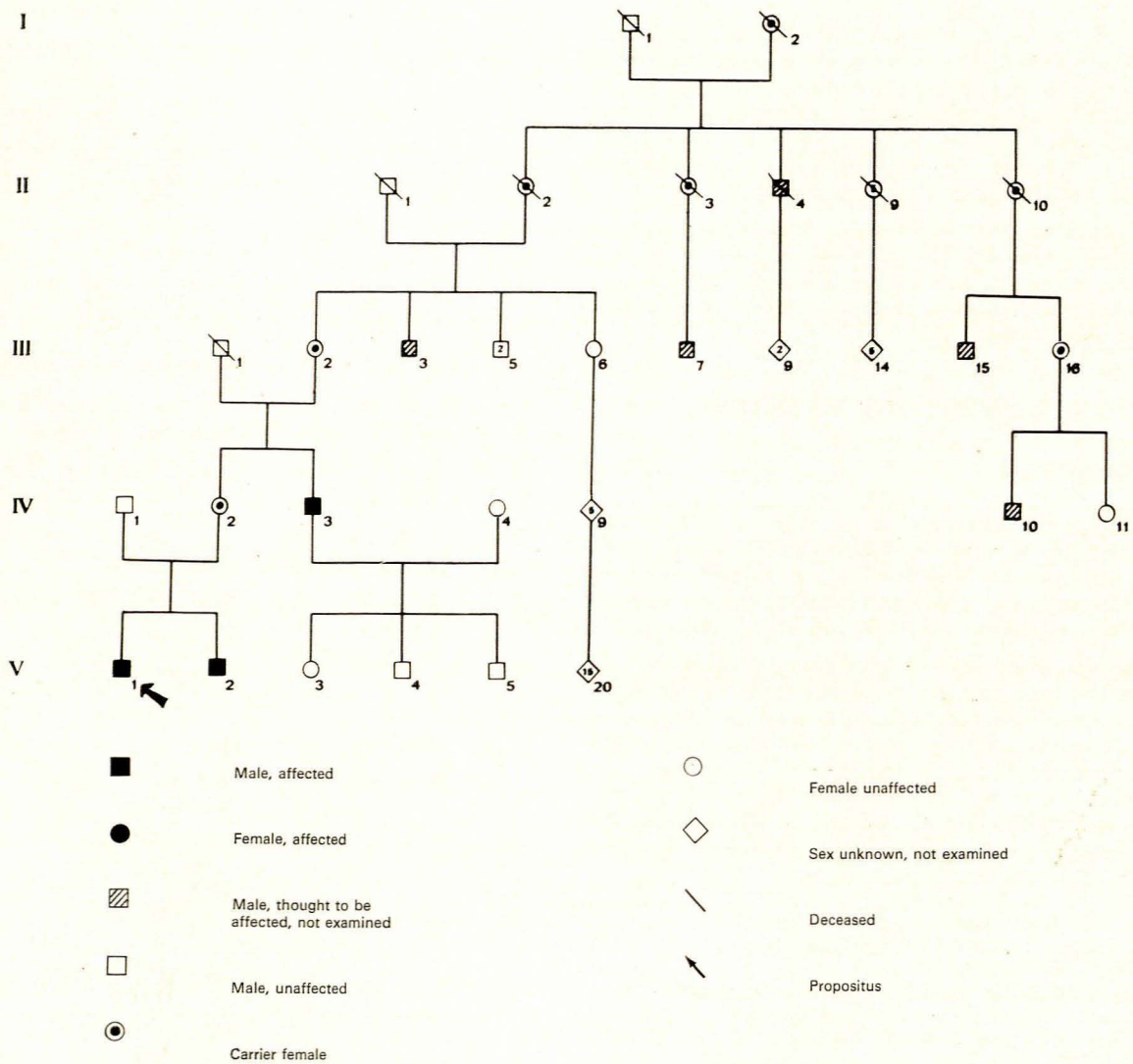
Pure tone audiometry revealed a mixed perceptive and conductive hearing loss which was equal in both ears but which showed a greater air-bone gap in the lower frequencies (Fig. 1).

His speech threshold was 80 decibels in the left and 68 decibels in the right ear, with maximal discrimination scores of 75% in the left and 95% in the right ear. There was no distortion threshold. Bekesy audiometry produced a type I tracing and his calorigram indicated a left directional preponderance, which was clinically inexplicable. There was no evidence of positional or spontaneous nystagmus.

Serum electrolyte levels were within normal limits. Neither albumin nor glucose was present in the urine. Skeletal survey revealed no bony abnormality. Cytogenetic studies demonstrated a normal karyotype.

**Patient 2:** The brother of the propositus (V-2) was born in 1954 after a normal pregnancy and delivery. Deafness

**X-LINKED DEAFNESS**



**Fig. 3. Pedigree of the kindred.**

was diagnosed at the age of 18 months and a transistor hearing aid was subsequently worn in the left ear. Otitis media has never occurred and, apart from operations on a pilonidal sinus in 1968 and 1969, his general health has been unimpaired.

At the time of clinical examination in 1973, he was a fit young man, 1,80 m in height and mass 66 kg. He had a moderate disturbance of comprehension and speech, but no other abnormalities were detected in any system. In particular, his external ears, hair, eyes, neck and nails were all normal.

Pure tone audiometry demonstrated severe mixed hearing loss, which was worse in the right ear. The pattern of his audiometry was identical with that of his brother (Fig. 2). His calorigram was essentially normal and there was no evidence of positional or spontaneous nystagmus. Determination of serum electrolytes, urine analyses, skeletal survey and cytogenetic studies all gave normal results.

## Family Study

Investigation of the family revealed that severe deafness had been recognised during infancy or childhood in a total of 8 males in 4 generations. Only males were affected and there was no male-to-male transmission of the gene (see pedigree, Fig. 3). This pattern is entirely consistent with X-linked inheritance.

Apart from the propositus and his brother (V-1 and V-2), other members of the kindred who were personally examined were IV-2, the mother of the affected brothers, their uncle (IV-3) and his own offspring (V-3, 4, 5), and the maternal grandmother (III-2). The uncle (IV-3) had also been deaf since childhood. His speech and comprehension were markedly impaired, but clinical examination was otherwise normal. His pure tone audiogram was similar to that of his nephews (Fig. 4).

## PURE TONE AUDIOGRAM

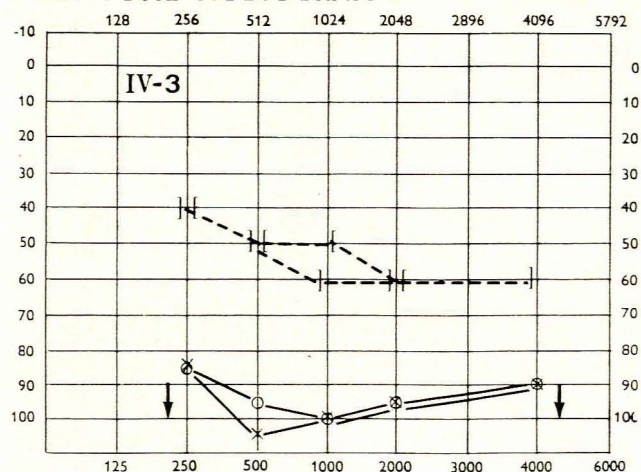


Fig. 4. Pure tone audiogram of the maternal uncle of the propositus showing similar marked bilateral mixed deafness, worse at 500, 1 000 and 2 000 cps. There is also less obvious narrowing of the air-bone gap at 4 000 cps.

The mother of the propositus (IV-2) was clinically normal and her audiogram was unremarkable. Her calorigram was also normal and there was no evidence of positional or spontaneous nystagmus. The maternal grandmother (III-2) was also clinically normal, but audiometry revealed a hearing loss in the higher frequencies which was consistent with simple age-related presbycusis.

The cousins of the propositus (V-3, 4, 5) were all clinically normal, and audiometric studies in patient V-3, a 16-year-old girl, were unremarkable. These individuals were all tested for protan and deutan colour blindness. All were normal.

No other family members were available for study as they were either deceased or living on other continents. However, a specialist's report on patient III-3 indicated that his case history, clinical features and audiometric stigmata were similar to those of his other affected relatives.

It is noteworthy that the two obligatory heterozygous females (IV-2 and II-2) and the potentially heterozygous girl (V-3) who were investigated, had neither clinical nor audiometric evidence of expression of the gene.

## Linkage Studies

Xg blood group investigations were undertaken by Dr Ruth Sanger of the Medical Research Institute Blood Group Unit at the Lister Institute, London.

Patients III-2, IV-3, IV-4 and V-3 were shown to be Xg(a+), while patients IV-1, IV-2, V-1, V-2, V-4 and V-5 were Xg(a-). These results indicate that the locus for the deafness gene is unlikely to be very close to the Xg locus, as there is at least one recombinant: IV-2 and IV-3 have received Xg and Xg<sup>a</sup> respectively from their mother, and each has also received the deafness gene. The Xg results of the other members of the kindred who were tested were uninformative.

As no member of the kindred was shown to be colour blind, no estimate could be made of any relationship with the protan and deutan colour blindness genes.

## DISCUSSION

The X-linked transmission of mixed deafness in association with congenital fixation of the stapedial foot-plate and increased perilymphatic pressure was recognised in a North American kindred by Nance *et al.*<sup>2</sup> Another affected kindred was mentioned by McKusick in 1971 when he cited a personal communication of Shine and Watson,<sup>3</sup> describing 9 affected males in 2 generations of a Chinese-American family.

The pattern of transmission of deafness in the kindred investigated by ourselves was indicative of X-linked inheritance. The clinical, audiometric and caloric findings were in close accord with those described by the previously-mentioned authors, and it is reasonable to conclude that these conditions are the same entity. In this respect, the consistent descriptions of 'perilymphatic gushing' during surgical interference with the stapes are particularly striking.

As the progenitors of both the South African kindred and Nance's North American family came from Britain, it is possible that they are directly related. The elucidation of this situation would constitute an interesting and valuable genealogical study.

Congenital perceptive deafness<sup>4</sup> and progressive deafness<sup>5</sup> may also be X-linked. However, clinical features, pattern of progression and audiometric findings allow differentiation from these disorders. Deafness is also a feature of a few other X-linked disorders, but in all of them recognition of multisystemic involvement permits diagnostic precision.<sup>4</sup>

Although Nance *et al.*<sup>2</sup> were able to demonstrate minor audiometric abnormalities in heterozygous females, no changes could be detected in the carriers in the South African kindred. The recognition of the asymptomatic carrier female therefore remains an unresolved problem. Linkage studies are of potential value in this respect, but, as no close linkage could be demonstrated between the deafness and Xg blood group genes, these techniques are unhelpful at the present time.

In view of the X-linked transmission of the condition, affected males could receive the gene from a line of car-

rier females and therefore lack a positive family history. However, the diagnosis may be suspected on a basis of the characteristic clinical and audiometric features. Diagnostic precision is of paramount importance, as appreciation of the X-linked nature of the condition permits accurate genetic counselling and avoidance of the potentially dangerous sequelae of stapedectomy.

We should like to thank Dr Ruth Sanger of the Medical Research Council Blood Group Unit; the Lister Institute, London, for the linkage studies; and Dr C. J. du Toit of Tygerberg Hospital, for the details of the operation which he carried out on the propositus.

This project was supported by a grant from the University of Cape Town Staff Research Fund.

#### REFERENCES

1. Konigsmarks, B. W. (1971): *Birth Defects: Original Article Series*, vol. 7, No. 4, pp 2 - 17. Baltimore: Williams & Wilkins.
2. Nance, W. E., Setleff, R., McLeod, A. C., Sweeney, A., Casper, M. C. and McConnell, F. (1971): *Op. cit.*<sup>1</sup>, pp. 64 - 69.
3. Shine, I. and Watson, J. R. (1967): cited by McKusick, V. A. (1971): *Mendelian Inheritance in Man*, 3rd ed., p. 558. Baltimore: Johns Hopkins.
4. Fraser, G. R. (1965): *Ann. Hum. Genet.*, **29**, 171.
5. Mohr, J. and Mageroy, K. (1960): *Acta Genet. Statist. Med.*, **10**, 54.