

Peritoneoscopy in Medical Cases

J. M. SPITAELS, M. G. MOSHAL

SUMMARY

Two hundred and fifty patients were subjected to peritoneoscopy. The Jacobs-Palmer peritoneoscope and the Lent photoperitoneoscope with distal flash were employed. Local anaesthesia was utilised throughout. Diagnostic analysis included 32 patients with tuberculosis (31 peritoneal, 1 hepatic); 39 patients with carcinoma (31 liver, 7 peritoneal, 1 ovarian); 56 patients with cirrhosis; 44 with various other liver conditions; 49 patients with non-specific peritoneal inflammation; and 9 patients with other conditions. Fourteen peritoneoscopies were normal and 7 were terminated for technical reasons. The clinical impression of a 'doughy abdomen' was confirmed in only 17 out of 27 patients. In a series of 25 patients with radiological suspicion of intestinal tuberculosis none had tuberculous peritonitis; in 1 patient, mesenteric lymph nodes were enlarged and chylous ascites was found, in another hepatic tuberculosis was seen, and non-specific peritoneal inflammation was observed in 8 patients. Only one perforation of the intestine occurred and this was effectively treated.

S. Afr. Med. J., 48, 531 (1974).

Peritoneoscopy is widely used in continental countries, but remains unpopular in South Africa and English-speaking countries as a diagnostic tool in medical problems. Quinlan¹ and Mayat² have recently reported their experience in South Africa, using peritoneoscopy in gynaecological conditions. In 1965, Heselson³ drew attention to the value of peritoneoscopy in various medical conditions, yet it was 1972 before the report of McQuaide⁴ followed, revealing the paucity that exists in the South African literature about the subject. We have analysed our experience of 250 peritoneoscopies in medical problems.

CLINICAL MATERIAL AND METHODS

Two hundred and fifty patients were subjected to peritoneoscopy: 217 were Blacks (128 male and 89 female), with mean age 42,0 years; 33 were Indian (14 male and 19 female), with mean age 46,5 years. Two hundred and fifteen patients were referred from medical wards and 35 from surgical wards. The period of study extended from May 1970 to June 1973.

On arrival in the theatre, the patient is sedated with

Gastro-intestinal Unit, University of Natal and King Edward VIII Hospital, Durban

J. M. SPITAELS, M.D.

M. G. MOSHAL, M.R.C.P.

Based on a paper presented at the 8th Biennial Scientific Congress of the Association of Physicians of South Africa (MASA), Durban, July 1973.

5-10 mg diazepam intravenously, the dose graded according to the degree of anxiety. The procedure is performed under local anaesthesia. Infiltration of skin and subcutaneous tissue is done by introducing 2% lignocaine and air into the abdominal cavity through a Verres needle inserted into the left iliac fossa. Control tests are made to check that the tip of the needle is in the peritoneal cavity prior to the insufflation. The intra-abdominal pressure is easily controlled by palpation alone.⁵ When the pressure is adequate, a long infiltration needle is employed to explore the site where the trocar is to be introduced and to ensure that the cavity is free for safe introduction. The trocar, with its sleeve, is then inserted approximately 3 cm below the umbilicus, slightly lateral to the midline; the trocar is withdrawn, ascitic fluid drained if in excess, and the Jacobs-Palmer peritoneoscope⁶ introduced through the trocar sleeve. This is a foroblique viewing instrument (Fig. 1). A systematic survey is undertaken for the presence or absence of ascites and peritoneal adhesions. A careful note is made of the liver (size, colour, nodularity, localised suspicious lesions) and the degree of vascularisation of the falciform ligament observed. The surfaces of the gall bladder and spleen are examined, as well as the contents of the pelvic cavity, and the presence of abdominal masses is reported. A liver biopsy can be performed under direct vision, with the Jacobs needle inserted through the peritoneoscope. This is an elongated and modified Menghini needle. A grasping-type biopsy forceps is employed for peritoneal lesions. All instruments are introduced away from the eye-piece, owing to the unique 'step-down' design. After examination and instrumentation the peritoneoscope is withdrawn and photographs taken through the Lent lateral-viewing photoperitoneoscope* equipped with a distal flash (Fig. 2). After the procedure, air is expressed from the abdominal cavity, by gentle pressure on the flanks, through the open valve of the trocar sleeve. Mattress or continuous sutures are employed to close the incision which is 3 cm wide. If a biopsy specimen was taken during the procedure, the patient is kept in bed for 24 hours with regular checks of blood pressure and pulse.

RESULTS

The results of peritoneoscopy in 250 patients are shown in Table I.

Tuberculous Peritonitis

This was encountered in 31 patients and 18 cases were proved by biopsy. The typical picture consists of adhesions, between bowel loops, between abdominal wall and bowel loops, or between liver and abdominal walls, and scattered

*Afrox Surgical & Hospital Equipment Ltd.




Fig. 1. Jacobs-Palmer peritoneoscope. The step-down design allows introduction of various instruments (biopsy forceps, liver biopsy needle) away from the eye-piece.

peritoneal nodules (Fig. 3, a). The macroscopic diagnosis of tuberculosis may be made confidently if both adhesions and nodules are present. Additional signs of tuberculosis include fibrin streaks on bowel loops (Fig. 3, b) and hepatic surfaces (a crust of fibrin along the liver edge), turbid ascites, retracted omentum, and a brick-red smooth liver. Adhesions alone (localised or diffuse) are called non-specific peritonitis or perihepatitis.

The tuberculous nodules were miliary (pinhead size) in 26 patients, variable in size in 3 patients and large in 2 patients. Tuberculous peritonitis was associated with cirrhosis in 5 patients. The liver was engulfed in adhesions

and could not be seen in 5 other patients. Thirty peritoneal biopsies were performed, of which 18 provided histological evidence of tuberculosis, granulation tissue and caseation (17 patients) or acid-fast bacilli, or both (2 patients). Only 12 showed a non-specific inflammatory reaction.

Peritoneal Carcinomatosis (Table II)

Peritoneal carcinomatosis was seen in 7 patients. Confluent nodules, sometimes cauliflower-like, were spread on the peritoneal surfaces. The degree of fibrinous reaction was minimal, contrasting with that of tuberculous peritonitis. Histological proof was obtained from peritoneal biopsies in all but 1 patient.

TABLE I. ANALYSIS OF 250 MEDICAL CASES IN WHICH PERITONEOSCOPY WAS PERFORMED

	Macro- scopical diagnosis (No.)	Histological proof (No.)	%
Tuberculosis			
Peritoneal	31	18	58,1
Hepatic	1	1	100,0
Carcinoma			
Hepatic	31	16	51,6
Peritoneal	7	6	85,7
Ovarian	1		
Cirrhosis of the liver	56	12	21,4
Various liver conditions	26		
Cholestasis	18		
Non-specific peritonitis	49		
Other conditions	9		
Suspected retroperitoneal pathology (7)			
Ovarian cyst (1)			
Pregnancy (1)			
Normal	14		
Terminated procedures	7		
	—		
Total	250		

TABLE II. PERITONEAL CARCINOMATOSIS

Macroscopical diagnosis	Histology
Ovarian	Carcinoma, probably ovarian
Gastric	Mucus-secreting carcinoma
Carcinomatosis	Lymphocytic (minute piece) infiltration
Hepatic	Adenocarcinoma
Sigmoid colon	Carcinoma, probably papillary cystadenocarcinoma of ovary
Carcinomatosis	Undifferentiated
Tuberculosis, carcinoma not excluded	Adenocarcinoma, probably ovarian

Liver Carcinoma

The macroscopic diagnosis of hepatic carcinoma was made in 31 patients. Confirmation on biopsy was obtained in 16 patients (9 primary, 4 secondary and 3 undifferentiated). A liver biopsy could not be done in 6 patients because of uncorrected bleeding diathesis or heavy vascularisation of the tumour. In 9 further biopsies an insuf-

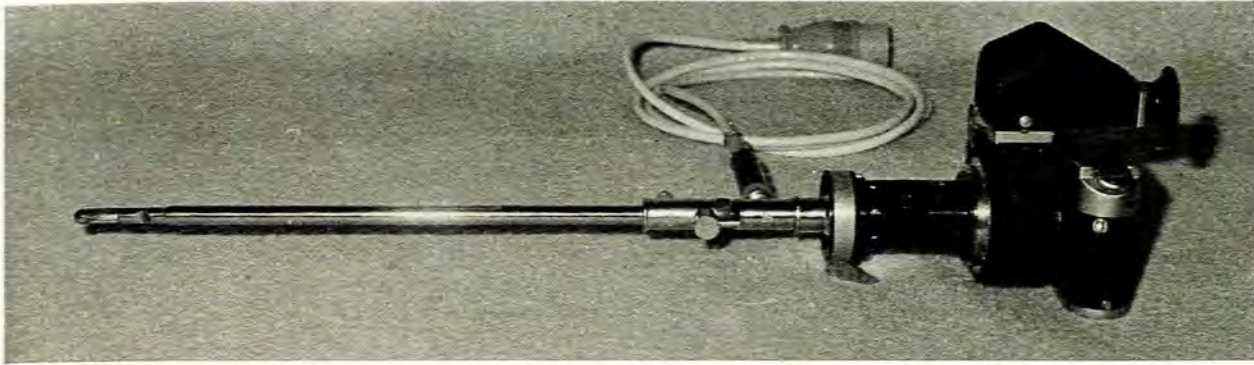


Fig. 2. Lent lateral-viewing photoperitoneoscope fixed to a Leitz camera. The flash-bulb can be seen at the end of the instrument.

ficient specimen did not contain malignant cells. The secondary carcinomatous lesions were well demarcated from the liver tissue and characteristically were umbilicated (Fig. 3, c). In 1 patient the primary, a carcinoid tumour of the rectum, was known (Fig. 3, d). Three were adenocarcinomata, the primary tumour presumably pancreatic. Clinically the patients presented with ascites (11), hepatomegaly (15), or cholestatic jaundice (5). Postmortem examination was done in 4 of the 15 patients where histological evidence of malignancy was missing; 3 additional primary liver cancers were found and 1 secondary carcinoma oesophagus. Cirrhosis was encountered in 9 of the 12 patients with primary carcinoma of the liver. The macroscopical type of cirrhosis was micronodular in 4 patients (Fig. 3, e) coarsely nodular in 1 patient, and postnecrotic scarring was seen in 1 patient (Fig 3, f). The cirrhosis was not characteristic in 3 patients; in 2 of these, the liver was markedly atrophic.

Cirrhosis

Fifty-six patients had cirrhosis of the liver without carcinoma. They presented with ascites not responding to treatment or a 'doughy abdomen' (40 patients) or with hepatomegaly or pain (16 patients). The macroscopical diagnosis of cirrhosis was made at peritoneoscopy if the liver surface showed an unequivocal nodular appearance.

Micronodular cirrhosis was present in 16 livers (Fig. 3, g), 11 were coarsely nodular (Fig. 3, h), 1 showed postnecrotic scarring and 8 patients had cardiac cirrhosis. Nineteen shrunken livers (Fig. 3, i) were found difficult to classify according to the categories of Gall.⁷ One smooth, brick-red liver was diagnosed macroscopically as possible hepatitis, but micronodular cirrhosis was found histologically. Portal hypertension was present in 35 patients. This was evident as congestion of the falciform ligament, parietal peritoneum, and mesenteric and gastric vessels. In 8 patients, white pinhead-size vesicles were scattered over the liver surface. This is evidence of a severe portal hypertension with formation of lymphatic cysts under Glisson's capsule.⁸ When the liver shrinks due to fibrosis, the gall bladder is lifted up and often appears 'erected'. This was so in 38 instances in our series. Eighteen liver

biopsies were done under direct vision. The histological diagnosis was in agreement with the macroscopical diagnosis of cirrhosis in 12 patients. In 4 patients the histological specimens were too small to confirm cirrhosis. One unsuspected hepatocellular carcinoma was found on biopsy and 1 patient had amyloidosis (Fig. 3, j).

Various Liver Conditions

Heterogeneous liver diseases were seen in 26 patients: big red livers compatible with hepatitis (6 patients), fibrotic livers without nodular changes but with fatty or siderotic infiltration (18 patients) and Riedel's lobe (2 patients). The examination was normal in 14 cases.

Cholestasis

Cholestasis alone was seen in 18 patients. It was considered to be intrahepatic in 8, extrahepatic in 6 and of doubtful origin in 4 patients. Cholestasis was also found to be present in association with 5 carcinomata of the liver (Fig. 3, k, l). The types of cholestasis are listed in Table III. If the peritoneoscopic picture was compatible with extrahepatic cholestasis or was equivocal, liver biopsy was avoided and laparotomy advised.

Non-Specific Peritoneal Inflammation

In 49 instances, non-specific peritoneal inflammation was observed. This was sometimes localised, predominantly around the liver, and resulted in the adherence of the hepatic surface to the abdominal wall by thick or 'violin string' adhesions, giving the appearance of perihepatitis. This was present in 23 patients. In 6 patients extensive adhesions hindered adequate observation of the upper abdominal organs. Peritoneal biopsies were done in 12 cases of which 11 showed non-specific inflammatory reaction and 1 patient fat necrosis. Liver biopsies were done on 4 occasions, revealing fat infiltration and siderosis. The clinical indications for peritoneoscopy in this group were: ascites not responding to treatment or

Fig. 3. See opposite page. (Please note that the pictures are upside down.)

(a) Tuberculous peritonitis. Miliary nodules are scattered on the surface of a red liver. Adhesions bind the liver to the diaphragmatic peritoneum.

(b) Close-up of tuberculous nodules and streaks of fibrin scattered on a bowel loop.

(c) Secondary liver carcinoma possibly pancreatic in origin. The umbilication is typical.

(d) Hepatic secondaries from a carcinoid tumour of the rectum.

(e) Fleshy appearance of a hepatocellular carcinoma. Micronodular cirrhosis. The patient had blood-stained ascites but no palpable liver.

(f) Hepatocellular carcinoma on top of postnecrotic scarring. Two 'blind' biopsies had failed to confirm malignancy.

(g) Micronodular cirrhosis.

(h) Coarse nodular liver with portal hypertension on the falciform ligament and diaphragmatic peritoneum.

(i) Shrunken liver in Black boy, aged 17 years, with splenomegaly and hypersplenism. The liver was clinically not palpable and liver biopsy was contra-indicated in the presence of low prothrombin index and platelet count.

(j) Amyloidosis. The gall bladder is infiltrated.

(k) Liver of cholestasis, enlarged and green.

(l) Close-up of malignant nodules on right lobe of the same liver. Bile-producing hepatocellular carcinoma on histology.

(m) Liver in sarcoidosis.

(n) Cholecystomucocele in a case of cholestatic jaundice.

(o) Primary biliary cirrhosis. Note the empty gall bladder.

Other Conditions

Retroperitoneal pathology was suspected in 7 patients with clinically unidentifiable abdominal masses. The gynaecological conditions included 1 ovarian carcinoma, 1 ovarian cyst and 1 pregnancy.

Complications

Perforation of a bowel loop occurred in 1 patient with tuberculous peritonitis. At laparotomy immediately thereafter, the perforation was sutured and the diagnosis of tuberculous peritonitis confirmed. The postoperative course was uneventful. Hepatic failure was possibly precipitated by the procedure in 1 patient who had carcinoma of the liver, and died in hepatic coma 4 days after the peritoneoscopy. Another patient with advanced cirrhosis became abnormally deeply sedated by 5 mg diazepam given intravenously, but recovered overnight. No haemorrhagic or embolic complications occurred. Leakage of ascitic fluid through the incision was seen early in the series if ascitic fluid was abundant; this was later avoided by employing a continuous suture in the presence of gross ascites. Skin emphysema occurred in 2 patients. The procedure had to be interrupted in 7 instances: 3 young patients were unco-operative despite the sedative given; and in 4 a proper pneumoperitoneum was not created, probably because of extensive intra-abdominal adhesions.

A death following peritoneoscopy has been reported and attributed to air embolism.⁴ The use of carbon dioxide instead of air was advocated. We have encountered no complications using air. If the pneumoperitoneum needle (Verres needle) is positioned correctly in the peritoneal cavity, 5 ml of injected air should flow without resistance and should not be recoverable by subsequent gentle aspiration. Various other tests can be employed to ensure that the end of the needle is indeed located in the free abdominal cavity.⁵ Insufflation with CO₂ produces a rise in the p_aCO₂⁹ and the end-tidal CO₂ concentration¹⁰ and may cause cardiac arrhythmias or cardiac arrest.

DISCUSSION

Peritoneoscopy is a useful diagnostic tool when laparotomy is contra-indicated and when other diagnostic methods fail. The yield in diagnosis of tuberculous peritonitis is improved by peritoneoscopy.¹¹ The success of a 'blind' peritoneal biopsy is variable (64% in a series by Singh *et al.*¹²). The diagnosis of tuberculosis on peritoneoscopy obviates the 2-8-week wait for culture of ascitic fluid for acid-fast bacilli. The appearance of tuberculous peritonitis is typical and the diagnosis is virtually certain, even if histology is inconclusive. Twelve of our 30 peritoneal biopsies were inconclusive, possibly due to anti-tuberculous therapy prior to the procedure. The clinical impression of a 'doughy abdomen' may be misleading. The abdomen was felt to be doughy by the referring clinician in 27 patients. In 14 of these, extensive adhesions were found. These were histologically shown to be tuberculosis in 6 patients, and non-specific inflammation in 8

TABLE III. CHOLESTASIS

Biopsy	Follow-up
Intrahepatic	
Primary biliary cirrhosis	Wedge biopsy at laparotomy, confirmed
Active hepatitis	Jaundice cleared
Not done	Lost to follow-up
Active hepatitis	Jaundice cleared
Fibrous tissue	Jaundice cleared
Coarse nodular cirrhosis	Jaundice cleared
Eosinophilia	Jaundice cleared
Not done	Lost to follow-up
Extrahepatic	
Not done	Refused laparotomy
Not done	Refused laparotomy
Not done	Lost to follow-up
Not done	Lost to follow-up
Not done (cholecystomucocele seen)	Cholecystomucocele (chronic cholecystitis)
Not done	Lost to follow-up
Doubtful origin	
Not done	Cholecystitis
Not done	Carcinoma of the liver (post-mortem)
Not done	Jaundice cleared
Not done	Lost to follow-up

'doughy abdomen' (22 patients); hepatomegaly with abnormal liver scan (11 patients); atypical abdominal pain (5 patients); pyrexia of unknown origin (3 patients); and small or large intestinal patterns suggestive of tuberculosis on contrast radiography (8 patients).

patients. The procedure had to be interrupted in 3 other patients, also due to extensive adhesions. In these 17 patients the use of the term 'doughy abdomen' could be justified. In the remaining 10 patients there was no evidence of tuberculosis or adhesive reaction in the abdomen to substantiate the impression of doughiness.

Peritoneoscopy was embarked upon in 25 patients where small-intestine X-ray films or barium enemas were suggestive of intestinal tuberculosis. This was not rewarding, as a tuberculous granuloma was obtained from a liver biopsy in only 1 patient. In a second patient, enlarged mesenteric lymph nodes were seen and chylous ascites was present, but no biopsy was possible. Non-specific peritoneal inflammation was observed in 8 additional cases. In our series, abdominal tuberculosis appeared to affect the various abdominal compartments separately (intraluminal, serosal, glandular). In the series of tuberculous peritonitis reported by Singh *et al.*²¹ small-intestine X-ray films were normal.

Peritoneal carcinomatosis provides the highest yield in conclusive biopsies (7 carcinomata in 8 biopsies). Histological proof of carcinoma of the liver may be obtained by 'blind' liver biopsy or a biopsy under direct vision at peritoneoscopy. Biopsy under direct vision has the distinct advantage that the needle can be guided towards localised suspicious-looking lesions which are missed by 'blind' biopsy. This is especially true for secondary hepatic tumours. Even if a biopsy is contra-indicated because of an uncorrected bleeding problem, the macroscopical appearance at peritoneoscopy may be unequivocal. A low prothrombin index may be a contra-indication for a liver biopsy, but not for a small incision in an avascular non-hepatic area. The 9 'insufficient' specimens in our 25 biopsies in patients with carcinoma of the liver were from fibrotic livers; there are technical difficulties in obtaining adequate specimens from such livers, and it is not wise to perform a deep aspiration biopsy in heavily vascularised tumours. A deeply seated primary carcinoma was missed in 1 patient, the appearance was described as micronodular cirrhosis, but malignant tissue was present in the biopsy specimen.

A secondary carcinoma was thought to be present in 1 case but not confirmed by biopsy (Fig. 3, m). The patient, a 35-year-old Indian woman, while on treatment for cervical adenitis considered tuberculous in nature, complained of abdominal swelling. A 3-fingerbreadths, firm hepatomegaly with ascites was found. Malignant cells were seen on cytological examination of the ascitic fluid. Yellow patches about 1 cm in diameter, with irregular margins and mildly raised over the smooth hepatic surfaces, were observed at peritoneoscopy. The appearance was suggestive of secondaries. To our surprise, the histology showed granulomatous tissue with no acid-fast bacilli. The diagnosis of tuberculosis was reviewed and sarcoidosis considered likely. The hepatomegaly melted away under steroid therapy.

The liver scan in cirrhosis may show cold areas due to pseudotumours, which are not easily distinguishable from true hepatic tumours.²² In addition, an atrophic right hepatic lobe may show as a large cold area. In these situations peritoneoscopy can exclude hepatocellular carcinoma with

reasonable certainty. The correlation between the macroscopical appearance of the liver at peritoneoscopy and histology, is excellent in cirrhosis.²³ Tuberculous peritonitis may be responsible for the deteriorating clinical condition in patients with cirrhosis, and this occurred in 5 patients in our series. In patients with splenomegaly, and clinical and laboratory evidence of cirrhosis and hypersplenism, the small non-palpable liver with evidence of portal hypertension will be observed on peritoneoscopy. The useful role of peritoneoscopy in investigating portal hypertension has been reviewed.¹⁴ A fibrotic liver without nodules is not cirrhosis,¹⁵ although the nodular changes may not be apparent under a thick hepatic capsule. In 17 biopsies of livers described as fibrotic but non-cirrhotic, there was 1 with nodular changes.

Finding non-specific peritoneal inflammation does not necessarily mean failure to make a diagnosis. Adhesions around an enlarged liver suggest an inflammatory process like amoebic liver abscess, rather than a liver carcinoma. In 1 patient scattered calcifications were found on peritoneal adhesions. Histological examination revealed fat necrosis, and relapsing pancreatitis was confirmed on follow-up.

The appearance of a cholestatic liver is characteristic. Features of extrahepatic cholestasis include a big gall bladder (Fig. 3, n) and a dark-green or green-spotted liver. Intrahepatic cholestasis (Fig. 3, o) is characterised by an empty gall bladder and mild discoloration of the liver.¹⁶ It must be noted that the gall bladder may also be empty in carcinoma of the bifurcation of the hepatic ducts.¹⁷ When there is doubt, laparotomy is indicated. One of the major contributions of peritoneoscopy is the avoidance of unnecessary general anaesthesia and laparotomy in patients with advanced carcinoma of the liver presenting as cholestasis.

Clinically unidentifiable masses are usually not seen at peritoneoscopy; they are frequently retroperitoneal and intestinal loops and omentum lie in front of them. In some series claims were made that the spleen was seen in 9 out of 10 occasions by tilting the patient in various positions.¹⁴

Only one major complication in this series was directly attributable to the procedure. Perforation of the small bowel could have been avoided. Hepatic encephalopathy was perhaps triggered by diazepam intravenously, although the drug is considered safe in chronic liver disease.¹⁹ We now avoid sedation if circumstances permit. Other drugs are on trial for premedication and this is the subject of a further report.

Peritoneoscopy is a safe procedure. Its degree of technical difficulty can be compared to peritoneal dialysis, commonly done in medical wards. Although a surgical theatre is preferable, a plain endoscopy room is suitable for the procedure.

We wish to thank the physicians and surgeons who referred the patients to us.

REFERENCES

1. Quinlan, D. K. (1972): *S. Afr. Med. J.*, **46**, 675.
2. Mayat, M. G. M. (1971): *Ibid.*, **45**, 701.
3. Heselson, J. (1965): *Ibid.*, **39**, 371.
4. McQuaide, J. R. (1972): *Ibid.*, **46**, 422.

5. Wittman, I. (1966): *Peritoneoscopy*, pp. 23 - 25. Budapest: Akadémiai Kiadó.
6. Jacobs, E. in Padova, E. D., Marcozzi, G. and Crespi, M., eds. (1972): *Advances in Gastro-intestinal Endoscopy*, p. 927. Piccin.
7. Gall, A. (1960): *Amer. J. Path.*, **36**, 241.
8. Lent, H. (1969): In *Endoscopy of the Digestive System*, pp. 102 - 103. Basle: Karger.
9. Scott, D. B. and Julian, D. G. (1972): *Brit. Med. J.*, **1**, 411.
10. Smith, I., Benzie, R. T., Gordon, N. L. M., Kelman, G. R. and Swapp, G. M. (1971): *Ibid.*, **3**, 410.
11. Singh, M. M., Bhargava, A. N. and Jain, K. P. (1969): *N. Engl. J. Med.*, **281**, 1091.
12. Eddleston, A. L., Rake, M. O., Pagaltos, A. P., Osborn, S. B. and Williams, S. R. (1971): *Gut*, **12**, 245.
13. Abstracts (1965): *Dtsch. Gesundh.-Wes.*, **26**, 20.
14. Jori, G. P. and Mazzala, G. (1971): *Gut*, **12**, 237.
15. Sherlock, S. (1968): In *Diseases of the Liver*, p. 396. Philadelphia: F. A. Davis.
16. Lenzi, G. and Cavassini, G. B. (1960): In *La laparoscopie*, p. 274. Paris: Masson.
17. Klatskin, G. (1965): *Amer. J. Med.*, **38**, 241.
18. Müller, K. (1969): In *op cit.*⁸, pp. 107 - 109.
19. Murray-Lyon, I. M., Young, J., Parkes, J. D., Knill-Jones, R. P. and Williams, R. (1971): *Brit. Med. J.*, **4**, 265.