

Eosinophil Infiltration of the Stomach

D. A. WARMINGTON, J. J. RIPPEY

SUMMARY

Eosinophil infiltration of the stomach or gastro-intestinal tract is an unusual condition, in which an inflammatory infiltrative condition may present as a tumorous mass simulating a malignant growth. Although the condition was first described in 1937 and a number of cases have since been reported, not a great deal is known about it. Its aetiology is obscure and its behaviour variable. Patients in whom the disease is likely to spread widely through the stomach and small intestine, and where it is likely to recur and progress, may have eosinophilia.

S. Afr. Med. J., 48, 405 (1974).

This condition was first reported in 1937,¹ and is not very well known, although a number of cases have since been reported. Cases where the disease is likely to spread through the stomach and small intestine may be associated with a peripheral eosinophilia.²

CASE REPORT

A Black man, aged 34 years, was admitted to Tembisa Hospital with a 4-day history of epigastric pain and vomiting. There was a 3-day history of the passage of tarry stools. The patient had recently lost 9 kg in mass. Physical examination was unremarkable apart from some tenderness in the epigastrium.

Investigations

The haemoglobin was 13,1 g/100 ml, the red cells were normocytic and normochromic. The total white blood cell count was 16 300/mm³; eosinophils formed 2% of the white blood cell count, i.e. 330/mm³, which is within the normal range of 40-440/mm³.³ Blood urea and electrolytes were within normal limits and X-ray examination by barium meal showed what appeared to be an ulcer at the apex of the duodenal cap.

Course

A clinical diagnosis of peptic ulcer was made and the patient underwent a laparotomy at which a lesion like

a tumour of the pyloric antrum and an area of infiltration of the pylorus were found. The pyloric infiltration appeared to be causing some obstruction, so a subtotal gastrectomy was performed.

There was an uneventful recovery and the patient was discharged from hospital 9 days after the operation. Three weeks later he was well and the white cell count was 6 200/mm³, and no eosinophils were observed in the peripheral blood. Tests for bilharziasis, amoebiasis, and hydatid disease were negative.

PATHOLOGY

The specimen consisted of a stomach measuring 9 cm along the lesser curvature and 14 cm along the greater curvature.

An irregular, firm, haemorrhagic, nodular zone of thickening extended from the lesser curvature to the anterior wall of the stomach; it measured about 3 cm × 4 cm. A similar area of thickening and distortion of tissue was present in the pylorus, where the lesion appeared to be causing some obstruction.

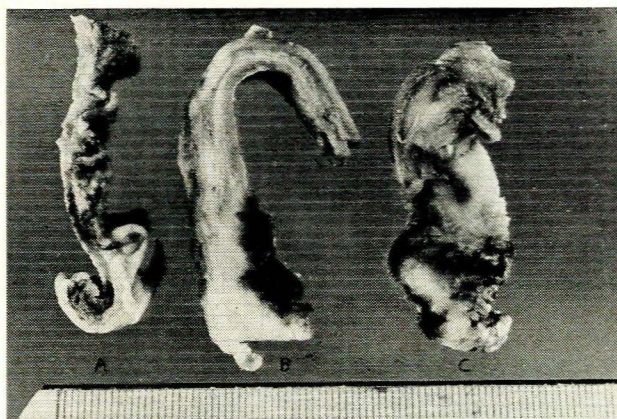


Fig. 1. (a) Normal stomach wall; (b) lesion on lesser curvature; (c) pyloric region.

Fig. 1 shows (a) on the left, the normal stomach wall in cross-section; (b) a section of the lesion from the lesser curvature; and (c) a section through the pyloric region. The degree of thickening can be readily appreciated. Macroscopically, the mucosa over both nodular thickened areas appeared intact, and on section through the full thickness of the lesion, it was still possible to distinguish clearly the anatomical layers of the stomach wall. Three slightly enlarged lymph nodes were dissected from the curvatures of the stomach. On microscopic examination the mucosa of the stomach was intact in all

School of Pathology, South African Institute for Medical Research and University of the Witwatersrand, Johannesburg

D. A. WARMINGTON, M.B. B.CH.

J. J. RIPPEY, M.B. B.S., M.R.C.P., M.R.C. PATH., D.P.H.

Paper presented in part at a meeting of the Transvaal Society of Pathologists, March 1973.

the sections examined. The muscle coat of the stomach was hypertrophic. There was marked oedema of the stomach wall, which caused a separation of the muscle bundles and marked thickening of the serosal coat (Fig. 2).

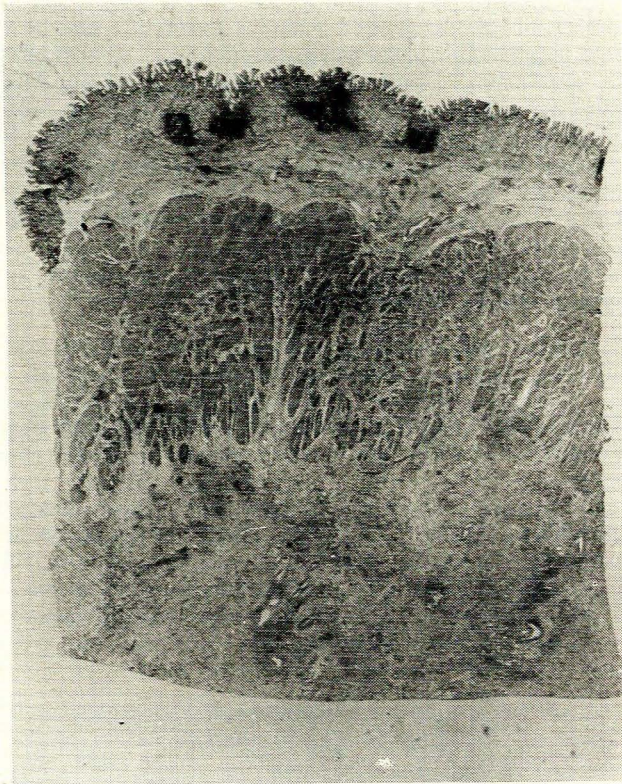


Fig. 2. Low-power view of stomach wall showing inflammatory infiltration and separation of tissues of stomach wall.

The submucosa, muscle and serosa of the stomach contained a heavy, irregularly diffuse, cellular infiltrate; there were a large number of eosinophils with an admixture of plasma cells and lymphocytes (Fig. 3). In several sections

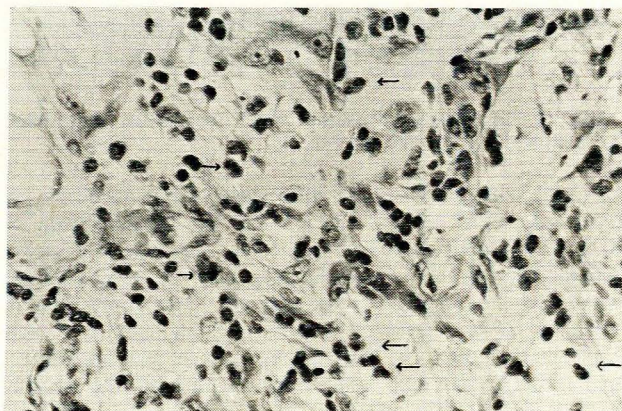


Fig. 3. Nature of inflammatory infiltrate. Arrows indicate eosinophils.

perivascular fibrosis was noted. The lymph nodes showed a non-specific lymphadenitis and only an occasional eosinophil in the sinuses of the nodes.

The pathological diagnosis was an eosinophil infiltration of the stomach.

DISCUSSION

Gastro-intestinal tract involvement by eosinophil infiltration is a well-recognised but uncommon disorder. In the literature this condition occurs under a somewhat confusing list of names among which are eosinophil infiltration of bowel, gastric lesions of Loeffler's syndrome, inflammatory pseudotumour of the stomach, and gastro-intestinal eosinophil granuloma. The latter term particularly is to be deprecated as it could be confused with the eosinophil granuloma type of the histiocytosis X group of diseases. Eosinophil infiltration of the gastro-intestinal tract may present at any age, but is unusual in childhood. It may present with diffuse or localised involvement of the gut, and in the case of the localised form, the stomach, especially the prepyloric area, is most commonly affected. Infiltration in the stomach may take the form of a polyp of eosinophil-rich tissue. When the condition presents in a more diffuse form in the stomach, the clinical picture may be that of carcinoma of the stomach.

Recent studies have suggested a relationship between the location of the eosinophil infiltration and the presence or absence of peripheral eosinophilia.² Patients with eosinophilia appeared to present more often with multiple, poorly-defined lesions in the small intestines, and only rarely in the stomach, whereas patients without eosinophilia appeared with well-defined single lesions which, in 50% of cases, were in the stomach.

The aetiology of eosinophil infiltration of the gastro-intestinal tract is as yet uncertain, and over the years various factors have been implicated. Parasites have been found in some reported cases of gastro-intestinal eosinophil infiltration, but infestation is not a constant feature. Other authors have suggested that an immune mechanism may be responsible for the disease, as either an auto-immune phenomenon or a reaction to an exogenous antigen.

In one of the earliest case reports of this condition special mention was made of an apparent association between the patient's disease and his avid ingestion of raw onion, a habit of many years.¹ Further support for the suggestion of a sensitivity reaction being of aetiological significance in this disease, is provided by Cromwell and Campbell⁴ who were able to produce an eosinophil gastritis in a guinea pig by means of daily injections of human gamma globulin into the subserosal area of the stomach. The long-term prognosis of eosinophil infiltration of the stomach is variable; some patients have made a good recovery after treatment, with either steroids or surgical removal of the affected parts of the gut. Other patients have had recurrence of the disease after similar treatment. In this regard, recurrence appears to be more common in the more extensive forms of the disease, and patients with localised single, or well-defined lesions, are less likely to have progressive disease.²

Of considerable interest with regard to the prognosis for this condition is a recent report of a case⁵ where the initial picture of localised gastro-intestinal eosinophil infiltrate (accompanied by eosinophilia in the peripheral blood) terminated a few months later with disseminated eosinophil disease involving not only the gastro-intestinal tract and mesenteric lymph nodes, but also the heart and kidneys.

We wish to thank Dr E. Moffa under whose care this patient was admitted to hospital.

REFERENCES

1. Kaijser, A. (1937): *Arch. klin. Chir.*, **188**, 36.
2. O'Neill, T. (1970): *Brit. J. Surg.*, **57**, 704.
3. Dacie, J. V. (1970): *Practical Haematology*, 4th ed. London: J. & A. Churchill.
4. Cromwell, T. and Campbell, D. (1971): *Surgery*, **69**, 300.
5. Marko (1972): *Amer. J. Gastroent.*, **57**, 318.