

## BLASTOMYCOSIS OF THE SPINE WITH PARAPLEGIA\*

J. D. OSMOND, F.R.C.S.(I), G. SCHWEITZER, F.R.A.C.S., J. M. DUNBAR, M.D., M.R.C. PATH. AND W. VILLET, M.B., CH.B., *From the Departments of Orthopaedics, Microbiology and Pathology, University of Natal, Durban*

### SUMMARY

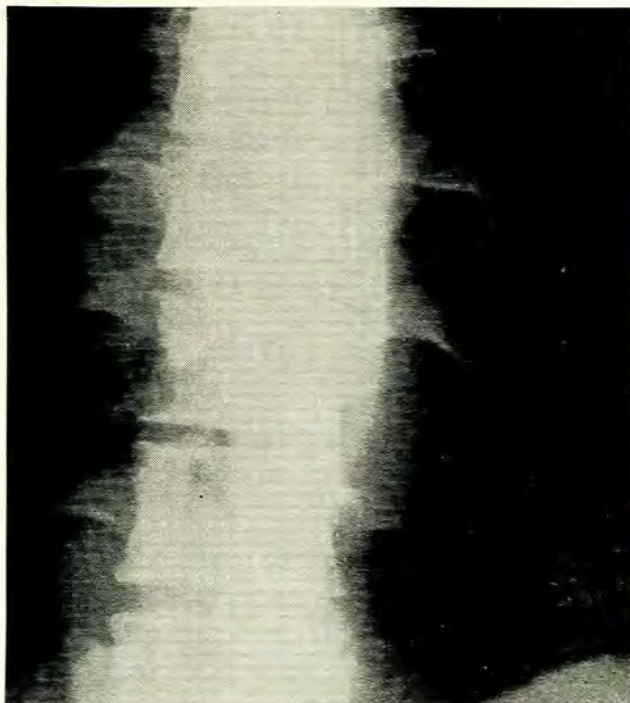
*A case of blastomycosis with vertebral and visceral involvement is presented.*

In an orthopaedic unit which investigates large numbers of patients with spinal tuberculosis, patients with diseases which clinically closely resemble tuberculosis are occasionally seen. Blastomycosis, a fungal infection which has been diagnosed recently in Africa, is one such disease.

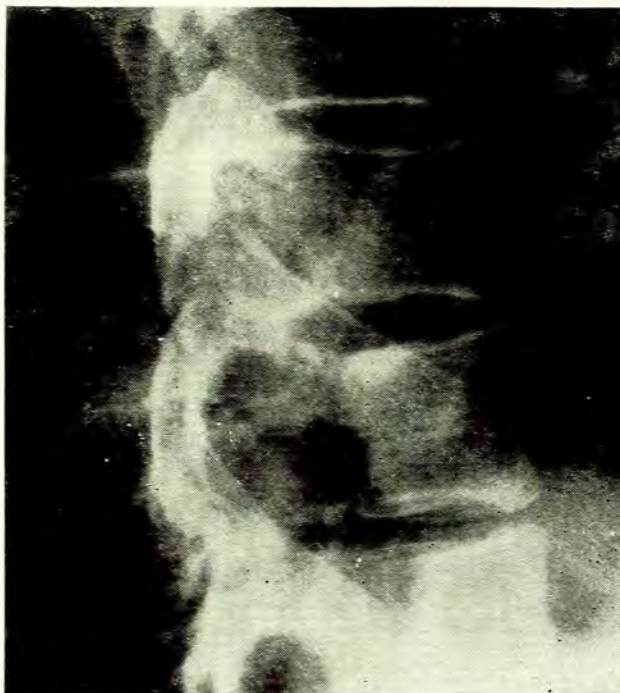
### CASE REPORT

A 39-year-old Zulu male was admitted to King Edward VIII Hospital, Durban, with a 2-month history of paraparesis which had recently progressed to paraplegia. There was no other relevant history. On examination he was found to have paraplegia with a motor level at L.1 and a sensory level at L.2. The erythrocyte sedimentation rate was 41 mm/hour and the Wassermann reaction was negative.

X-ray showed a fusiform paravertebral abscess shadow in the lower thoracic region (Fig. 1). This shadow was widest at the level of T.10. On the lateral film of the thoracic spine there was destruction of the posterior portion of the tenth thoracic vertebral body (Fig. 2). There was also a narrowing of the disc space between the tenth and the eleventh thoracic vertebrae. A myelogram showed a block at the level of T.11 with an extradural pattern.



*Fig. 1. An anteroposterior X-ray of the lower thoracic spine showing a fusiform abscess shadow.*



*Fig. 2. Lateral X-ray of the thoracic spine showing destruction of the posterior portion of the body of the tenth thoracic vertebra and a narrowing of the disc space between the tenth and the eleventh thoracic vertebrae.*

On 12 January 1970 a neurosurgeon performed a dorsal laminectomy and biopsy. At operation the extradural space was found to be occupied by a sleeve of firm, stringy, pinkish-grey tissue. The latter was very adherent to the dura and difficult to separate. A dorsal strip of this tissue was removed for biopsy. The material was not submitted for culture. Histology of the specimen showed fragments of vascular connective tissue. Focal plasma cell infiltration was seen in relation to small vessels.

As the patient failed to obtain relief following the laminectomy, he was transferred to the orthopaedic unit. On 5 March 1970 a costotransversectomy was performed through the bed of the left eleventh rib. A paravertebral abscess containing granulation tissue was found. The body of the tenth thoracic vertebra was found to contain an abscess cavity filled with granulation tissue. The cavity was curetted and packed with bone chips and streptomycin. No tubercle bacilli or pyogenic organisms were grown from specimens sent to the bacteriology laboratory.

Following operation the patient's paraplegia failed to improve and he developed a discharging sinus through the costotransversectomy wound. It was still thought at this stage that the patient was suffering from spinal tuberculosis and that the infecting organism had possibly become drug-resistant. Having completed a 3-month course of streptomycin, PAS and INH, the patient at this stage was being treated with the two last-mentioned drugs. Because of the

possible bacterial resistance, PAS and INH were discontinued and Myambutol and ethionamide were substituted. In spite of this the patient continued to deteriorate.

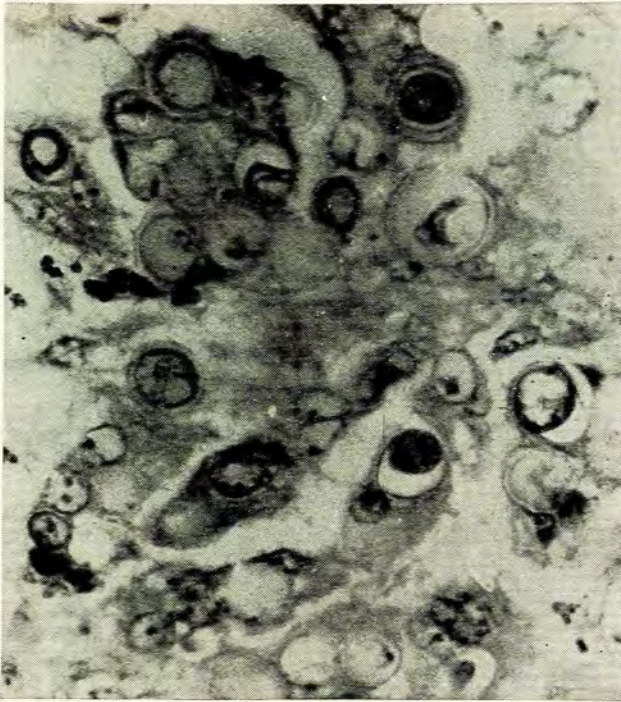

Fig. 3. Biopsy specimen from the tenth thoracic vertebra showing blastomycetes.

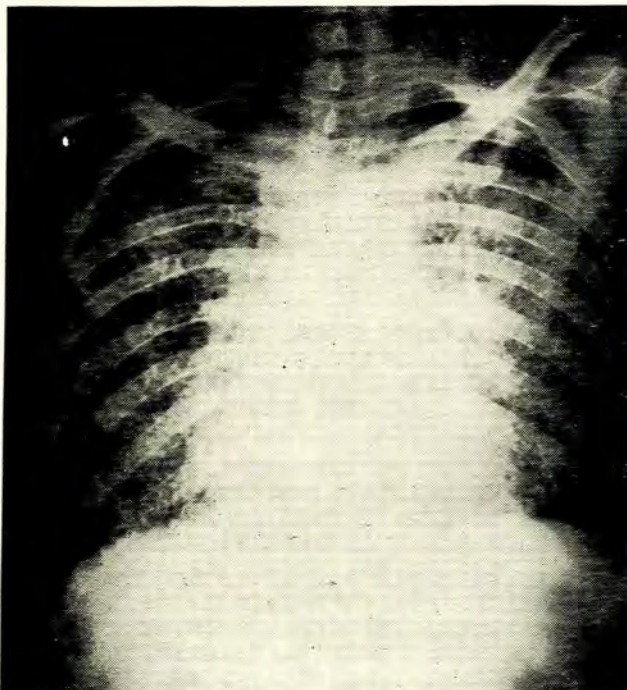


Fig. 4. X-ray of the chest showing bronchopneumonic changes.

On 23 June 1970 an anterolateral decompression was performed. At operation the spinal cord was found to be surrounded by pus, sequestra and granulation tissue. There was an extensive destruction of the vertebrae and the intervening discs over an area of approximately 12 cm. Histology of the removed tissue showed blastomycosis (Fig. 3). The pus obtained at operation was not cultured on Sabouraud's medium as at this stage fungal infection was still not suspected. As soon as the histological diagnosis became available, a course of amphotericin B given intravenously was immediately commenced. During the course the patient became unco-operative and constantly removed the intravenous infusion cannula. He deteriorated further, developed bronchopneumonia (Fig. 4), would not eat or drink, refused a gastrostomy and died.

The autopsy disclosed partial destruction of the bodies of the tenth and eleventh thoracic vertebrae. The spinal cord was also destroyed in this region. A paravertebral abscess was present on the left side with destruction of the posterior ends of the ninth, tenth and eleventh ribs (Fig. 5). The destroyed vertebrae were replaced by granulation tissue. On opening the cranial cavity, basal meningitis was found (Fig. 6). The lungs were uniformly granular

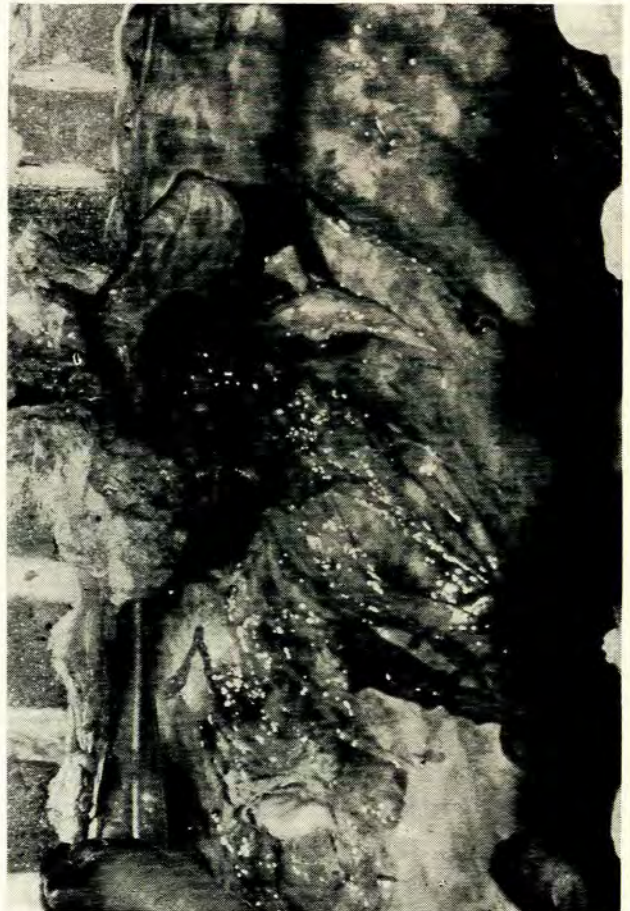

Fig. 5. Postmortem specimen of the spine showing destruction of vertebral bodies and a paravertebral abscess on the left side.

with mild oedema, congestion and pneumonia (Fig. 7). The urinary bladder was grossly distended and thickened. Bilateral pyelonephritis was present.

We were unable to culture fungi from any of the organs. Histology showed *Blastomyces dermatitidis* in the granulation tissue replacing the vertebral bodies, lungs

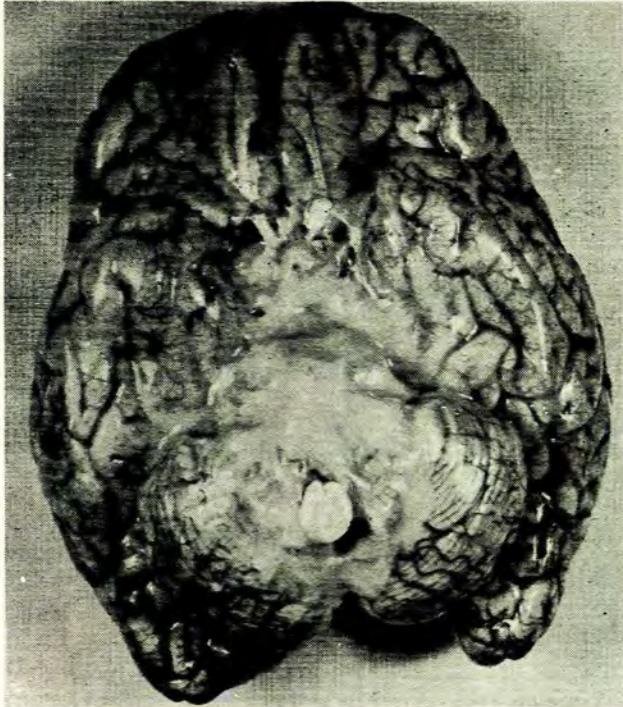

Fig. 6. The brain at postmortem examination showing basal meningitis.

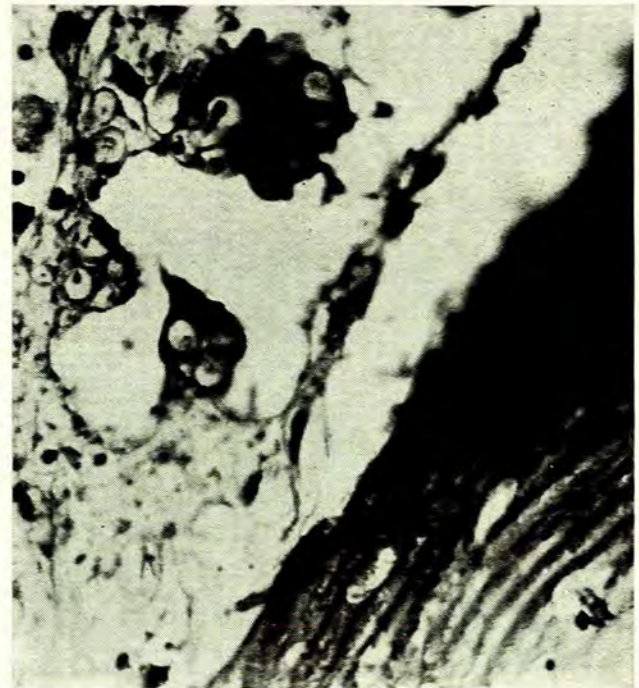

Fig. 8. Microscopic section from the tenth thoracic vertebra showing blastomycetes.




Fig. 7. The left lung at postmortem examination showing congestion.

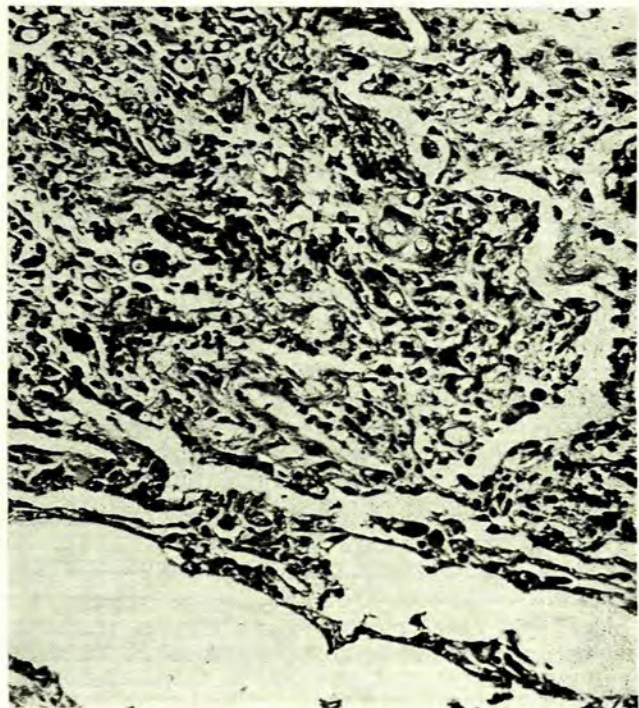


Fig. 9. Microscopic section from the left lung showing blastomycetes.

and kidneys (Figs. 8-10). We were unable to demonstrate fungi in the brain or in the meninges. Culture of the pus at the base of the brain did not yield any organisms.

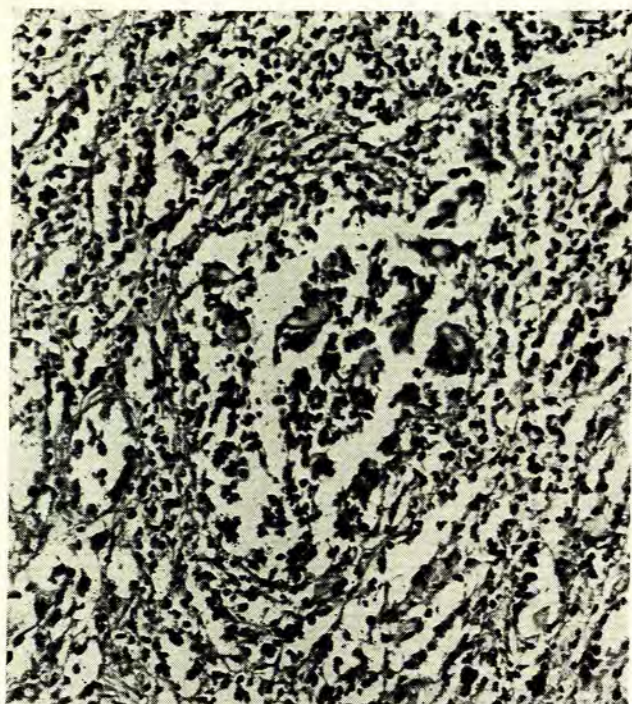


Fig. 10. Section from the right kidney showing pyelonephritis. Blastomycetes are also present in the centre of the picture.

#### DISCUSSION

In an Orthopaedic Unit which treats large numbers of patients with spinal tuberculosis, surprises sometimes occur. It is only when the results of histology and microbiology become available that a lesion which was pre-operatively thought to be tuberculous is found to be something quite different.

During the period from 1 December 1969 to 1 October 1970, 88 cases of spinal tuberculosis were treated in our unit. During this time a case of typhoid spondylitis, reported previously,<sup>1</sup> and a case of blastomycosis were admitted. Both of these lesions were initially thought to be tuberculous. During the previous 4 years, one of the authors (J.D.O.) while working at Livingstone Hospital in Port Elizabeth, encountered 2 cases of spinal hydatid which closely resembled tuberculosis. The Livingstone Hospital Orthopaedic Unit also handles a large number of cases of spinal tuberculosis.

Blastomycosis of the spine is becoming diagnosed more frequently in Southern Africa. A case was presented at a Clinical Staff Conference at Harare Hospital, Salisbury, Rhodesia and was subsequently reported in the literature.<sup>2</sup> During the ensuing discussion Prof. S. Morton stated that he had seen 2-3 cases of spinal blastomycosis during the preceding year. Blastomycosis is caused by *Blastomyces dermatitidis*, a fungus which occurs in the soil or on

vegetables. The condition should therefore be suspected in farm-workers. Of the domestic animals, dogs are the only species to be spontaneously infected. Blastomycosis is a chronic suppurative and granulomatous condition which may be confined to the skin or be disseminated and involve the bones, viscera and meninges. The appearances in the lungs are very similar to miliary tuberculosis as was seen in our case.

The infection is probably acquired by the inhalation of spores or by direct inoculation into the skin. If bone is involved there may be extensive necrosis and suppuration. Sinuses discharging at some distance from the lesion may be present,<sup>3</sup> as was seen in our patient. The thoracic and the lumbar vertebrae are the bones most commonly involved. A case where the knee joint was involved was recently reported.<sup>4</sup> The infection spreads up and down the spine by tracking under the anterior longitudinal ligament.<sup>5</sup> 'Skip lesions' may occur. The X-ray appearance strongly resembles tuberculosis. However, as Morton<sup>2</sup> has pointed out and as is seen in our case, the initial destruction of the vertebral bodies appears to begin on the posterior surface. Scalloping of several successive vertebral bodies may occur. A paravertebral abscess is often present and may be unilateral or bilateral. The abscess often erodes the adjacent ribs, a feature rarely seen in tuberculosis and present in our case. In the lumbar region a psoas abscess may be present.

Differentiation between blastomycosis and tuberculosis may, on occasions, be made pre-operatively by using serological tests. However, to establish an unequivocal diagnosis of blastomycosis, current serological procedures, such as complement-fixation using yeast from antigen are considered inadequate. In the disseminated and progressive disease, less than 50% of proved cases give a positive result and some give a cross-reaction with the histoplasma antigen. Reactions greater than 1:8 against the homologous strain may give presumptive evidence. The skin test antigen, blastomycin, like tuberculin may be used to detect past infection.

The prognosis in blastomycosis is variable. Death may occur in the first or second year or the patient may survive up to 15 years. Amphotericin B and the aromatic diamidines such as dihydroxystilbamidine may produce remissions and may result in a permanent cure.

We wish to thank Dr H. R. J. Wannenburg, Medical Superintendent of King Edward VIII Hospital, Durban, for permission to publish the case report; Dr I. G. Murray of the Mycology Department, London School of Hygiene and Tropical Medicine, for his help in identifying the causal organism; Mr R. Stuart of the Photographic Department for the photographs; and Mrs D. Hyman for secretarial assistance.

#### REFERENCES

1. Schweitzer, G., Hoosen, G. M. and Dunbar, J. M. (1971): *S. Afr. Med. J.*, **45**, 126.
2. Harare Hospital Staff Round (1968): *Cent. Afr. Med. J.*, **14**, 82.
3. Gehweiler, J., Capp, M. and Chick, E. (1970): *Amer. J. Roentgenol.*, **108**, 497.
4. Liggett, A. and Silberman, Z. (1970): *J. Bone Jt Surg.*, **52-A**, 1445.
5. Baylin, G. and Wear, J. (1953): *Amer. J. Roentgenol.*, **69**, 395.