

# Mechanisms and management of heart failure in active rheumatic carditis

J. B. BARLOW, R. H. MARCUS, W. A. POCOCK, C. W. BARLOW,  
R. ESSOP, P. SARELI

## Summary

Fulminating active rheumatic carditis has been observed for over three decades in this environment with no recent alteration in either the incidence or the pattern of presentation. Heart failure (in this context defined as 'an inadequate circulation at rest together with a raised pulmonary venous pressure, with or without an associated high systemic venous pressure in the absence of haemodynamically significant tricuspid valve disease or pericardial effusion') is prevalent but occurs only when a haemodynamically important left-sided valve lesion supervenes. Regurgitation is the predominant valve lesion and involves principally the mitral valve. Mitral annular dilatation is marked and predisposes to lengthening — or rupture — of chordae tendineae and prolapse of the anterior leaflet. The resultant cardiac work-overload apparently perpetuates or aggravates the rheumatic activity. Heart failure, as defined, whether caused by or associated with active rheumatic carditis, makes surgical management of the valve lesion mandatory as a life-saving measure. Aggressive medical therapy for heart failure, which should include vasodilator drugs and especially angiotensin-converting enzyme inhibitors, provides temporary improvement only. Contrary to ongoing doctrine, treatment with steroid drugs in this context is neither life-saving nor beneficial.

*S Afr Med J* 1990; 78: 181-186.

There is almost universal agreement that rheumatic fever and rheumatic heart disease are always preceded by infection with group A  $\beta$ -haemolytic streptococcus. Factors that increase the likelihood of development of rheumatic fever after infection with this organism include significant antibody responses, the presence of an exudative pharyngitis, and the persistence of the group A streptococcus in the pharynx for at least 21 days during convalescence.

In most developed countries, the reported incidence of both rheumatic fever and rheumatic heart disease has declined drastically. The fact that the onset of this decline preceded the advent of antibiotics indicates that factors other than streptococcal infection must play a role in the pathogenesis of this condition. Despite world-wide research, the factors causing a high prevalence of rheumatic heart disease in any community remain uncertain. It is favoured that socio-economic factors are important; hence the continued high prevalence of rheu-

matic heart disease in Third-World countries. Rheumatic heart disease remains a major challenge to cardiologists in the Asian-Pacific area. In 1978, Padmavati<sup>1</sup> concluded that 'prophylaxis was hardly worthwhile' in patients encountered for the first time with a late stage of rheumatic heart disease. Such cases comprised 75% of those considered for a secondary prophylaxis programme in India between 1968 and 1974. While it is now rare to encounter white patients in South Africa under the age of 20 years with rheumatic heart disease, the clinical experience of those involved with the diagnosis and treatment of black patients is that rheumatic heart disease remains prevalent and continues to affect young children. In 1972<sup>2</sup> we conducted a survey of 12 050 black schoolchildren in Soweto and detected an overall prevalence rate for rheumatic heart disease of 6,9/1 000, with a peak rate of 19,2/1 000 in children aged about 15 - 18 years.

The exact nature of the relevant 'co-factors(s)' that predispose to rheumatic fever or rheumatic heart disease remains uncertain. In 1930, Glover<sup>3</sup> stated that: 'No disease has a clearer-cut 'social incidence' than acute rheumatism, which falls perhaps thirty times as frequently upon the poorer children of the industrial town as upon the children of the well-to-do . . . the incidence of acute rheumatism increases directly with poverty, malnutrition, overcrowding and bad housing'. Since Glover's<sup>3</sup> comments, the socio-economic factors that have received the most attention are poor nutrition and overcrowding. Hereditary, racial, geographical and blood group factors have also been studied but are probably of minor or no importance. From the data obtained in our survey, we concluded that overcrowding was of importance but that it was not the sole factor. All schools are 'overcrowded' in that the pupils are in close contact with one another, and this will facilitate spread of the  $\beta$ -haemolytic streptococcus. As many as 9% of pupils at an exclusive Johannesburg preparatory school in 1975<sup>4</sup> had throat swabs that tested positive for the  $\beta$ -haemolytic streptococcus, yet rheumatic fever or rheumatic heart disease has not, to our knowledge, been encountered in a pupil at that school during the last three decades. A more recent survey,<sup>5</sup> in which the throats of coloured and Indian schoolchildren were swab-tested, revealed group A  $\beta$ -haemolytic streptococci in 24% and 21%, respectively, during the summer months. The total number of 226 children examined was relatively small, but none had rheumatic heart disease. We did not detect significant malnutrition in the black schoolchildren whom we examined in 1972, but it is possible that poor nutrition during the first year of life renders a child susceptible to rheumatic fever and rheumatic heart disease. Aryanpur-Kashani<sup>6</sup> made this assumption in 1980, and it requires further investigation.

Elucidation of factors predisposing to acute rheumatic fever and rheumatic carditis has not been assisted by the recent apparent resurgence of these entities in the USA.<sup>7,8</sup> In many of the reported cases, the preceding pharyngitis was mild, the incidence of carditis high and the rheumatic fever occurred in middle-class families with ready access to medical care. In their excellent review on the pathogenesis of rheumatic fever, Kaplan and Markowitz<sup>9</sup> concluded that just as the marked decline in incidence of rheumatic fever in Western countries

Cardiovascular Research Unit, Department of Cardiology, University of the Witwatersrand and Baragwanath and Johannesburg Hospitals, Johannesburg

J. B. BARLOW, M.D., F.R.C.P.  
R. H. MARCUS, F.C.P. (S.A.)  
W. A. POCOCK, M.B. B.CH., F.R.C.P.  
C. W. BARLOW, M.B. B.CH.  
R. ESSOP, F.C.P. (S.A.), M.R.C.P.  
P. SARELI, M.D. (HADASSAH)

Accepted 4 May 1990.

Based on an invited lecture delivered by Professor J. B. Barlow at the First International Symposium on Heart Failure, Jerusalem, Israel, 21 - 25 May 1989.

remains 'unexplained', so does the recent resurgence. Moreover, they stated that 'unless and until the pathogenesis of rheumatic fever is fully understood, methods of control will not be optimal'.

### Active, severe rheumatic carditis

A fulminating form of active rheumatic carditis continues to be encountered and has been observed by one of the authors (J.B.B.) for more than three decades. It is difficult to assess the incidence, but there is no evidence to suggest that it is decreasing.<sup>9</sup> During 1986, for example, a total of 339 patients were subjected to mitral valve surgery in our institutions (Fig. 1) and almost all of these had a rheumatic aetiology.

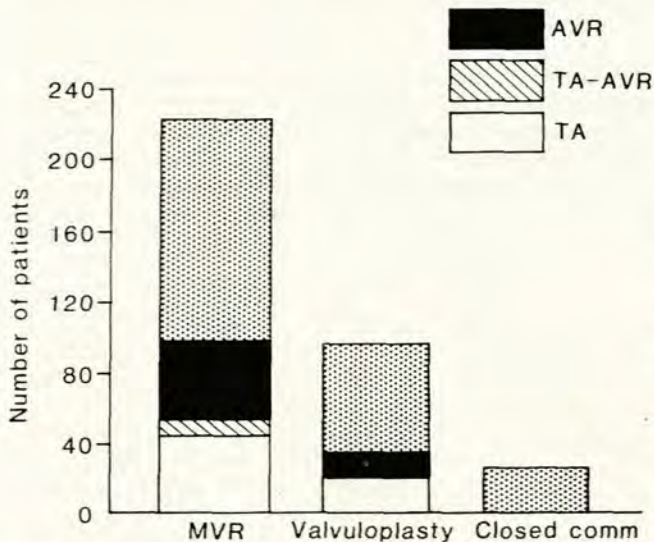


Fig. 1. Analysis of 339 patients who had mitral valve surgery at Baragwanath and Johannesburg Hospitals during 1986. Additional aortic valve replacement (AVR) and tricuspid annuloplasty (TA), either alone or in combination, were required in about one-third of the patients (Closed comm = closed commissurotomy; MVR = mitral valve replacement).

### Clinical features

On the basis of an analysis of 80 patients subjected to valve replacement or repair while in the active phase of rheumatic carditis, the clinical presentation can be outlined (Table I).<sup>9</sup> All but 4 patients were under the age of 21 years. Eighteen patients (23%) were < 10 years and the youngest was 5 years. The children or their parents commonly claimed that symptoms such as tiredness, breathlessness, cough and arthralgia had been present for a few weeks only. Tachycardia of more than 100/min and pyrexia greater than 38°C were present in 96% of patients. The clinical picture was often compatible with infective endocarditis, but the differentiation could usually be made. Relevant distinguishing features are negative blood cultures, absence of splinter haemorrhages or other evidence of systemic embolism, no vegetations on echocardiography, and lack of response to a trial of antibiotic therapy. There was definite clubbing of the fingers in about 15% of patients. This is a little-recognised feature of active rheumatic carditis and may mislead clinicians into diagnosing infective endocarditis. Splenomegaly was detected in about 15% of patients. It is uncertain whether this is causally related to the rheumatic activity or a coincidental feature in a population with a high prevalence of parasitic infestation. A notable symptom was severe anterior chest pain (31 patients), which was typically

TABLE I. CLINICAL FEATURES OF ACTIVE SEVERE RHEUMATIC CARDITIS IN 80 PATIENTS SUBJECTED TO VALVE SURGERY

Clinical features	No. of patients	%
<b>Age (yrs)</b>		
< 10	18	23
10 - 20	58	72
> 20	4	5
<b>Tachycardia (&gt; 100/min)</b>	77	96
<b>Pyrexia</b>	77	96
<b>Chest pain</b>	31	39
<b>Arthralgia</b>	13	16
<b>Epistaxis</b>	10	13
<b>Cardiothoracic ratio (N = 57)</b>		
≥ 0,6	53	93
< 0,6	4	7
<b>PR interval (N = 55)</b>		
> 0,20	30	55
< 0,20	25	45
<b>Cachexia</b>	34	42
<b>Emergency operation</b>	52	65

aggravated by pressure of the palm of the examiner's hand on the sternum. A pericardial rub may be heard in such cases and acute fibrinous pericarditis was confirmed at surgery in 24 of these 31 patients. Haemodynamically significant pericardial effusion has seldom been encountered in our experience of acute rheumatic carditis and was detected in none of the 80 patients. Cachexia was notable in 34 and may be extremely marked. Arthralgia or arthritis was infrequent (16%). Considerable cardiomegaly was readily apparent on clinical examination and was confirmed by a cardiothoracic ratio on chest radiography of 60% or more in most cases.

Regurgitation was invariably the predominant valvular lesion and almost always involved the mitral valve. Of the 80 patients, 72 had pure or predominant mitral regurgitation. Concomitant aortic regurgitation was present in 47 of the 80 patients, but marked aortic regurgitation as an isolated lesion, i.e. without detectable associated mitral valve involvement, was encountered in only 6 subjects. Dominant mitral stenosis occurred in 1 instance only in this series and there was no case of significant aortic stenosis. Associated tricuspid regurgitation was common and resulted from dilatation of the tricuspid annulus. This was confirmed at operation in 22 patients. The systolic murmur of tricuspid regurgitation due to annular dilatation is unimpressive or absent and the entity should be recognised clinically by prominent systolic waves in the jugular venous pressure and systolic pulsation of the enlarged liver. Tricuspid regurgitation with annular dilatation in the absence of tricuspid leaflet disease is generally described as 'functional' but we consider that rheumatic annular disease is a crucial factor in initiating or aggravating the tricuspid annular dilatation.<sup>10</sup> This is analogous to the functional anatomy of rheumatic mitral regurgitation, which will be discussed below.

### Pathogenesis and functional pathology of severe mitral regurgitation

Marcus *et al.*<sup>11</sup> from our institution recently published a detailed echocardiographic analysis of 73 patients, aged 7 - 27 years, with severe mitral regurgitation and active rheumatic carditis. All patients were later subjected to surgery where an independent qualitative assessment of mitral leaflets, the anulus and chordae tendineae was made. The results confirmed and

**TABLE II. CLINICAL, RADIOGRAPHIC AND HAEMODYNAMIC DATA (MEAN ± SD) AND OPERATIVE PROCEDURE IN 73 PATIENTS WITH SEVERE MITRAL REGURGITATION AND ACUTE RHEUMATIC CARDITIS**

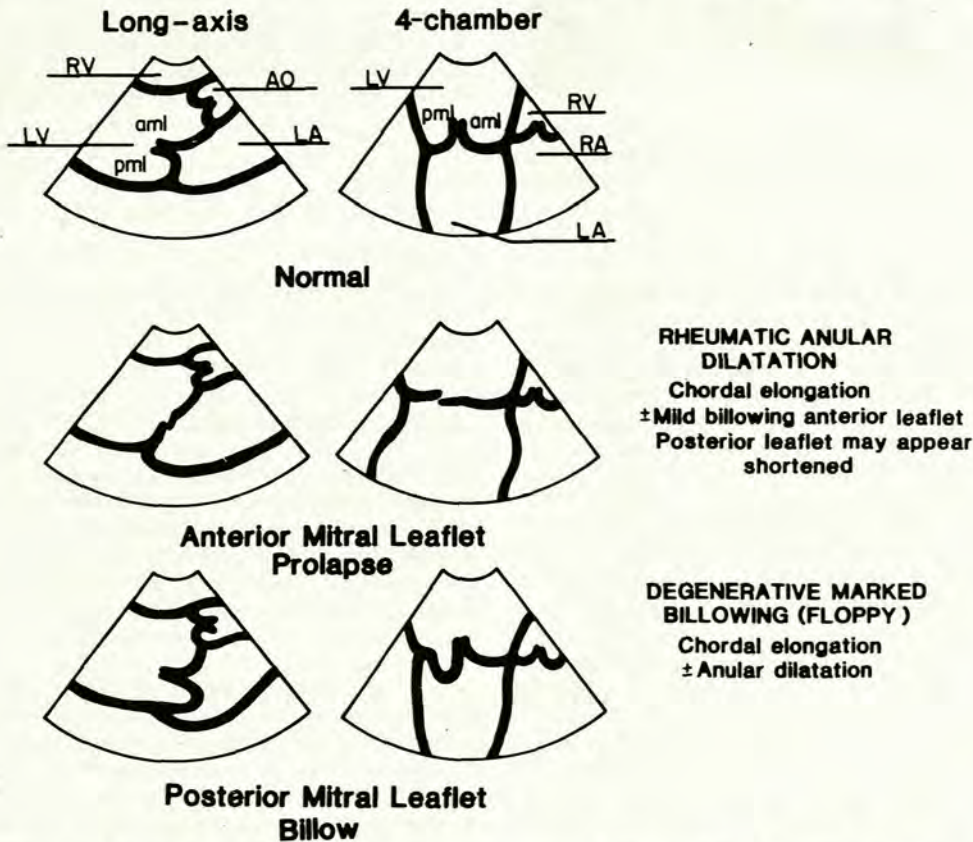
Age (yrs)	Sex		NYHA		Rhythm		CTR (%)	Pressures (mmHg)*			Procedure	
	M	F	Grade III	Grade IV	SR	AF		LA mean	LA'V'	LVED	MVR	Repair
13 ± 3	25	48	47	26	69	4	65 ± 7	25 ± 8	48 ± 17	16 ± 8	39 (16†)	34 (2†)

\* Recorded at operation.  
 † Concomitant aortic valve replacement for significant aortic regurgitation.  
 NYHA = New York Heart Association grade; CTR = cardiothoracic ratio; SR = sinus rhythm; AF = atrial fibrillation; LA = left atrial; LVED = left ventricular end-diastolic; MVR = mitral valve replacement.

clarified our concepts of the functional anatomy.<sup>9,12</sup> Relevant clinical, haemodynamic and other data are summarised in Table II.

The primary and predominant defect in active rheumatic carditis causing pure mitral regurgitation is dilatation of the posterior annulus<sup>9</sup> — the anterior annulus comprises dense fibrous tissue and is relatively fixed. Chordal lengthening and prolapse of the anterior leaflet supervene but are mainly secondary to the annular dilatation.<sup>9</sup> It is essential to emphasise that we define mitral valve prolapse as failure of leaflet coaptation resulting in displacement of an involved leaflet's edge toward the left atrium.<sup>11,13,14</sup> This definition of mitral valve prolapse is in accord with the morphological observations of pathologists<sup>15</sup> as well as those at operation of Carpentier *et al.*<sup>16</sup> and our own cardiac surgeons,<sup>17,18</sup> which are crucial in

assessment during a reconstructive procedure. The terms 'billowing', 'floppy' and 'flail' also require clarification in the context of correlating clinical evaluation with mitral valve functional anatomy.<sup>13,14</sup> 'Billowing', and in its more advanced form, 'floppy', are *anatomical* terms that describe the leaflet bodies. There is a gradation of mild billowing of the normal leaflet bodies towards the left atrium during ventricular systole to marked displacement when the leaflets are voluminous and the chordae elongated. A floppy mitral valve may remain functionally competent throughout systole. Prolapse, and its more advanced form, flail, reflect failure of leaflet edge apposition and therefore describe valve *function*. Two-dimensional (2-D) echocardiography is contributory in the evaluation of both the rheumatic and degenerative processes that may involve the complex mitral valve mechanism causing functional pro-



**Fig. 2. Schematic 2-D echocardiographic appearance during systole of normal, prolapsed (rheumatic) and markedly billowing or floppy (degenerative) mitral valves in the parasternal long axis and apical four-chamber views. In the normal valve the coaptation of the leaflets is readily apparent. In rheumatic mitral prolapse the annulus is significantly dilated and the free edge of the prolapsing anterior leaflet is displaced beyond the line of valve closure. The posterior leaflet appears shortened because it is stretched by the dilated annulus. In degenerative mitral billow the body of the posterior leaflet bulges into the left atrium (LA) but the leaflet margins usually appear coapted. Principal functional anatomical features are listed in the right column (AO = aorta; LV = left ventricle; pml = posterior mitral leaflet; aml = anterior mitral leaflet; RA = right atrium; RV = right ventricle).**

lapse and hence mitral regurgitation. However, the echocardiographic appearances are essentially different because functional anatomy is different (Fig. 2). The degenerative condition widely, and often inappropriately, called primary mitral valve 'prolapse' affects principally the leaflet bodies. Bulging of these leaflet bodies toward the left atrium during ventricular systole is readily demonstrated by 2-D echocardiography and ranges from a normal variant to pronounced floppiness.<sup>14</sup> On the other hand, redundancy and billowing of leaflet bodies are seldom features of rheumatic mitral regurgitation but 2-D echocardiography dramatically reflects the failure of leaflet edge apposition when the prolapse is severe (Fig. 3).

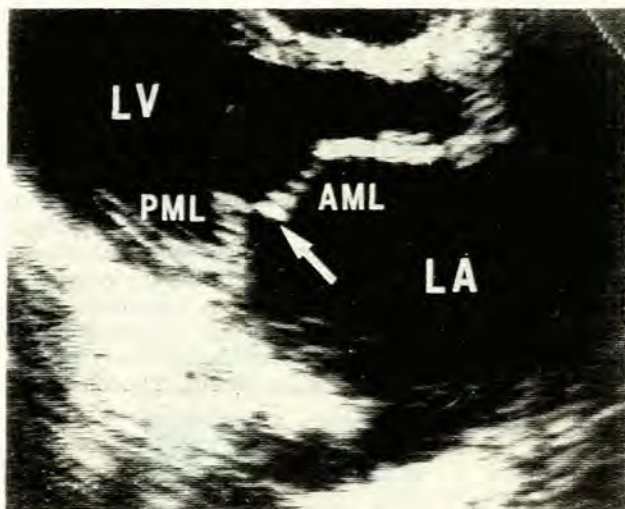


Fig. 3. Two-D echocardiogram, in the parasternal long axis view, showing (arrow) a severely prolapsed, or flail, anterior mitral leaflet (AML) in a 10-year-old patient with fulminant rheumatic carditis and severe mitral regurgitation.

Sixty-nine of the 73 patients (94%) studied by Marcus *et al.*<sup>11</sup> showed varying degrees of anterior mitral leaflet prolapse on 2-D echocardiography and this finding was confirmed at surgery. Dilatation of the mitral annulus was noted at operation in 70 patients, all but 2 of whom had demonstrable prolapse of the anterior mitral leaflet. Moreover, the mean external diameters of prosthetic valves ( $N = 39$ ) and Carpentier rings ( $N = 34$ ) inserted at the time of surgery were  $28 \pm 2$  mm and  $32 \pm 2$  mm, respectively, disproportionately large for the young age (mean 13 years) of the patients studied.<sup>11</sup> The maximal diameter of the mitral annulus was measured on 2-D echocardiography in 12 patients and was significantly greater ( $P < 0,0001$ ) than that obtained for 10 control subjects matched for age, mass and body surface area ( $37 \pm 4$  mm v.  $23 \pm 1,9$  mm). In 6 patients in whom precise measurements of annular circumference were made at surgery, the derived mean annular diameter of  $36 \pm 3$  mm was similar to that independently evaluated on 2-D echocardiography. Considerable elongation of the marginal ('strut') chordae tendineae attaching to the anterior mitral leaflet, associated with prolapse of the leaflet, was observed at operation in 66 of the 73 patients. Thirty-three of the 34 patients who underwent mitral valve repair required shortening of chordae to the anterior mitral leaflet. Posterior leaflet chordal elongation was uncommon, and was present in only 3 patients. Anterior leaflet chordal rupture was detected in 5 patients, and was invariably accompanied by elongation of intact chordae to that leaflet, dilatation of the annulus and mitral valve prolapse. The mean maximal systolic chordal length measured by pre-operative 2-D echocardiography in 6 patients was significantly greater ( $P < 0,01$ ) than that of 5 age-matched control subjects ( $23 \pm 4$  mm v.  $17 \pm 1$

mm). The mean intra-operative value for chordal length in these 6 patients was  $23 \pm 3$  mm, similar to that measured by 2-D echocardiography.

Although chordal elongation may relate in part to rheumatic inflammatory involvement, exposure of the chordae to enhanced tensile stresses during ventricular systole is probably the predominant factor. The rise in chordal tension in the normal mitral valve during ventricular systole is attenuated by the 'keystone mechanism' whereby the pressure generated by left ventricular contraction is applied against opposite sides of the apposing mitral leaflets, forming a competent seal.<sup>19,20</sup> A normal valve leaflet:annular area ratio is essential for this mechanism to operate optimally.<sup>21</sup> After posterior annular dilatation and functional retraction of the stretched posterior leaflet (Fig. 2), the area of apposition of the valve leaflets is reduced, diminishing the keystone effect with resultant increase in chordal tension. The chordae stretch or rupture, the anatomically relatively normal anterior leaflet prolapses and mitral regurgitation supervenes. Consequent upon the mitral regurgitation, the left atrium enlarges, which allows further dilatation of the posterior annulus<sup>22</sup> and thus perpetuates a vicious cycle.<sup>9,18</sup> Scarring of the valve leaflets and commissural fusion were infrequent (16 of 73 patients) and mild.

The devastating clinical consequences of this cascade of events continue to manifest themselves in underdeveloped countries where rheumatic carditis remains a major cause of morbidity and mortality.<sup>2,9,23</sup> The fact that such patients invariably show evidence on histological examination of chronic rheumatic activity in addition to active carditis suggests that the severe haemodynamic lesion is seldom the result of a single attack, but rather of repeated episodes.<sup>11</sup> Reasons for such recurrences are environmental but include the potentially avoidable contributory factors of inadequate penicillin prophylaxis<sup>24</sup> and ongoing physical activity,<sup>9,11</sup> both of which are discussed later.

## Heart failure

We emphasise that left or right ventricular failure does not result from active rheumatic carditis in the absence of a haemodynamically severe valvular lesion. We are uncertain of the cause or the role of the myocardial component referred to by Stollerman<sup>25</sup> as 'toxic rheumatic myocarditis' but reiterate that, unlike viral myocarditis, it never by itself causes ventricular dilatation or heart failure.<sup>9</sup> By far the most prevalent valve lesion encountered in patients in heart failure with active rheumatic carditis is mitral regurgitation. When depressed left ventricular function is associated (Fig. 4), we are uncertain whether this reflects 'rheumatic myocarditis' or is a consequence of work overload produced by the severe regurgitation.<sup>9</sup> Evaluation of the 'myocardial factor' in active rheumatic carditis requires clarification and is a subject of ongoing study in our department.

Because 'heart failure' associated with fulminant active rheumatic carditis results principally or entirely from a haemodynamically severe valve lesion, usually mitral regurgitation, the term is difficult to define in this context. A practical definition based on clinical evaluation would be 'an inadequate circulation at rest together with a raised pulmonary venous pressure, with or without high systemic venous pressure, in the absence of haemodynamically important tricuspid valve disease or pericardial effusion'. Although this definition may be imprecise in not clarifying 'inadequate circulation', a raised left ventricular end-diastolic pressure was encountered in most patients in whom pressures were recorded, whether at cardiac catheterisation or during operation (Table II). Medical management of such cases is of limited value but requires brief consideration:

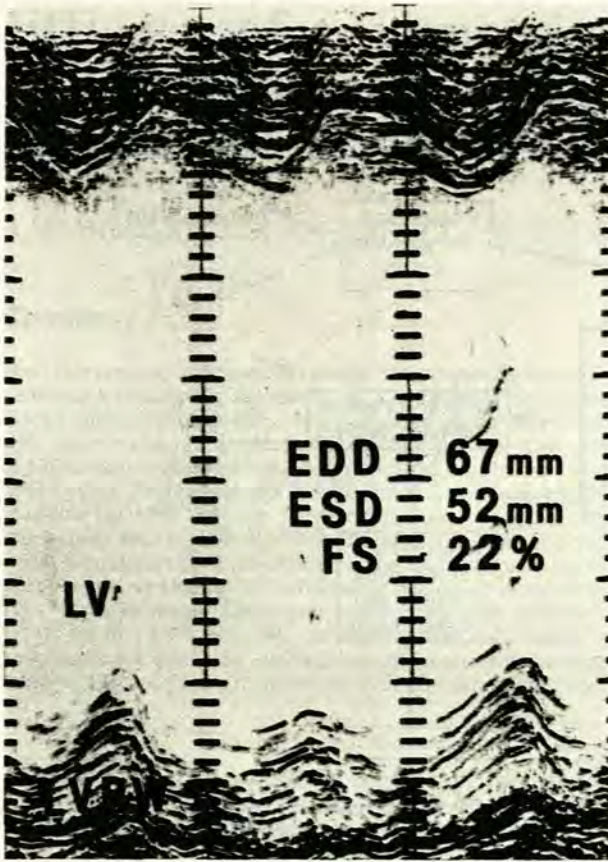


Fig. 4. M-mode echocardiogram demonstrating a dilated left ventricular (LV) cavity with poor contraction in a patient with severe rheumatic mitral regurgitation (EDD = end-diastolic diameter; ESD = end-systolic diameter; FS = fractional shortening).

**Antibiotic therapy.** This is mandatory and we use intramuscular benzathine penicillin G in a dose of 1,2 million units (600 000 U for children weighing < 30 kg) administered at 3 - 4 week intervals or oral penicillin in a dose of at least 250 mg twice daily.

**Salicylate, steroid and other medical therapy.** Salicylates are recommended for symptomatic relief of arthralgia, arthritis or severe pericardial pain. Contrary to the conclusions of Czonicz et al.,<sup>26</sup> and which became accepted doctrine,<sup>27,28</sup> steroids are never a 'life-saving' measure in patients who have severe active rheumatic carditis with heart failure. Steroids may make the tissues more friable and the task of the surgeon more difficult. We have indeed encountered patients with fulminating rheumatic carditis and severe regurgitant valve lesions who have been treated with steroids,<sup>9</sup> but have yet to observe improvement of the heart failure on such therapy!

We seldom use digitalis unless atrial fibrillation is present (5% of patients<sup>11</sup>). Diuretic and vasodilator therapy, including angiotensin-converting enzyme inhibitors, cause temporary symptomatic improvement, mainly by decreasing pulmonary venous pressure, but clinical evidence of rheumatic activity and of heart failure invariably persist.

### Aspects of prevention and progression of active fulminant rheumatic carditis with mitral regurgitation

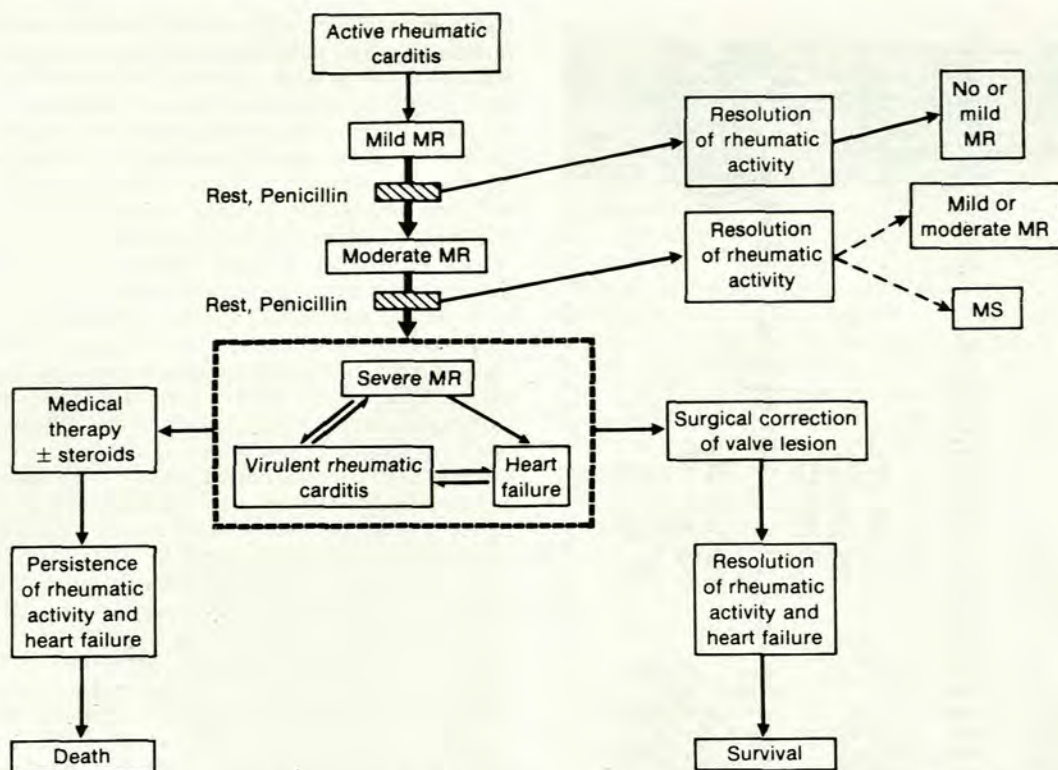
It is relevant to discuss the early course of active rheumatic carditis and our concept of its progression with inappropriate

management (Fig. 5). A first or early attack of active rheumatic carditis may cause mild mitral regurgitation, which we suggest is due to failure of normal annular contraction<sup>29</sup> and for which we originally used the term 'annular dysfunction'.<sup>30</sup> Provided the patient is now sedentary and penicillin is administered, the rheumatic activity should abate and the mitral regurgitation diminish or disappear.<sup>9,31,32</sup> If the patient continues to exercise and does not receive penicillin, rheumatic activity will be ongoing and moderate mitral regurgitation will ensue. Even at this stage, rest and penicillin therapy should eliminate the rheumatic activity and reduce the mitral regurgitation. Whereas it is possible that steroid therapy would now contribute to regression of rheumatic activity, this has never been well substantiated. It is highly likely, however, that many of these patients subsequently develop scarring of leaflets and commissures with resultant mitral stenosis. When patients with moderate mitral regurgitation and active carditis are still not treated with penicillin, the rheumatic process will continue or recur and severe mitral regurgitation will supervene. This formidable haemodynamic overload seems to aggravate the rheumatic activity and may initiate virulent rheumatic carditis.<sup>9</sup> A vicious cycle is now established and heart failure results. The sole effective management of such patients is surgical. Neither the rheumatic activity nor the cardiac failure will respond satisfactorily to any medical therapy. Surgery should not be delayed<sup>33</sup> and, in our experience,<sup>9,18,34</sup> at least 90% of patients survive surgery. The rheumatic activity abates dramatically during the first few weeks of the postoperative period. We conclude that a principal factor predisposing to this postoperative resolution of rheumatic activity is the removal of the cardiac workload by correction of the valve lesion. This concept is in accord with the observations<sup>35,36</sup> made before the antibiotic era that manifestations of acute rheumatic fever recede more rapidly with bed-rest. The excessive workload on the heart of a patient with severe rheumatic mitral regurgitation produces a situation analogous to that of a child with active carditis and a mild valve lesion being forced to exercise continuously.

Socio-economic factors will continue in the foreseeable future to cause rheumatic heart disease in this and other Third-World countries. The cost of therapy is immense and economic factors will surely limit optimal management. Based on clinical, surgical and epidemiological observations made over three decades and the recent precise echocardiographic and intra-operative measurements, we have attempted in this article to review and clarify the ongoing problem of rheumatic heart disease in this environment.

### REFERENCES

1. Padmavati S. Rheumatic fever and rheumatic heart disease in developing countries. *Bull WHO* 1978; 56: 543-550.
2. McLaren MJ, Hawkins DM, Koornhof HJ et al. Epidemiology of rheumatic heart disease in black schoolchildren of Soweto, Johannesburg. *Br Med J* 1975; 3: 474-478.
3. Glover JA. Incidence of rheumatic diseases. *Lancet* 1930; 1: 499-505.
4. Devaux P. Some aspects of rheumatic fever in Soweto. *The Leech* 1979; 49: 67-68.
5. Ransome OJ, Roode H, Spector I, Reinach SG. Pharyngeal carriage of group A beta-haemolytic streptococci in Coloured and Indian schoolchildren. *S Afr Med J* 1983; 64: 779-781.
6. Aryanpur-Kashani I. On rheumatic fever in children (Correspondence). *Am Heart J* 1980; 100: 942-943.
7. Veasy LG, Wiedmeier SE, Orsmond GS et al. Resurgence of acute rheumatic fever in the intermountain area of the United States. *N Engl J Med* 1987; 316: 421-427.
8. Kaplan EL, Markowitz M. The fall and rise of rheumatic fever in the United States: a commentary. *Int J Cardiol* 1988; 21: 3-10.
9. Barlow JB, Kinsley RH, Pocock WA. Rheumatic fever and rheumatic heart disease. In: Barlow JB. *Perspectives on the Mitral Valve*. Philadelphia: FA Davis, 1987: 227-245.
10. Barlow JB, Pocock WA, Antunes MJ, Sareli P, Meyer TE. Surgical aspects of mitral valve disease. In: Barlow JB. *Perspectives on the Mitral Valve*. Philadelphia: FA Davis, 1987: 281-282.
11. Marcus RH, Sareli P, Pocock WA et al. Functional anatomy of severe mitral regurgitation in active rheumatic carditis. *Am J Cardiol* 1989; 63: 577-584.
12. Marcus R, Sareli P, Antunes M et al. Functional pathology of mitral regurgitation in active rheumatic carditis — surgical and echocardiographic observations (Abstract). *J Am Coll Cardiol* 1986; 7: 8A.



**Fig. 5. Flow chart showing progression of untreated mild rheumatic mitral regurgitation to virulent carditis, severe regurgitation and heart failure. Alternate pathways to death (medical therapy only) or survival with resolution of rheumatic activity (surgical correction of valve lesion) are illustrated. Appropriate treatment with penicillin and physical rest at an early stage, together with long-term penicillin prophylaxis, avoid this disastrous sequence (for details see text).**

13. Barlow JB, Pocock WA. Billowing, floppy, prolapsed or flail mitral valves? *Am J Cardiol* 1985; **55**: 501-502.
14. Barlow JB, Pocock WA. Mitral valve billowing and prolapse: perspective at 25 years. *Herz* 1988; **13**: 227-234.
15. Becker AE, De Wit APM. Mitral valve apparatus: a spectrum of normality relevant to mitral valve prolapse. *Br Heart J* 1979; **42**: 680-689.
16. Carpentier A, Lessana A, D'Allaines C, Blondeau P, Piwnica A, Dubost C. Reconstructive surgery of mitral valve incompetence. *J Thor Cardiovasc Surg* 1980; **79**: 338-348.
17. Antunes MJ, Magalhaes MP, Colsen PR, Kinsley RH. Valvuloplasty for rheumatic mitral valve disease. A surgical challenge. *J Thorac Cardiovasc Surg* 1987; **94**: 44-56.
18. Kinsley RH, Girdwood RW, Milner S. Surgical treatment during the acute phase of rheumatic carditis. *Surg Annu* 1981; **13**: 299-323.
19. Salisbury PF, Cross CE, Rieben P. Chorda tendineae tension. *Am J Physiol* 1963; **205**: 385-392.
20. Cobbs BW. Clinical recognition and medical management of rheumatic heart disease and other acquired valvular disease. In: Hurst JW, Logue RB, Schlant RC, Wenger NK, eds. *The Heart*. New York: McGraw-Hill, 1974: 862.
21. Brock RC. The surgical and pathologic anatomy of the mitral valve. *Br Heart J* 1952; **14**: 489-513.
22. Levy MJ, Edwards JE. Anatomy of mitral insufficiency. *Prog Cardiovasc Dis* 1962; **5**: 119-144.
23. Agarwal BL. Rheumatic heart disease unabated in developing countries. *Lancet* 1981; **1**: 910-911.
24. Dajani AS, Bisno AL, Chung KJ *et al*. Prevention of rheumatic fever: a statement for health professionals by the Committee on Rheumatic Fever, Endocarditis, and Kawasaki Disease of the Council on Cardiovascular Disease in the Young of the American Heart Association. *Circulation* 1988; **78**: 1082-1086.
25. Stollerman GH. *Rheumatic Fever and Streptococcal Infection*. New York: Grune & Stratton, 1975: 127-131.
26. Czoniczer G, Amezcua F, Pelargonio S, Massell BF. Therapy of severe rheumatic carditis: comparison of adrenocortical steroids and aspirin. *Circulation* 1964; **29**: 813-819.
27. Sukumar IP. Acute and chronic rheumatic heart disease. In: Anderson RH, Macartney FJ, Shinebourne EA, Tynan M, eds. *Paediatric Cardiology*. Edinburgh: Churchill Livingstone, 1987: 1193.
28. Bland EF. Rheumatic fever: the way it was. *Circulation* 1987; **76**: 1190-1195.
29. Barlow JB, Antunes MJ. Functional anatomy of the mitral valve. In: Barlow JB. *Perspectives on the Mitral Valve*. Philadelphia: FA Davis, 1987: 11-12.
30. Barlow JB, Pocock WA. The problem of non-ejection systolic clicks and associated mitral systolic murmurs: emphasis on the billowing mitral leaflet syndrome. *Am Heart J* 1975; **90**: 636.
31. Tompkins DG, Boxerbaum B, Liebman J. Long-term prognosis of rheumatic fever patients receiving regular intramuscular benzathine penicillin. *Circulation* 1972; **45**: 543-551.
32. Sanyal SK, Berry AM, Duggal S, Hooja V, Ghosh S. Sequelae of the initial attack of acute rheumatic fever in children from North India: a prospective 5-year follow-up study. *Circulation* 1982; **65**: 375-379.
33. Lewis BS, Geft IL, Milo S, Gotsman MS. Echocardiography and valve replacement in the critically ill patient with acute rheumatic carditis. *Ann Thorac Surg* 1979; **27**: 529-535.
34. Magalhaes M, Antunes M, Marcus R *et al*. The role of surgery in acute rheumatic valvulitis — a 2-year experience of 70 cases (Abstract). Xth World Congress of Cardiology, Washington, DC, 1986: 115.
35. Miller R. Rheumatic heart disease in children. In: Rolleston H, ed. *The British Encyclopaedia of Medical Practice*. Vol. 6. London: Butterworth, 1937: 250.
36. Bywaters EGL. The general management of rheumatic fever. *Proc R Soc Med* 1950; **43**: 199-206.