

# Giant lower oesophageal ulcer in a Bushman baby

## A case report

J. J. HEYDENRYCH, A. D. KEET

### Summary

The case of a giant, penetrating lower oesophageal ulcer in a 14-month-old Bushman baby is reported. This would probably be classified as a Barrett's ulcer. Histological examination showed that the ulcer developed in columnar epithelium and that there was normal stratified squamous oesophageal mucosa both proximally and distally to the ulcer, indicating that it had developed in an islet of ectopic gastric mucosa. The ulcer originally described by Barrett developed in a short oesophagus, into which gastric mucosa extended in a continuous sheet. Lower oesophageal ulcers should probably be divided into a primary type, of which the present case is an example, and a secondary type, in which there is direct extension of gastric mucosa into the oesophagus due to metaplasia of oesophageal mucosa secondary to reflux oesophagitis.

*S Afr Med J* 1983; 63: 331-333.

The normal oesophagus is lined by stratified squamous epithelium. Columnar gastric mucosa may rarely appear in the oesophagus as true ectopic islands, or more commonly as a direct extension in a continuous sheet from the gastric fornix.

Schridde<sup>1</sup> found that ectopic islets of gastric mucosa were usually microscopic in size and practically always occurred in the postericoid region. Rector and Connerley<sup>2</sup> reviewed the literature in 1941 and reported their own findings in 1 000 consecutive autopsies performed on infants and children ranging in age from prematurity to 14 years. Ectopic islands of gastric mucosa were found in the oesophagus in 7,8% of their cases.

A case in which the normal epithelium of the lower part of the oesophagus was replaced by a continuous sheet of gastric mucosa, extending upwards from the stomach, was described by Barrett<sup>3</sup> in 1950. The condition has since become known as Barrett's oesophagus. An ulcer was present in the original case, and it has become customary to call lower oesophageal ulcers Barrett's ulcers. Barrett originally described the intrathoracic viscus lined with gastric mucous membrane as stomach, even though from the outside it looked like oesophagus. He believed that a congenitally short oesophagus was present, and that part of

the stomach had been drawn upwards through the diaphragmatic hiatus to resemble the oesophagus. The condition was not properly understood until 1953 when Allison and Johnstone<sup>4</sup> reported 7 similar cases, and identified the columnar epithelium-lined intrathoracic segment as oesophagus. It was found that a variable amount of the oesophagus below the aortic arch might be lined by gastric mucosa of the cardiac type, in continuity with the actual stomach mucosa. In all their cases it was associated with herniation of the true stomach through the diaphragmatic hiatus, with resultant reflux oesophagitis.

At present it is widely accepted that upward extension of gastric mucosa is due to metaplasia of oesophageal epithelium, secondary to reflux oesophagitis.<sup>5,6</sup> However, congenital ectopic islands of gastric mucosa of the type described by Rector and Connerley<sup>2</sup> are unrelated to reflux oesophagitis.<sup>6</sup>

Of clinical significance is the fact that gastric mucosa in the oesophagus is prone to ulceration, haemorrhage, perforation and stricture, while in rare cases, in adults, an adenocarcinoma of the oesophagus may form.<sup>4,7</sup> In infants and children, however, in our experience complications due to gastric mucosa in the oesophagus are rarely encountered. The present case is an example of such a condition, and is unusual in several respects: the history suggested that the disease had been present since birth; histological examination showed that the oesophageal ulcer had not developed in gastric mucosa which had extended upwards in a continuous sheet from the stomach, but in an island of ectopic gastric epithelium; quite unlike the case described by Barrett, the ulcer had burrowed through the wall of the oesophagus and penetrated deeply into the parenchyma of the left lobe of the liver. Lastly, we are not aware of similar reports in babies of this ethnic group.

### Case report

On 5 November 1979 a 14-month-old baby of the Namibian Bushman tribe was referred from South West Africa to our clinic with a history of haematemesis and melaena on several occasions during the previous week. Because the parents are illiterate they could not accurately indicate the age of the baby, but reliable informants confirmed that it was 'just over a year old'.

When first seen by his doctor the patient's abdomen appeared distended and on rectal examination dark faeces was visible on the glove. His haemoglobin concentration was 3,1 g/dl.

On admission the infant appeared to be in pain and incessant crying precluded a thorough systematic examination. Food was immediately rejected. On general examination there were no signs of cyanosis, jaundice, lymphadenopathy, hepatosplenomegaly or other organomegaly. Oral candidiasis was present.

Clinically he was grossly anaemic, as subsequently confirmed by a full haematological examination. Crepitations and rhonchi were heard at both lung bases posteriorly, but the cardiovascular system was normal. He weighed 6,3 kg; examination of the skin and subcutaneous tissue indicated that he had lost a great deal of body mass, compatible with 10 - 15% dehydration. Special inves-

Departments of Paediatric Surgery and Radiology, University of Stellenbosch and Tygerberg Hospital, Parowvallei, CP

J. J. HEYDENRYCH, M.Sc., M.MED. (SURG.), *Principal Paediatric Surgeon*

A. D. KEET, M.D., PH.D., *Principal Radiologist*

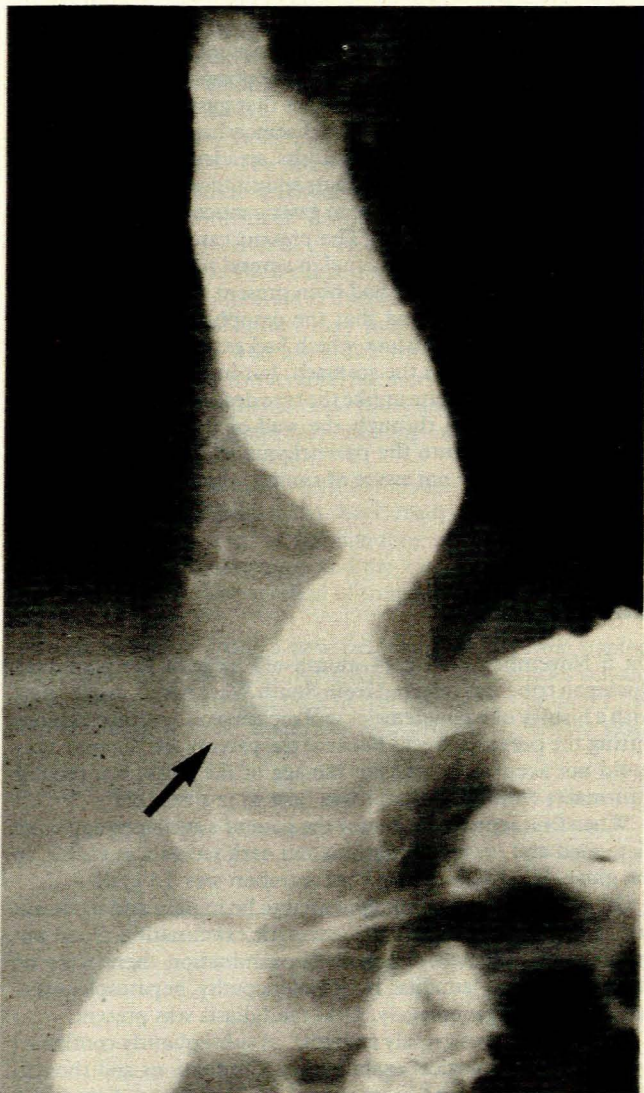
Date received: 30 March 1982.



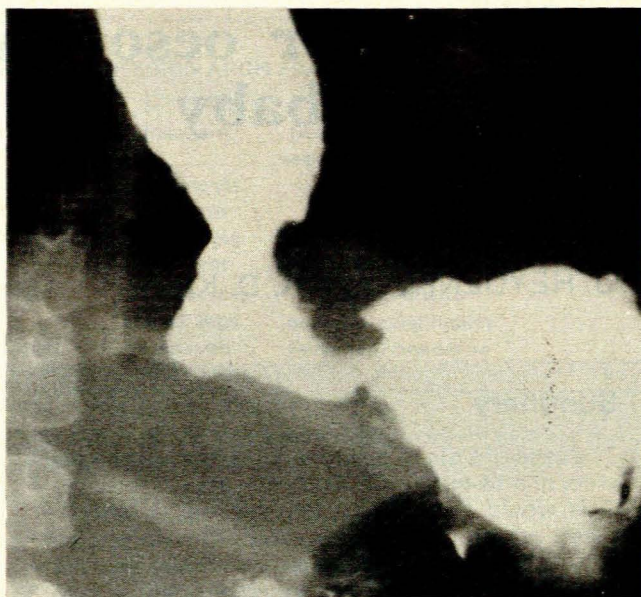
tigations were essentially negative except for a pH of 7,43, hypochloraemia (86 mEq/l) and a haemoglobin reading of 7,1 g/dl.

The baby responded to oral sedatives, parenteral rehydration, antacids and nystatin suspension for the oral thrush. However, attempts at oral feeding were unsuccessful and it became evident that swallowing of food was painful; repeated regurgitation of food signified that the oesophagus was partly occluded.

A barium swallow examination on 13 November 1979 showed a large ulcer, 2 - 3 cm in diameter, in the lower part of the oesophagus just above the diaphragm (Figs 1 and 2). Proximally to the lesion the oesophagus was dilated, showing a constant irregularity of the walls with absence of primary and secondary peristaltic waves. There was a delay in the passage of barium. No inco-ordinated contractions were seen. The segment of the oesophagus distally to the lesion, approximately 5 mm in length, where it passed through the diaphragmatic hiatus to join the stomach, appeared to be smooth and regular and showed normal longitudinal oesophageal mucosal folds. Because of the delay in emptying of the oesophagus and the presence of barium in the ulcer, it was difficult to establish whether or not gastro-oesophageal reflux was present. The stomach and duodenum showed no abnormality. The appearances were interpreted as a



**Fig. 1.** Large lower oesophageal ulcer (arrowed) immediately above the diaphragm. The oesophagus above the lesion is dilated and devoid of peristalsis.



**Fig. 2.** Detailed view of ulcer. The short terminal oesophageal segment, between the ulcer and gastric fundus, appears to be uninvolved.

large ulcer in the lower oesophagus, with motility disturbance, retention and oesophagitis above the lesion.

On 19 November endoscopic examination showed a huge ulcer in the distal oesophagus. Several biopsy specimens were obtained from the proximal edge for histological examination. The pathologist's report stated that these consisted of gastric columnar mucosa, with concomitant chronic inflammatory infiltration.

A repeat barium study after 3½ months showed no improvement, and on this occasion gastro-oesophageal reflux was observed in addition to the features mentioned previously. There was also a contracted prepyloric segment ('pseudohypertrophic pyloric stenosis'). Surgical intervention was clearly indicated.

### Surgical treatment

A high midline incision was made, incorporating and splitting the xiphisternum with a needle-tip diathermy probe.

The gastro-oesophageal junction could not be identified as the ulcer had penetrated deeply into the left lobe of the liver and caused excessive fibrosis. To identify the gastro-oesophageal junction the segment of the left lobe of the liver harbouring the ulcer was resected, and the intrahiatal segment of the oesophagus was mobilized, drawn downwards and transected proximally to the ulcer.

From this area full-thickness specimens were obtained for histological examination and found to consist of normal oesophageal stratified squamous epithelium. The ulcerated segment together with 1,25 cm of proximal stomach was resected in one block. Biopsy of the segment between the ulcer and the stomach showed normal stratified squamous oesophageal mucosa. The transected oesophagus was anastomosed to the proximal stomach with interrupted 4/0 Dexon suture material followed by a Nissen fundoplication. Because of fibrosis the vagi could not be identified. A simultaneous pyloroplasty was performed.

The procedure was well tolerated and the postoperative course was uneventful.

### Discussion

Barrett<sup>3</sup> originally stated that most cases of peptic ulcer of the oesophagus were in truth examples of congenital short oesopha-



gus, in which part of the stomach was drawn upwards even as high as the neck. He stressed the fact that 'accurate surgery must rest upon accurate pathology'. In order to comply with this request, adequate full-thickness specimens were taken at operation from the wall of the ulcer, the segment proximal to the ulcer, and the segment interposed between the ulcer and the gastro-oesophageal junction. The histological examination showed that the ulcer had not developed in a congenitally short oesophagus, as normal oesophageal mucosa was seen proximally as well as distally to the ulcer, but in an islet of ectopic columnar mucosa (the original biopsy findings of columnar mucosa were confirmed in the resected ulcer). These findings are at variance with Barrett's statement that chronic peptic ulcer 'has never been shown to have commenced in an island of ectopic mucosa anywhere in the oesophagus'. It appears that in the present case the opposite is true, namely that the ulcer had developed in an island of ectopic columnar mucosa of the type described by Schridde<sup>1</sup> and later by Rector and Connerley.<sup>2</sup>

More than one type of aberrant cell was found in some of the cases of Rector and Connerley,<sup>2</sup> and in many cases there was concomitant chronic inflammatory infiltration. However, they did not demonstrate any gastric parietal cells in the lower oesophagus in their cases. Naef and Savary,<sup>8</sup> referring to those cases of 'Barrett's oesophagus' in which a continuous sheet of gastric mucosa extended upwards, suggested that two types should be recognized. In type I the squamo-columnar junction was linear and situated at the level of the aortic arch. It occurred with greatest frequency in childhood up to the age of 15 years, and was probably a congenital condition. In type II the junction was irregular, generally lower than the aortic arch, and scattered islands of squamous epithelium were sometimes observed in the ectopic mucosa. It occurred in patients over the age of 55 years, and in their opinion was an acquired heterotopia, due to metaplasia secondary to gastro-oesophageal reflux and peptic oesophagitis. In a series of 62 patients with columnar epithelium-lined lower oesophagus, they were able to demonstrate reflux constantly. In 59 of these cases hiatus hernia was present, while 9 patients in addition had an adenocarcinoma and 4 a Barrett's ulcer. The heterotopic columnar epithelium consisted of mucus-secreting cells and did not contain any acid-secreting parietal cells.

According to Mangla *et al.*<sup>9</sup> the most constant cellular elements in columnar-lined oesophagus were tall columnar cells, goblet cells and a small number of argentaffin cells. Parietal and chief cells were infrequent. It was shown that the aberrant mucosa might secrete pepsin and might contain gastrin. Paull *et al.*<sup>10</sup> found three types of epithelium in the aberrant mucosa, namely a gastric fundic type containing parietal and chief cells, a

junctional type consisting of cardiac mucous cells, and a specialized columnar type. In the present case we could not demonstrate a similar spectrum of abnormal cells, as all the ectopic cells were of the same columnar type.

It seems to us that the condition in which gastric columnar cells occur in the lower oesophagus should be divided into primary and secondary types. The primary type is congenital, and may consist of scattered islets of ectopic columnar mucosa (as in the present case) or of a sheet of columnar mucosa in continuity with that in the stomach (as in type I of Naef and Savary<sup>8</sup>). In the secondary type a sheet of columnar mucosa extends upwards from the stomach, due to metaplasia of oesophageal mucosa secondary to gastro-oesophageal reflux and peptic oesophagitis (i.e. type II of Naef and Savary<sup>8</sup>).

As the vast majority of cases of columnar-lined lower oesophagus are of the secondary type, it is logical to conclude that the treatment should be directed towards preventing gastro-oesophageal reflux and peptic oesophagitis. Naef and Savary<sup>8</sup> advocated Nissen fundoplication as the treatment of choice. Mangla *et al.*<sup>9</sup> found medical treatment ineffective in all their cases, but satisfactory results were obtained with Nissen fundoplication. Regression of the columnar-lined epithelium towards the cardia has been reported after successful antireflux surgery by Brand *et al.*<sup>11</sup>

In our patient the circumstances were quite different and a resection was indicated, followed by a Nissen fundoplication.

#### REFERENCES

- Schridde H. Ueber Magenschleimhaut-Inseln vom Bau der Kardialdrüsenzzone und Fundusdrüsenzregion und den unteren, oesophagealen Kardialdrüsen gleichende Drüsen im obersten Oesophagusabschnitt. *Virchow's Arch (Pathol Anat)* 1904; **175**: 1-16.
- Rector LE, Connerley ML. Aberrant mucosa in the esophagus in infants and children. *Arch Pathol* 1941; **31**: 285-294.
- Barrett NR. Chronic peptic ulcer of the oesophagus. *Br J Surg* 1950; **38**: 175-182.
- Allison PR, Johnstone AS. The oesophagus lined with gastric mucous membrane. *Thorax* 1953; **8**: 87-101.
- Mossberg SM. The columnar-lined esophagus (Barrett syndrome): an acquired condition? *Gastroenterology* 1966; **50**: 671-676.
- Thompson H. Tissue reactions in disease. In: Sircus W, Smith AN, eds. *Scientific Foundations in Gastroenterology*. London: Heinemann, 1980: 259-260.
- Cho KJ, Hunter TB, Whitehouse WM. The columnar epithelial-lined lower esophagus and its association with adenocarcinoma of the esophagus. *Radiology* 1975; **115**: 563-568.
- Naef AP, Savary M. Conservative operations for peptic esophagitis with stenosis in columnar lined lower esophagus. *Ann Thorac Surg* 1972; **13**: 543-551.
- Mangla JC, Schenk EA, Desbaillets L, Guarasci G, Kubasik NP, Turner MD. Pepsin secretion, pepsinogen and gastrin in 'Barrett's esophagus'. *Gastroenterology* 1976; **70**: 669-676.
- Paull A, Trier J, Dalton D, Camp RC, Loeb P, Goyal RK. The histologic spectrum in Barrett's esophagus. *N Engl J Med* 1976; **295**: 476-480.
- Brand DL, Ylvisaker JT, Gelfand M, Pope CE. Regression of columnar esophageal (Barrett's) epithelium after anti-reflux surgery. *N Engl J Med* 1980; **302**: 844-848.