

Anomalous left coronary artery from the pulmonary artery — a therapeutic dilemma

A report on 12 cases

K. C. HOUSEHAM, D. G. HUMAN, C. B. FRASER, H. S. JOFFE

Summary

An anomalous left coronary artery from the pulmonary artery was diagnosed clinically in 12 patients (and confirmed angiographically in 11 and at autopsy in 1). A classic history of 'infantile angina' was obtained in only 1 patient, while the typical electrocardiographic findings of anterolateral ischaemia or infarction were present in 11 patients (92%). The majority had evidence of left ventricular dysfunction and mitral regurgitation.

Three patients underwent surgical reimplantation of the anomalous left coronary artery into the ascending aorta. Two survive, but with persistent electrocardiographic changes and cardiomegaly. Nine patients, of whom 4 survive, were managed

medically. Five of the 6 deaths occurred within 1 month of diagnosis.

A conservative approach to surgical intervention is recommended, as surgery is unlikely to alter the ultimate prognosis.

S Afr Med J 1983; 63: 325-327.

Anomalous origin of the left coronary artery from the pulmonary artery is an unusual congenital anomaly found in 1/300 000 children in the general population.¹ The condition carries a grave prognosis with high mortality, especially in the first year of life, mortality rates of up to 85% being reported.²⁻⁴

The dilemma of whom to recommend for surgery and when led us to review our experience of this anomaly over the past 10 years. During this period (1970-1979) 12 cases were identified and details of these together with a review of aspects of the published data are presented.

Patients

There were 9 females and 3 males. In 11 the clinical diagnosis was confirmed angiographically, while in the remaining infant it was confirmed at autopsy. Age at presentation ranged from 5 weeks to 20 months (mean 10 months) excluding a child with a

Cardiology Unit, Department of Paediatrics and Child Health, University of Cape Town and Red Cross War Memorial Children's Hospital, Cape Town

K. C. HOUSEHAM, M.B. CH.B., F.C.P. (S.A.)

D. G. HUMAN, B.M. B.CH., M.R.C.P.

C. B. FRASER, M.B. CH.B., M.R.C.P., D.C.H.

H. S. JOFFE, M.D., M.MED. (PAED.)

Based on a paper delivered at the 12th Biennial Congress of the Southern Africa Cardiac Society, Johannesburg, 4-6 August 1980.

coincidental ventricular septal defect who was seen at 4 years, after surgical closure of the septal defect. The presentation in this last case was delayed because pulmonary hypertension allowed adequate perfusion via the anomalous vessel.

Clinical data

Reviewing the clinical data (Fig. 1) we found the classic history of infantile angina as described by Bland *et al.*⁵ in only 1 patient. Two patients had a nonspecific history of respiratory distress, failure to thrive or difficulty with feeding.




Fig. 1. Clinical data in 12 patients.

Features of congestive cardiac failure were present in 11 patients and significant clinical mitral regurgitation was noted in 6. No patient had a continuous murmur. The typical electrocardiographic findings of anterolateral infarction or ischaemia were present in 11 patients. Cardiomegaly (cardiothoracic ratio > 60%) was an invariable finding. The child with a ventricular septal defect developed the typical electrocardiographic changes after surgical closure of the defect.

Angiographic data

Angiographic data were available in 11 patients (Fig. 2), and the diagnosis was made in 9 at the initial study. Left ventricular dyskinesia (10 cases) and mitral regurgitation (8 cases) were common findings. The pulmonary wedge pressure was elevated in 8 cases (mean > 12 mmHg). Associated defects were a single atrial septal defect, and one ventricular septal defect. A left-to-right shunt from aorta to pulmonary artery was present in 4 patients, but was only regarded as significant (i.e. > 15%) in 2.

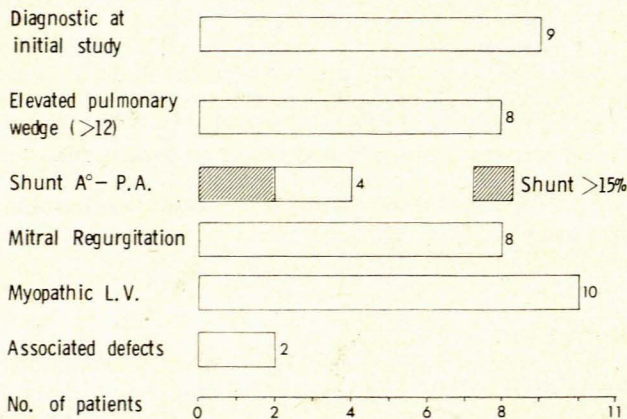


Fig. 2. Angiographic data in 11 patients.

Echocardiography in 5 patients revealed a significant degree of left ventricular dysfunction in all. The mean percentage shortening fraction was 22%. There was no significant difference in the shortening fraction between the medical and surgical groups.

Course and management (Fig. 3)

Three patients underwent a reimplantation of the anomalous left coronary artery into the ascending aorta. One died at operation with extending myocardial infarction related to technical difficulty. The 2 survivors remain well but have persistent electrocardiographic changes and cardiomegaly.

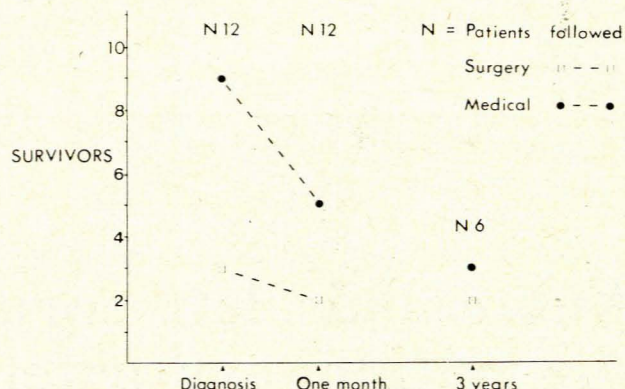


Fig. 3. Course and management.

Nine patients were managed medically. Five died, 4 within 1 month of presentation. The patient who died later initially presented at 4 months of age, and she remained well with a 32% left-to-right shunt at pulmonary artery level when studied 3 years after the initial diagnosis. She died suddenly at home and autopsy was not performed. The 4 survivors all require medication (digoxin and a diuretic) and all have signs of persistent anterolateral infarction on the ECG and cardiomegaly on chest radiographs. Three have survived 3 1/2-5 years after initial presentation.

It is striking that 5 of the 6 deaths occurred within 1 month of diagnosis; this emphasizes the need for early surgery if the latter is contemplated.

Discussion

The anomaly of the left coronary artery arising from the pulmonary trunk was first described as a clinical entity by Bland *et al.*⁵ in 1933. The condition has been extensively reviewed in recent years,^{3,4,6-8} and four clinical syndromes have been described by Wesselhoeft *et al.*³ Firstly, there is the infantile group, members of which present early with failure to thrive and angina-like attacks while feeding. Mortality in this group has been reported to be as high as 80%. Autopsy findings show an infarcted, myopathic left ventricle with a paucity of collaterals between the left and right coronary arteries. In the second group, mitral regurgitation with congestive cardiac failure is the dominant finding. Here the papillary muscle and mitral valve are involved by fibrosis and, less frequently, calcification. Thirdly, there may be a continuous murmur associated with angina-like attacks in older patients. Autopsy on these patients reveals a grossly dilated left coronary artery with viable anastomoses between the two coronary arteries. Finally, sudden death is reported in 30% of adults with this anomaly.^{4,8,10} Characteristically, autopsy shows a large

tortuous right coronary artery with no obvious collaterals, and fibrosis of the inner myocardium.

All but 1 of our patients were under 2 years of age and presented with congestive cardiac failure and mitral regurgitation, conforming to the infantile and mitral regurgitation groups described.

In the neonatal period the myocardium is perfused via the anomalous left coronary artery as a result of high pulmonary artery pressures. The normal fall of pulmonary arterial pressure during this period causes myocardial perfusion to drop to a critical level and survival depends on a dominant right coronary artery or the development of collaterals. Infarction of the left ventricular myocardium invariably follows at this stage.

One 5-year-old patient with a coincidental ventricular septal defect is of particular interest. Initial angiography failed to demonstrate the anomalous vessel and a ventricular septal defect with pulmonary hypertension was reported. Following surgical closure, with consequent decrease in pulmonary hypertension, the typical electrocardiographic changes developed, and on further investigation an anomalous left coronary artery with left ventricular dyskinesia was found. Five similar cases have been described, with similar outcome.^{2,11} We support the recommendation of Pinsky *et al.*¹¹ that the coronary arteries should always be identified at angiography to avoid tragic sequelae. We further conclude that in the majority of patients myocardial infarction has already occurred at initial presentation.

A significant left-to-right shunt at pulmonary artery level has been proposed as an important prognostic factor,^{2,3,7,8} the absence of a shunt being associated with a high mortality and its presence with long-term survival. In our 8 patients managed medically and studied angiographically the mortality rate was 50%. However, there was no difference in survival related to the presence of a shunt, since only 2 had a significant left-to-right shunt and 1 of these died during follow-up. The presence of a shunt likewise did not alter the degree of left ventricular dysfunction. One child is alive and asymptomatic at 6 years of age with no demonstrable shunt, 3 years after presentation. While we accept that the numbers are small, in our experience the presence or absence of a shunt at pulmonary artery level is not a useful prognostic factor.

A factor that appears significant in the prognosis is the age at presentation. All our patients who presented under 6 months of age died. Death occurs earlier in those with inadequate collaterals and a dominant left coronary artery, and therefore greater myocardial damage. In the group of patients presenting after 6 months of age there was a single late fatality, in a patient aged 3½ years. Three children in the medical group were recatheterized (2-4 years later), and all showed a significant left ventricular myopathy. To date neither of our surgical survivors has been restudied, so we have no evidence of graft patency. Both remain well, with mild symptoms despite persisting left ventricular dysfunction.

Since myocardial infarction has occurred in the majority of cases at presentation, surgery can at best be regarded as palliative. The definitive surgical procedure is reimplantation of the left coronary artery into the aorta, which has been reported as being technically feasible in young infants.¹² Improvement of myocardial function has not been well documented postopera-

tively except in 1 case recently reported by Levitsky *et al.*,¹³ which was notable in that the pre-operative ECG showed ischaemia but not established myocardial infarction. Reduction of the risk of sudden death in survivors postoperatively remains unproved and will only become clear after long-term follow-up. However, we suggest that if sudden death is related to extensive myocardial scarring rather than to ongoing ischaemia, it may be that surgery will not reduce the reported 30% incidence of sudden death in adults.

We offer the following recommendations for therapy. In the group under 6 months of age, the outlook is so poor that surgery may be justified in all cases. Because the majority of deaths in this group occur within 1 month of presentation, operation must be undertaken early. Improved short-term survival beyond 6 months of age would support surgical intervention in this group.

Beyond 6 months of age, the role of surgery in our view is less clear. Although the establishment of a 'two-coronary system' of myocardial blood supply would seem beneficial, the long-term results remain unproved. The high mortality rates occur in the early infantile group, while in older children and adults the mortality is significantly lower. This must be taken into account in the interpretation of surgical results. At present we would recommend surgery in the group aged over 6 months if there is evidence of ongoing myocardial ischaemia rather than established myocardial infarction (rare). In all other cases we would recommend conservative management with long-term follow-up.

REFERENCES

1. Keith JD. Anomalous origin of the left coronary artery from the pulmonary artery. *Br Heart J* 1959; **21**: 149-161.
2. Askenazi J, Nadas AS. Anomalous left coronary artery originating from the pulmonary artery: report on 15 cases. *Circulation* 1975; **51**: 976-987.
3. Wesselhoeft H, Fawcett JS, Johnson AL. Anomalous origin of the left coronary artery from the pulmonary trunk: its clinical spectrum, pathology and pathophysiology, based on a review of 140 cases with 7 further cases. *Circulation* 1968; **38**: 403-425.
4. Wenger NK. Rare causes of coronary artery disease. In: Hurst JW, ed. *The Heart*. 4th ed. New York: McGraw-Hill, 1978: 1345.
5. Bland EF, White PD, Garland J. Congenital anomalies of the coronary arteries: report of an unusual case associated with cardiac hypertrophy. *Am Heart J* 1933; **8**: 787-801.
6. Wilson CL, Dlabal PW, Holeyfield RW, Akins CW, Knauf DG. Anomalous origin of left coronary artery from pulmonary artery: case report and review of literature concerning teenagers and adults. *J Thorac Cardiovasc Surg* 1977; **73**: 887-893.
7. Perry LW, Scott LP. Anomalous left coronary artery from pulmonary artery: report of 11 cases: review of indications for and results of surgery. *Circulation* 1970; **41**: 1043-1052.
8. Nora JJ, McNamara DG, Hallman GL, Sommerville RJ, Cooley DA. Medical and surgical management of anomalous origin of the left coronary artery from the pulmonary artery. *Pediatrics* 1968; **42**: 405-414.
9. Chaitman BR, Bourassa MG, Lesperance J, Grondin P. Anomalous left coronary artery from pulmonary artery: an 8-year angiographic follow-up after saphenous vein bypass graft. *Circulation* 1975; **51**: 552-555.
10. Ihekwa FN, Davidson KG, Ogilvie B, Caves PK. Anomalous origin of the left coronary from the pulmonary artery with coronary artery steal in adults: report of two cases and review of the literature. *Thorax* 1976; **31**: 337-345.
11. Pinsky WW, Gillette PC, Duff DF *et al.* Anomalous origin of left coronary artery from the pulmonary artery with ventricular septal defect. *Circulation* 1978; **57**: 1026-1030.
12. Grace RR, Angelini P, Cooley DA. Aortic implantation of anomalous left coronary artery arising from pulmonary artery. *Am J Cardiol* 1977; **39**: 608-613.
13. Levitsky S, van der Horst RL, Hastreiter AR, Fisher EA. Anomalous left coronary artery in the infant: recovery of ventricular function following early direct aortic implantation. *J Thorac Cardiovasc Surg* 1980; **79**: 598-602.