

Haematoma in the transverse mesocolon secondary to acute pancreatitis

A case report

B. M. EPSTEIN, D. TANNE

Summary

A case of acute haematoma of the transverse mesocolon secondary to acute necrotizing pancreatitis is presented, with a brief discussion of the pathogenesis and computed tomographic findings. The value of computed tomography in acute complicated pancreatitis is emphasized.

S Afr Med J 1983; 63: 585-586

The pathway of spread of exudate in acute pancreatitis along the transverse mesocolon is well described.¹ In addition, findings on computed tomography (CT) of the inflamed transverse mesocolon have recently been demonstrated.² An acute haematoma in the transverse mesocolon has been demonstrated by CT and confirmed surgically at Baragwanath Hospital, Johannesburg.

Case report

A 40-year-old Black man with a history of heavy alcohol abuse was admitted with haematemesis of 3 days' duration, weakness and oliguria.

On examination the patient was in shock with a blood pressure of 80/60 mmHg. Marked gaseous distension was present with poor bowel sounds. The haemoglobin concentration was 16,9 g/dl, the white cell count 17 600/ μ l, the serum amylase level 409 U/l, the prothrombin index 43%, and the serum calcium level 1,95 mmol/l. The patient then passed a melaenic stool and the haemoglobin concentration dropped to 6,7 g/dl. During the next few days he was given frequent blood transfusions and it was noted that he had developed a large epigastric mass and that fluid had collected in the flanks.

A chest radiograph revealed a right pleural effusion, elevated right hemidiaphragm, plate atelectasis and volume loss. An abdominal radiograph showed a central abdominal opacity. Ultrasonography was unsuccessful owing to overlying intestinal gas.

CT demonstrated a massively oedematous pancreas with extension of the inflammatory process into the anterior pararenal spaces and small-bowel mesentery; there was some penetration of Gerota's fascia of the right kidney (Figs 1 and 2). There was

also extensive ascites surrounding the liver (Fig. 3). In addition, a high-density mass (30 Hounsfield units (HU)) was noted in the anatomical area of the transverse mesocolon. The pancreatic area

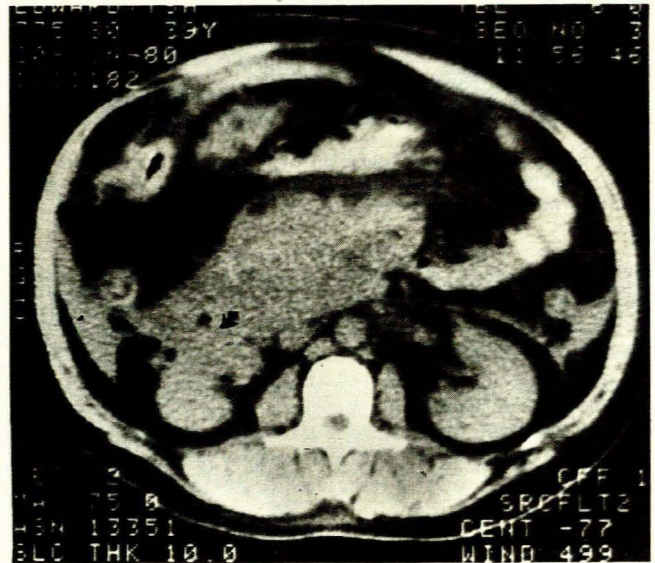


Fig. 1. Large low-density mass (0-6 HU) in area of head of pancreas. There is penetration of Gerota's fascia by the inflammatory process with extension to the right kidney (arrow).

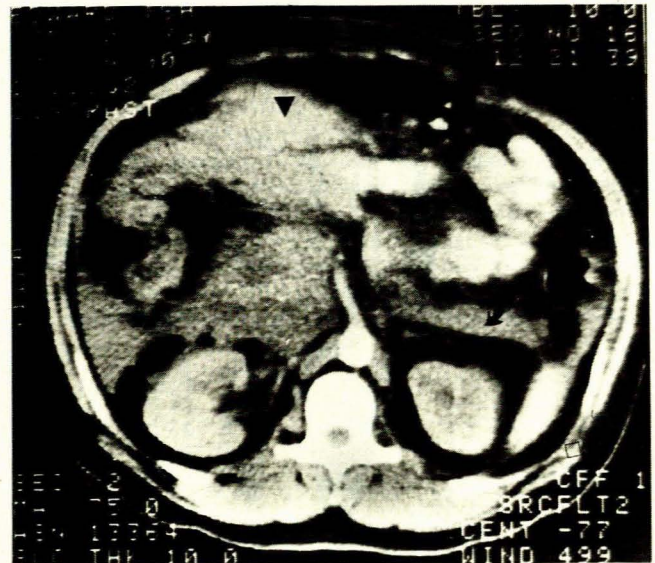


Fig. 2. Low-density area (head of pancreas) with markedly heterogeneous blush after bolus of contrast medium. There are inflammatory changes in the left anterior pararenal space (arrow) and an irregular area of high density anterior to head of pancreas (arrowhead). There is no change in the density of the mass compared with pre-contrast scans.

Departments of Diagnostic Radiology and Surgery, Baragwanath Hospital and University of the Witwatersrand, Johannesburg

B. M. EPSTEIN, M.B. B.CH., F.F.RAD. (D.) (S.A.), F.R.C.R.
D. TANNE, F.R.C.S.

Date received: 1 June 1982.
Reprint requests to: Dr B. M. Epstein, Department of Radiology, Hillbrow Hospital, Private Bag 23140, Joubert Park, 2044 RSA.

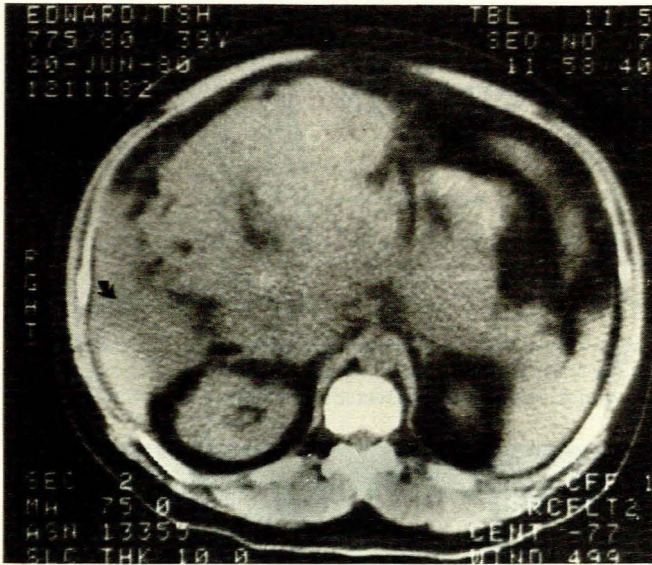


Fig. 3. Ascites adjacent to lower border of liver (arrow). There is a huge high-density mass (30 HU) anteriorly in the anatomical area of the transverse mesocolon (cursor).

itself measured 0-10 HU. (The haemoglobin concentration was 7,6 g/dl at the time of the scan.) The mass was not enhanced by the administration of an intravenous bolus of contrast medium.

Although the patient's clinical condition was stable at this stage, a laparotomy was performed. A large hard mass (8 x 6 cm) consisting of a haematoma was discovered in the transverse mesocolon. There was a necrotic mass in the duodenal area. No active bleeding was found. On histological examination the mass was found to consist of granulation tissue with blood clot undergoing organization.

The patient made good progress after the operation and was discharged 1 week later. One month later, the epigastric mass had decreased in size and he remained well.

Discussion

Massive haemorrhage is an unusual complication of pancreatic disease. Significant haemorrhage is said to occur in 2 - 5% of patients with acute pancreatitis.^{3,4} The proteolytic enzymes released in acute pancreatitis are responsible for producing the chemical inflammation and tissue destruction which is the fundamental lesion. Once the cell envelope has been breached or there is arteriolar damage with ischaemia and bleeding, haemorrhagic changes are seen macroscopically. In a review of visceral vessel erosion associated with acute pancreatitis 53 cases of severe bleeding in acute pancreatitis were analysed.⁵ The common vessels involved were the splenic artery (34% of cases),

the gastroduodenal artery (6%) and the pancreaticoduodenal artery (7%); the middle colic artery was involved in only 1 case.

Mortality in acute haemorrhagic pancreatitis is variously quoted as 33 - 100%, depending on the diagnostic criteria.⁶ Because of this, several authors have advocated prompt surgical intervention in patients with this clinical diagnosis. In a recent report⁷ it was concluded that a conservative approach should be followed in patients with evidence of pancreatic haemorrhage on CT unless the clinical findings dictate otherwise. In retrospect our patient did not require a laparotomy and would have benefited from a more conservative approach.

Although haematomas in the transverse mesocolon (due to trauma and iatrogenic causes and in patients on anticoagulant agents)^{8,9} have been well described, this is believed to be the first case reported in which a haematoma secondary to acute necrotizing pancreatitis developed in the transverse mesocolon. In a recent report the value of ultrasonography in the diagnosis of mesenteric haematomas was emphasized and the appearance on the CT scan of a high-density haematoma in the mesentery secondary to trauma was demonstrated.¹⁰ The appearance of a lesion with high-density values (40 - 60 HU) on CT is virtually specific for a recent haematoma. The HU value of our patient's mass was lower than expected owing to his severe anaemia, but was much higher than that of the adjacent normal parenchymal organs and the other areas involved by the extensive pancreatic inflammatory process.

In two recent reviews of the colonic complications secondary to acute pancreatitis^{11,12} no mention was made of this complication. The colonic complications secondary to acute pancreatitis may be characterized by three patterns of involvement: (i) early adynamic or localized paralytic ileus; (ii) fibrosing or stenosing pericolicitis; and (iii) colonic necrosis and fistulization.

This case report emphasizes the value of CT in acute complicated pancreatitis.

REFERENCES

1. Meyers M. *Dynamic Radiology of the Abdomen: Normal and Pathologic Anatomy*. New York: Springer Verlag, 1976.
2. Mendez G, Isikoff MB, Hill MC. CT of acute pancreatitis: interim assessment. *AJR* 1980; **135**: 463-469.
3. Jordan EL, Spjut HJ. Hemorrhagic pancreatitis. *Arch Surg* 1972; **104**: 489-493.
4. Lawson DW, Dagget WM, Civetta JM, Corry RJ, Bartlett MK. Surgical treatment of acute necrotizing pancreatitis. *Ann Surg* 1970; **172**: 605-615.
5. Gadacz TR, Trunkey D, Kieffer RF. Visceral vessel erosion associated with pancreatitis. *Arch Surg* 1978; **113**: 1438-1440.
6. Waterman WC, Wolsky BA, Kasdan ML, Abrams BL. The treatment of acute hemorrhagic pancreatitis by sump drainage. *Surg Gynecol Obstet* 1968; **126**: 963-971.
7. Isikoff MB, Hill CM, Silverstein W, Barkin J. The clinical significance of acute pancreatic hemorrhage. *AJR* 1981; **136**: 679-684.
8. Westcott JL, Smith JRV. Mesentery and colon injuries secondary to blunt trauma. *Radiology* 1975; **114**: 597-600.
9. Babb RR, Spittel JA jun, Bartholemew LG. Gastroenterologic complications of anticoagulant therapy. *Mayo Clin Proc* 1968; **43**: 738-751.
10. Fon TG, Hunter BH, Haber K. Utility of ultrasound for diagnosis of mesenteric hematoma. *AJR* 1980; **134**: 381-384.
11. Abcarian H, Eftaiha M, Kraft AR, Nyhus LM. Colonic complications of acute pancreatitis. *Arch Surg* 1979; **114**: 995-1001.
12. Grodzinsky C, Ponka JL. The spectrum of colonic involvement in pancreatitis. *Dis Colon Rectum* 1978; **21**: 66-70.