

## Presenting features of primary angle-closure glaucoma in patients of mixed ethnic background

J. F. SALMON

**Abstract** The relative frequency with which patients present with acute or chronic angle-closure glaucoma depends on their ethnic background. In order to examine the presenting features and effects of primary angle-closure glaucoma in people of mixed ethnicity, we reviewed all 'coloured' patients who presented to Groote Schuur Hospital with this diagnosis during a 5-year period. Of the 92 patients, 33 (36%) presented with acute angle-closure glaucoma and 59 (64%) with chronic angle-closure glaucoma. The level of intra-ocular pressure on presentation correlated well with the number of quadrants of angle closure (correlation coefficient:  $r = 0,73$ ,  $P < 0,001$ ). When individual eyes were assessed, a mean cup/disc ratio of  $\geq 0,8$  was present in 35% (65/184) and glaucomatous visual field loss was present in 56,5% (104/184). Total uni-ocular blindness secondary to chronic angle-closure glaucoma, was found in 16 (17%) patients. This study indicates that 'coloured' patients with primary angle-closure glaucoma are more likely to present with chronic symptoms and signs, and that the disease may result in devastating ocular damage and visual loss. In patients of mixed ethnic background with signs of primary glaucoma, chronic angle-closure should be excluded by careful gonioscopic evaluation of the drainage structures of the eye.

*S Afr Med J* 1993; 83: 594-597.

Primary glaucoma is classified into two main entities: open-angle glaucoma and angle-closure glaucoma. The conditions are differentiated by examination of the drainage structures of the eye with a gonioscope. In patients with angle-closure glaucoma, the trabecular meshwork is partially or totally closed by the iris root. Accurate differentiation between these two entities is important because the therapy of angle-closure glaucoma is significantly different from that of open-angle glaucoma.

Clinically, patients with angle-closure glaucoma may present with a red painful eye (so-called 'acute' glaucoma) or with a white eye and gradual, painless loss of vision (so-called chronic angle-closure glaucoma). The relative frequency of the two presenting profiles are dependent on the race of the individual. In whites, acute glaucoma is significantly more common than chronic angle-closure glaucoma.<sup>1,2</sup> However, in blacks and orientals the reverse is true, and most patients present with chronic angle-closure glaucoma.<sup>3-7</sup>

The Cape Coloured people, a distinct ethnic group residing in the Cape Peninsula, South Africa, have oriental, indigenous African and European ancestors.<sup>8</sup> The presenting features of angle-closure glaucoma and the effect of this disease on vision in these people, have not previously been reported.

### Patients and methods

All new 'coloured' patients who presented to Groote Schuur Hospital between January 1986 and December 1990 with the diagnosis of primary angle-closure glaucoma were assessed.

The diagnosis of primary angle-closure glaucoma was made on presentation if the intra-ocular pressure was  $> 21$  mmHg, or if a glaucomatous visual field was found, in the presence of a partially or totally closed angle or peripheral anterior synechiae. Provocation tests were not performed. Patients with secondary angle closure (e.g. secondary to uveitis, angle neovascularisation and lens intumescence) were excluded.

On presentation, patients were classified into one of two groups, acute or chronic, according to features. Patients who presented with a red painful eye, raised intra-ocular pressure and a closed angle were classified as having acute glaucoma. Those who presented with a history of painless visual loss, a non-inflamed eye, raised intra-ocular pressure and a partially closed angle were classified as having chronic angle-closure glaucoma. The appearance of the optic disc was not taken into account when classifying either of these groups.<sup>9</sup> Those patients who presented with a previous history of intermittent ocular pain or headache associated with a partially occluded angle, a normal intra-ocular pressure and glaucomatous disc cupping, were included in the chronic angle-closure glaucoma group. A record was kept of all patients with acute or chronic angle-closure glaucoma whose history suggested previous intermittent closure of the angle. Fellow eyes with a shallow anterior chamber, an occludable angle but a normal intra-ocular pressure and optic disc, were considered to be 'predisposed' to primary angle-closure glaucoma.

All patients were assessed by the same observer and underwent a full ophthalmic examination including slit-lamp examination, applanation tonometry and direct ophthalmoscopy. The best corrected visual acuity was recorded after control of the acute episode of intra-ocular pressure rise. The drainage angle was assessed by means of manipulative Goldmann gonioscopy or indentation gonioscopy. In the areas classified as closed, only Schwalbe's line was visible. The angle was divided into four quadrants and noted as 1/4, 2/4, 3/4 or 4/4 closed. The average of the vertical and horizontal cup/disc ratios was recorded. Visual fields were assessed in all sighted patients by means of a Humphrey automated field analyser using a three-level screening strategy. In patients with optic disc cupping, a field was considered glaucomatous if 17 or more absolute and/or relative defects were present in the full test area.<sup>10</sup> If the visual field could not be assessed on presentation, the examination was performed once the acute condition had been controlled.

Statistical analysis was performed using the *t*-test and Pearson's test of correlation. A finding was considered significant at  $P < 0,05$ .

### Results

In the 5-year period, 92 new patients presented with primary angle-closure glaucoma. The mean age at presentation was 62,2 years (44 - 82 years) and 69 (75%) were women.

Department of Ophthalmology, Groote Schuur Hospital and University of Cape Town

J. F. SALMON, F.R.C.S.

Accepted 25 Aug 1992.

Thirty-three (36%) patients presented with acute angle-closure glaucoma and 59 (64%) with chronic angle-closure glaucoma, a ratio of nearly 1:2. Six patients had bilateral acute glaucoma and 38 had bilateral chronic angle-closure glaucoma on presentation (Table I). Twenty patients with chronic angle-closure glaucoma gave a definite history of previous intermittent ocular pain and headache. Thirty-two fellow eyes were predisposed to angle-closure glaucoma.

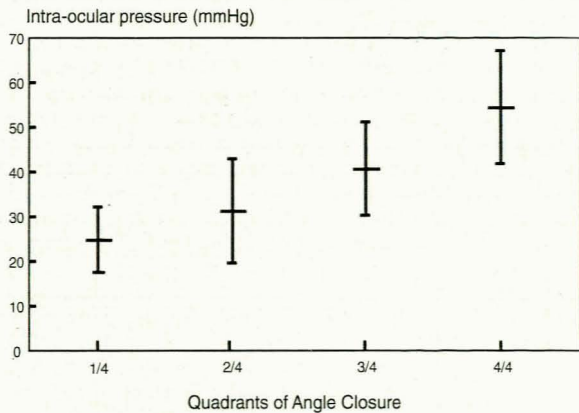
**TABLE I.**  
**Diagnosis in presenting and fellow eyes of 92 patients with primary angle-closure glaucoma**

| Fellow eye   | Presenting eye |           | Total     |
|--------------|----------------|-----------|-----------|
|              | Acute          | Chronic   |           |
| Acute        | 6              | —         | 6         |
| Chronic      | 8              | 41        | 49        |
| Predisposed  | 17             | 15        | 32        |
| Other*       | 2              | 3         | 5         |
| <b>Total</b> | <b>33</b>      | <b>59</b> | <b>92</b> |

\*Other\* comprises blind eyes secondary to trauma or neovascular glaucoma.

The mean intra-ocular pressure in eyes presenting with acute angle-closure glaucoma was 51 mmHg; with chronic angle-closure glaucoma 34,4 mmHg; and in eyes that were considered to be predisposed to closure, 16,2 mmHg. Despite a mean intra-ocular pressure of 34,4 mmHg in eyes with chronic angle-closure, the intra-ocular pressures were found to be between 40 mmHg and 49 mmHg in 22 eyes and between 50 and 59 mmHg in 13 eyes.

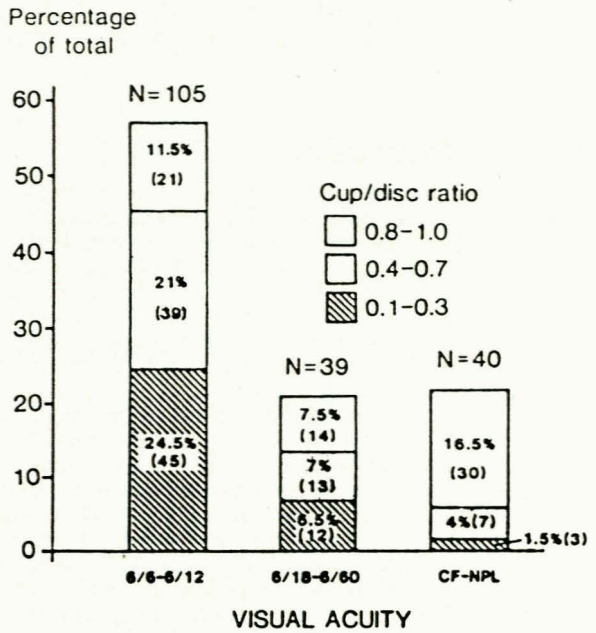
The intra-ocular pressure on presentation was compared with the number of quadrants of angle closure (Fig. 1). The superior quadrants were consistently involved in all eyes. The greater the number of closed quadrants, the higher the initial intra-ocular pressure. The correlation between the intra-ocular pressure on presentation and the number of closed quadrants was good (correlation coefficient  $r = 0,73$ ;  $P < 0,001$ ).



**FIG. 1.**  
**Mean intra-ocular pressure on presentation with one standard deviation compared with the number of quadrants of angle closure.**

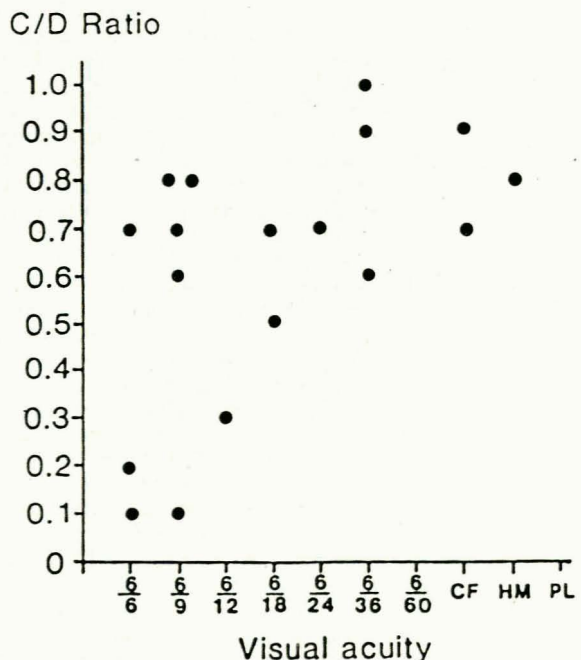
The mean cup/disc ratio was greater than 0,7 in 65 of 184 (35%) eyes, and the visual acuity assessed after control of the acute episode was worse than 6/12 in 79 (43%) eyes (Fig. 2). In 51 patients, the reduction in visual acuity was related mainly to nuclear sclerosis, although early cortical lens opacity and posterior subcapsular cataract were also observed. While cataract formation prevented examination of the optic disc in 3 eyes, intumescence of the lens was not found. Glaucomatous visual field loss was found in 24 eyes

with signs of acute glaucoma and in 80 eyes with chronic angle-closure glaucoma (104/184, 56,5%). In 15 eyes with acute and in 28 with chronic angle-closure, full visual fields were present.



**FIG. 2.**  
**Best corrected visual acuity and mean cup/disc ratio in 184 eyes of 92 patients.**

Eighteen patients presented with no light perception in one eye. The cause of the blindness was absolute angle-closure glaucoma in 13 patients (4 with acute glaucoma), neovascular glaucoma secondary to a central retinal vein occlusion in 3 patients and phthisis bulbi secondary to trauma in 2 patients. The fellow eyes in these 18 patients were also found to have experienced severe visual loss (Fig. 3). A diagnosis of chronic angle-



**FIG. 3.**  
**Best corrected visual acuity and mean cup/disc ratio in the 18 fellow eyes of patients with uni-ocular absence of light perception.**

closure glaucoma was made in 12 fellow eyes (mean intra-ocular pressure 33,7 mmHg) and acute angle-closure glaucoma in 5 fellow eyes (mean intra-ocular pressure 50,2 mmHg). One eye was considered to be predisposed to angle closure (mean intra-ocular pressure 16 mmHg). Only 4 of these 18 patients had a visual acuity of more than 6/12 with a normal optic disc and full visual fields.

## Discussion

The presenting features of primary angle-closure glaucoma depend on the ethnic background of the patients.<sup>9</sup> The majority of white patients with angle-closure glaucoma in South Africa and Europe present with acute symptoms and signs.<sup>1,7</sup> Blacks in South Africa and America, and orientals usually present with chronic manifestations.<sup>3,4,7</sup> These patients give a history of gradual visual loss that, without treatment, may progress to irreversible blindness.<sup>3</sup>

Historically, the so-called 'coloured' people trace their origins back to the 17th century. Their ancestors were introduced to Africa from eastern countries (the Malay Archipelago, Ceylon and India) and East Africa (Madagascar and Mocambique). Other ancestors were local indigenous people (the Khoi-Khoi and San) and, to a lesser extent, Europeans.<sup>8</sup> These racial influences are evident in their present-day genetic characteristics.<sup>11</sup> In order to study the presenting features and effect on the eye in patients of mixed ethnic background, 92 new coloured patients who presented during a 5-year period were reviewed.

Patients with angle-closure glaucoma may present with an acute, subacute (intermittent) or chronic condition. This classification is an oversimplification, because a combination of these types is often seen.<sup>9</sup> A patient presenting with an acute attack may have a deeply excavated disc in one or both eyes due to long-standing chronic angle-closure glaucoma. Similarly, a patient with chronic angle-closure glaucoma may also be suffering from asymptomatic intermittent episodes of angle-closure. In this study therefore, the features on presentation were assessed irrespective of glaucomatous disc damage and the patients were divided into only two categories, acute or chronic angle-closure glaucoma. Seven patients who presented with quiet eyes, shallow anterior chambers, partially occluded angles, normal intra-ocular pressures and cupped discs were included in the chronic angle-closure glaucoma group.

Chronic angle-closure glaucoma is also referred to as 'creeping' angle closure.<sup>12</sup> This disease is often misdiagnosed because it closely resembles primary open-angle glaucoma, in that patients are asymptomatic, have quiet eyes and often have cupping of the optic disc and visual field loss. Gonioscopy is the key to the diagnosis of chronic angle-closure glaucoma and it reveals a narrow angle with apposition between the iris and the trabecular meshwork. Apposition may result in permanent occlusion of the angle with peripheral anterior synechiae. The treatment for primary angle-closure glaucoma is laser iridotomy.<sup>13</sup> After this procedure, residual glaucoma is treated in a stepwise fashion by means of medical therapy and filtering surgery as needed.

Of the 92 patients, 69 (75%) were women and the mean age at presentation was 62,2 years. European studies have reported an identical sex distribution.<sup>1,4</sup> Other studies show that most patients present in their 6th and 7th decades.<sup>1,7,14</sup> There were no differences between the demographic characteristics of patients with acute glaucoma and those with chronic angle-closure.

During this 5-year period, 33 (36%) patients presented with an acute episode of angle closure and 59 (64%) patients with signs of chronic angle-closure glaucoma, a ratio of 1:2. Although it has been reported that

acute angle-closure glaucoma is rare in blacks, Luntz<sup>7</sup> found an incidence of 32% and therefore a similar acute/chronic ratio.<sup>5,6</sup> Twenty (21,7%) patients gave a definite previous history of intermittent ocular pain before presentation. In a study from Israel, 23% of patients with primary angle-closure glaucoma gave a history of subacute episodes, but Lowe<sup>15</sup> reported that nearly 50% of patients who presented with acute glaucoma had experienced similar symptoms in the past. Because of the asymptomatic nature of intra-ocular pressure spikes in our patients, the incidence of previous subacute episodes of angle-closure glaucoma may have been higher than 21,7%. All the fellow eyes of the 32 (35%) patients who presented with unilateral acute or chronic angle-closure glaucoma, were predisposed to angle-closure. Six (6,5%) patients presented with bilateral acute glaucoma, a figure in accordance with previous reports.<sup>2</sup>

The mean intra-ocular pressure on presentation was higher in patients with acute angle-closure glaucoma (51 mmHg) than in patients with chronic angle-closure (34,4 mmHg). The mean intra-ocular pressure for eyes predisposed to angle-closure was 16,2 mmHg, which is similar to previously reported 'normal' intra-ocular pressure values.<sup>16</sup> It was remarkable how high the intra-ocular pressure was on presentation in some patients with chronic angle-closure glaucoma (13 patients had an intra-ocular pressure of more than 50 mmHg) who had no symptoms or signs of acute congestion or corneal oedema. Similar findings have been noted in blacks in Africa and in America and have not been explained.<sup>4,6</sup>

The level of intra-ocular pressure on presentation correlated well with the number of closed quadrants of drainage angle assessed gonioscopically. Although it has previously been suggested that the height of the intra-ocular pressure is directly related to the extent of angle closure, a linear relationship and high correlation coefficient has not been shown before.<sup>13</sup>

Most of these patients presented with reduced visual acuity and glaucomatous visual fields. In 51 patients early cataract was found. These lens changes were probably age-related, although Lowe<sup>17</sup> has suggested that nuclear sclerosis may be a complication of primary angle-closure glaucoma. In addition, the effects of the acute and chronically raised intra-ocular pressure were present in many eyes. Only 15 patients with acute glaucoma were found to have a normal disc with full visual fields. Advanced disc excavation was present in 35% of eyes and glaucomatous visual field loss in 56,6% of eyes. Unilateral blindness was evident in 13 patients with absolute glaucoma and in 3 patients with neovascular glaucoma secondary to a central retinal vein occlusion; the latter is a complication of primary angle-closure glaucoma that has been recognised previously.<sup>18</sup> Evidence of advanced optic disc damage was present in the fellow eyes of most of the patients who presented with one blind eye. A similar pattern of destructive eye disease has been noted in south-east Asia.<sup>19</sup> This is in marked contrast to the findings of Leighton *et al.*,<sup>1</sup> who reported that 5 of 77 (6,5%) English patients had a blind eye (1 with neovascular glaucoma, 1 with a central retinal vein occlusion and 3 with absolute angle-closure glaucoma).

The effects of raised intra-ocular pressure on other anterior segment structures were not significant. Corneal oedema was present in only 23 patients on presentation. Of these, 9 had acute glaucoma with a normal optic disc and 14 had acute glaucoma with a cupped disc. Patients with chronic angle-closure glaucoma had no corneal oedema despite high intra-ocular pressures and in 10 patients with acute glaucoma, a clear cornea was found. This finding has been recognised previously and is difficult to explain, as significant corneal endothelial cell loss has been demonstrated following acute intra-ocular pressure elevation.<sup>17,20</sup>

This study was supported by grants from the Medical Research Council of South Africa and the University of Cape Town. Dr Sedick Isaacs provided advice on the statistical analysis of these patients. Professor A. D. N. Murray and Dr R. Maske reviewed the manuscript and Dr J. Kane-Berman gave permission to publish.

#### REFERENCES

1. Leighton DA, Phillips CI, Tsukahara S. Profile of presenting states of eyes in angle-closure glaucoma. *Br J Ophthalmol* 1971; **55**: 577-584.
2. Hyams SW, Friedman Z, Keroub C. Fellow eye in angle-closure glaucoma. *Br J Ophthalmol* 1975; **59**: 207-210.
3. Lowe RF, Lim ASM. *Primary Angle Closure Glaucoma*. 1st ed. Singapore: PG Publishing, 1989: 52.
4. Alper MG, Laubach JL. Primary angle-closure in the American negro. *Arch Ophthalmol* 1968; **79**: 663-668.
5. Avshalom A, Berson D, Blumenthal M, et al. Israeli ophthalmologists in Africa. *J Isr Med Ass* 1966; **70**: 250-254.
6. Neumann E, Zauberman H. Glaucoma survey in Liberia. *Am J Ophthalmol* 1965; **59**: 8-12.
7. Luntz MH. Primary angle-closure glaucoma in urbanised South African caucasoid and negroid communities. *Br J Ophthalmol* 1973; **57**: 445-456.
8. Marais JS. *The Cape Coloured People 1652 - 1937*. 1st ed. Johannesburg: Witwatersrand University Press, 1957: 1-31.
9. Hyams S. *Angle-closure Glaucoma*. 1st ed. Amsterdam: Kugler & Ghedini Publications, 1990: 2,3,45.
10. Kosoko O, Sommer A, Auer C. Screening with automated perimetry using a threshold-related three-level algorithm. *Ophthalmology* 1986; **93**: 882-886.
11. Botha MC. Blood group gene frequencies: an indication of the genetic constitution of population samples in Cape Town. *S Afr Med J* 1972; **46**: suppl, 1-27.
12. Lowe RF. Primary creeping angle-closure glaucoma. *Br J Ophthalmol* 1964; **48**: 544-550.
13. Hoskins HD, Kass M. Angle-closure glaucoma with pupillary block. In: *Becker and Shaffers' Diagnosis and Therapy of the Glaucomas*. 6th ed. St Louis: CV Mosby, 1990: 223-224.
14. Teikari J, Raivio I, Nurminen M. Incidence of acute glaucoma in Finland from 1973 to 1982. *Graefe's Arch Clin Exp Ophthalmol* 1987; **225**: 357-360.
15. Lowe RF. Angle-closure glaucoma: acute and subacute attacks: clinical types. *Trans Ophthalmol Soc Aust* 1961; **21**: 65-75.
16. Hollows FC, Graham PA. Intraocular pressure, glaucoma and glaucoma suspects in a defined population. *Br J Ophthalmol* 1966; **50**: 570-586.
17. Lowe RF. Primary angle closure glaucoma: damage to cornea and lens. *Br J Ophthalmol* 1965; **49**: 460-465.
18. Sonty S, Schwartz B. Vascular accidents in acute angle-closure glaucoma. *Ophthalmology* 1981; **88**: 225-228.
19. Lim ASM. Prevention of blindness in Singapore. *Singapore Med J* 1965; **6**: 96-102.
20. Markowitz SN, Morin JD. The endothelium in primary angle-closure glaucoma. *Am J Ophthalmol* 1984; **98**: 103-104.