

# Systemic lupus erythematosus in a black South African child

## First documented case report

H. M. COOVADIA, A. HUSSAIN, L. H. Z. MWELASE

### Summary

**Systemic lupus erythematosus (SLE) is poorly described among black children in Africa despite being more frequent among some black adult populations than their white counterparts. The first black South African child with SLE is documented. The patient was a 10-year-old girl who had fever, facial rash (with complement (C4) deposited at the dermo-epidermal junction of normal skin), weight loss, central nervous system involvement (depression, withdrawal, retinal exudates), renal involvement (glomerular filtration rate 54 ml/min/1.73 m<sup>2</sup>; membranous nephropathy with mild mesangial proliferation; World Health Organisation classification Vb), alopecia, lymphadenopathy, hepatomegaly, positive Coombs test, hypocomplementaemia, anti-DNA antibodies and positive anti-nuclear factor.**

*S Afr Med J* 1991; 79: 101-103.

Systemic lupus erythematosus (SLE) is exceedingly rare among black children in Africa despite the fact that it occurs more frequently among black than white adults in some countries.<sup>1</sup> We have previously reported 4 Indian children with SLE from a large referral hospital (King Edward VIII Hospital, Durban), which has an annual paediatric outpatient attendance of 100 000 and inpatient admissions of 8 000.<sup>2</sup> The first black child with SLE seen over a period of 28 years at the same hospital is reported here.

### Case report

A 10-year-old black girl was admitted to hospital with a history of weight loss, fever and facial rash of a few months' duration. On examination the weight was on the 10th National Center for Health Statistics centile (24,1 kg), height on the 50th centile (135 cm), weight/height on the 5th centile, and she was pale.

She was apathetic and withdrawn; a psychologist reported that the patient had 'an organic affective syndrome with major depression'. There was a photodistribution of hyperpigmented lesions on the face and neck and a 'butterfly' rash on both cheeks. Dermatological opinion concurred that this rash was typical of SLE. The patient had significant alopecia with a single area of cicatricial alopecia. There was generalised lymphadenopathy with small, discrete non-tender glands; the liver

was soft and enlarged to 3 cm below the rib margin. Examination of the optic fundi showed two soft exudates in the right posterior pole and one in the left posterior pole. The other systems were normal. A bedside urine sample revealed 15 white cells per high-power field; red cells 60 per high-power field; hyaline casts +++; granular casts ++; cellular casts + and albumin +++.

Laboratory investigations revealed the following: full blood count — haemoglobin 8,4 g/dl; white cell count  $4,1 \times 10^9/l$ ; platelets  $379 \times 10^9/l$  with a normocytic normochromic anaemia; erythrocyte sedimentation rate 133 mm/1st h (Westergren); direct Coombs test positive; serum sodium value 130 mmol/l, potassium 4,5 mmol/l, chloride 103 mmol/l, bicarbonate 18,3 mmol/l, urea 21,4 mmol/l and creatinine 122 mmol/l; liver function tests — total protein 87 g/l, albumin 30 g/l, globulin 57 g/l, bilirubin 4 mmol/l; alkaline phosphatase 110 U/l; aspartate aminotransferase 32 U/l;  $\gamma$ -glutamyl transferase 16 U/l; antinuclear factor and anti-DNA antibodies strongly positive; and other auto-antibodies (smooth muscle, anti-parietal cell, extractable nuclear antigen) negative. The serum complement was C3 — 0,37 g/l (normal 0,83 - 1,77 g/l); C4 — < 0,08 g/l (normal 0,12 - 0,36 g/l); and properdin factor B 0,40 g/l (normal 0,17 - 0,42 g/l). The serum immunoglobulins were IgG — 33,8 g/l (normal range 7,23 - 16,85 g/l); IgA — 1,93 g/l (normal range 0,7 - 3,12 g/l); and IgM — 2,50 g/l (normal range 0,63 - 2,77 g/l). The glomerular filtration rate measured by radio-active sodium chromate ethylenediamine tetra-acetic acid was 50 ml/min/1,73 m<sup>2</sup>.

Skin biopsy showed complement (C4) deposition at the dermo-epidermal junction.

Renal biopsy revealed: one core with 33 glomeruli all of which showed a mild-to-moderate mesangial widening and an increase in mesangial cells; capillary loops appeared prominent and on silver staining 'spikes' were noted on the basement membrane. The tubules, interstitium and vessels appeared normal. These features were consistent with the World Health Organisation classification of lupus nephritis grade Vb.

Cerebrospinal fluid, prothrombin time, partial thromboplastin time, creatine kinase, Wassermann reaction, chest radiograph, ECG, and lung function tests were all normal.

In order to reinforce the impression gained from the outward physical appearance that the child was black, blood group and HLA antigens were tested. Blood-group antigen determination was partly confounded by a previous blood transfusion; however, the results indicated the following: ABO blood group A; rhesus-type positive; rhesus phenotype probably Ro (cDe), MN type M inconclusive; N+, s+, He-, m<sub>1</sub>-, Dantu-. The relevant antigen phenotype in this case was Ro, which in Natal has been shown by Moores (personal communication)<sup>3,4</sup> to be present in 2% of whites, 1,6% of Indians, 22% of coloureds and 62% of blacks; the child therefore had a greater probability of being black than any of the other race groups. HLA studies revealed that the child had the following antigens: A2, A3; B35, B57; Cw4; DR7, DR52, DR53; DQ3. None of these antigens are more frequent or rare in blacks than in other race groups to be helpful in providing further supportive evidence of race.

Department of Paediatrics and Child Health, University of Natal and Prince Mshiyeni Memorial Hospital, Durban

H. M. COOVADIA, F.C.P. (S.A.), M.D., M.S.C.

A. HUSSAIN, M.B.B.S. (KARACHI)

L. H. Z. MWELASE, M.B. CH.B., D.C.H. (S.A.), F.C.P. (S.A.)



## Discussion

This report describes the first case of SLE in a black South African girl. The clinical manifestations and investigations revealed a fairly typical and full-blown picture of this disorder with regard to gender, fever, facial rash with complement deposition in normal skin, weight loss, central nervous system involvement (depression), retinal exudates, renal involvement, alopecia, generalised lymphadenopathy, hepatomegaly, positive Coombs test, hypocomplementaemia and anti-DNA antibodies and positive antinuclear factor. She therefore satisfied the American Rheumatism Association criteria for diagnosis of SLE,<sup>5</sup> and is similar in many respects to this disorder described in 70 young patients (< 20 years) reported recently from Minnesota.<sup>6</sup>

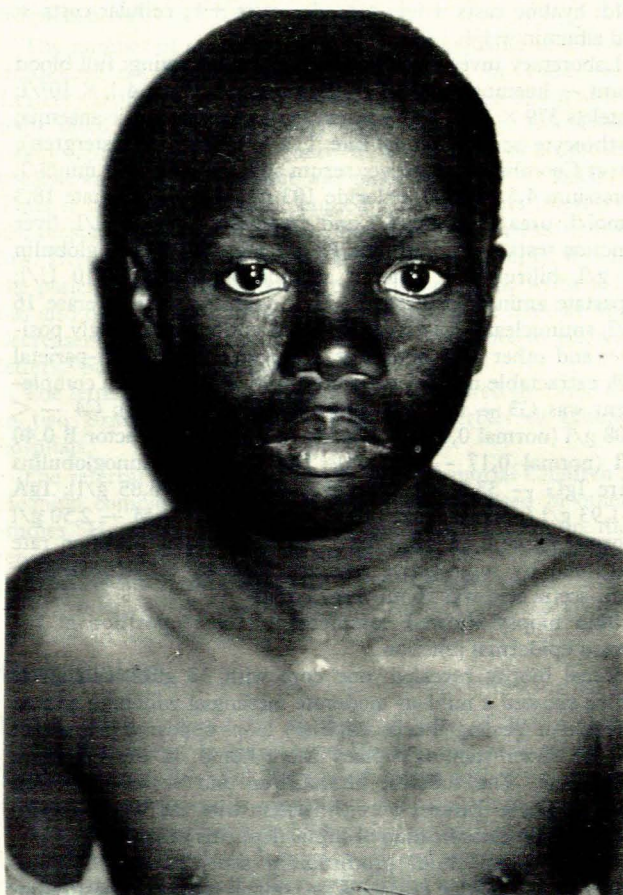


Fig. 1. Hyperpigmented lesions on face, neck and chest.

Auto-immune diseases occur infrequently among blacks in Africa<sup>7</sup> and Trowell<sup>8</sup> noted, for example, that no cases of SLE had been recorded up to 1958. Since then SLE remains sufficiently uncommon to warrant publication of isolated or small numbers of cases from Uganda,<sup>9</sup> Nigeria,<sup>7</sup> Senegal,<sup>7</sup> Congo,<sup>10</sup> Ghana<sup>11</sup> and South Africa.<sup>12</sup> Nearly all these were adult patients. An interesting paradox is the higher prevalence of this disease among black adults than in whites in the USA, the Caribbean, the UK and South Africa.<sup>1,12</sup> Community surveys in San Francisco<sup>13</sup> and New York<sup>14</sup> have shown that SLE occurs more frequently in black American women than in their white counterparts. The prevalence among American women between 15 years of age and 64 years of age is about

1:700 whereas among black women in the same age range in San Francisco it is 1:245. Similar high prevalence figures have been reported for Puerto Rican women.<sup>15</sup> Hospital data for SLE admissions from Cape Town show a rate of 4,9/1000 admissions for coloured (mixed race) women, 3,8/1000 for black women and 2,3/1000 for white women.<sup>12</sup> In the black population of the UK, which is mainly Jamaican, Cameron<sup>1</sup> reports a predisposition to SLE, which exceeds by a figure of 20 that for the remainder of the local population. He also suggests that black children in the USA, the Caribbean and the UK suffer from SLE more frequently than white children.

Yet SLE remains virtually unreported among black children in Africa.<sup>1</sup> A search of medical databanks revealed 5 cases in children under the age of 15 years with SLE in Africa.<sup>16-18</sup> Anecdotal reference was made to 2 black girls with SLE seen by Dr Rosen in Johannesburg in a recent report by Ransome and Thomson<sup>19</sup> dealing with coloured, white and Indian children with SLE. It is possible that a multisystem disease such as SLE, with exacerbations and spontaneous remissions, could have been missed in an environment swamped with infections and nutritional disorders. This seems unlikely in the major academic centres in South Africa and we have been especially alert because of previous experience of SLE in Indians and a research interest in kidney diseases of black children.

In addition to the physical appearance, the red cell antigen studies, although far from foolproof, suggest that the child is a black South African.

Genetic predisposition to SLE is well recognised and the most consistent HLA associations have been with the antigens A1, B5, B7, B8, DR2, DR3 and certain specific haplotypes.<sup>20</sup> The HLA profile of the child reported here does not include these antigens.

The Indian children with SLE we saw previously had an unfavourable outcome; all died within a short period after diagnosis and initiation of steroid therapy. The black child reported here has had a surprising and impressive early response to 1 mg/kg prednisolone daily; the rash has improved, the fever has settled, the alopecia has regressed, the weight has increased and the depression has been overcome.

We are grateful to the following for assistance: Dr J Abubaker, Skin Clinic; Mrs E. Smart, Natal Blood Transfusion Service; Clinical Psychology Department; Ophthalmology Department; Pathology Department; Dr A. Botha; Chief Medical Superintendent of King Edward VIII Hospital, Durban, for permission to study the patient; and Mrs E. Steyn for secretarial assistance.

## REFERENCES

1. Cameron JS. Pediatric nephrology in an unjust world. In: Holliday MA, Barratt TM, Vernier RL, eds. *Pediatric Nephrology*. 2nd Ed. Baltimore, Md: Williams & Wilkins, 1987: 341-347.
2. Rovers MJC, Coovadia HM. Systemic lupus erythematosus in children. *S Afr Med J* 1981; **60**: 711-713.
3. Moores PP. The blood groups of the Natal Negro people. M.Sc. thesis, University of Natal, 1976: 71-95.
4. Moores PP. The blood groups of the Natal Indian people. Ph.D. thesis, University of Natal, 1980: 156-178.
5. Cohen AS, Reynolds WE, Franklin EC *et al*. Preliminary criteria for the classification of systemic lupus erythematosus. *Bull Rheum Dis* 1971; **21**: 643-648.
6. Platt JL, Burke BA, Fish AJ, Kim Y, Michael AF. Systemic lupus erythematosus in the first two decades of life. *Am J Kidney Dis* 1982; **2**: 116-126.
7. Greenwood BM. Autoimmune diseases and parasitic infections in Nigerians. *Lancet* 1968; **2**: 380-382.
8. Trowell HC. *Non-infective Disease in Africa*. London: Edward Arnold, 1960: 145.
9. Shaper AG. Systemic lupus erythematosus: a review of the disorder as seen in African patients in Uganda. *East Afr Med J* 1961; **38**: 135-144.
10. Michaux JL, Sonnet J. Systemic lupus erythematosus in the Bantu. *Trop Geogr Med* 1965; **17**: 26-39.
11. Adu D, Anim-Addo Y, Foli AK *et al*. The nephrotic syndrome in Ghana: clinical and pathological aspects. *Q J Med* 1981; **50**: 297-306.



12. Jessop S, Myers OL. Systemic lupus erythematosus in Cape Town. *S Afr Med J* 1973; 47: 222-225.
13. Siegel M, Lee SL. The epidemiology of systemic lupus erythematosus. *Semin Arthritis Rheum* 1973; 3: 1-9.
14. Fessel J. Systemic lupus erythematosus in the community. *Arch Intern Med* 1974; 143: 1027-1035.
15. Siegel M, Holley HL, Lee SL. Epidemiologic studies on systemic lupus erythematosus: comparative data for New York City and Jefferson County, Alabama, 1956-1965. *Arthritis Rheum* 1970; 13: 802-811.
16. Otieno LS, Wairagu SG, Waweru HW. Systemic lupus erythematosus at Kenyatta National Hospital, 1972-1984. *East Afr Med J* 1985; 62: 391-396.
17. Bahemuka M, Bhatt KM. Transient retinopathy in uncomplicated case of systemic lupus erythematosus. *East Afr Med J* 1980; 57: 500-504.
18. Derrien JP, Normand CD, Monnier A, Ducloux M. Lupus érythémateux aigu disséminé chez l'Africain de race noire. *Bull Soc Med Afr Noire Lang Fr* 1976; 21: 65-70.
19. Ransome OJ, Thomson PD. Systemic lupus erythematosus with nephritis in children: a report of 6 cases. *S Afr Med J* 1986; 69: 629-633.
20. Walport MJ, Black CM, Batchelor JR. The immunogenetics of SLE. *Clin Rheum Dis* 1982; 8: 3-21.