

Black and brown widow spider bites in South Africa

A series of 45 cases

G. J. MÜLLER

Abstract Cases of black widow (*Latrodectus indistinctus*) and brown widow (*L. geometricus*) spider bites referred to the Tygerberg Pharmacology and Toxicology Consultation Centre from the summer of 1987/88 to the summer of 1991/92 were entered into this series. Of a total of 45 patients, 30 had been bitten by black and 15 by brown widow spiders. It was evident that black widow spider bites caused a more severe form of envenomation than brown widow bites, characterised by generalised muscle pain and cramps, abdominal muscle rigidity, profuse sweating, raised blood pressure and tachycardia. The symptoms and signs of brown widow bites were mild and tended to be restricted to the bite site and surrounding tissues. Conditions which should be considered in the differential diagnosis include cytotoxic spider bite, scorpion sting, snakebite, acute abdominal conditions, myocardial infarction, alcohol withdrawal and organophosphate poisoning. To prevent the development of complications, the administration of black widow spider antivenom is recommended in severe cases because untreated latrodectism could become protracted, without improvement, for several days.

S Afr Med J 1993; **83**: 399-405.

Owing to the lack of reliable information on the clinical toxicology of the two southern African widow spider species, *Latrodectus indistinctus* O.P.-Cambridge, 1904 and *L. geometricus* C. L. Koch, 1841, we recently studied the relative toxicity and polypeptide composition of the venoms of the two species.¹ As a sequel, this report, based on data collected from 45 cases, focuses on the medical aspects of black and brown widow spider bites. The controversy regarding the toxicity of the brown widow relative to that of

the more venomous black widow is also addressed and clarified. The morphology and habitat of the South African *Latrodectus* species are also described to assist the physician in identification.

Except for case reports involving 1 or 2 patients,^{2,3} no case series has been reported since Finlayson's 1937 publication on 15 cases of 'knoppie-spider' bites.⁴ All recent review articles and books on the subject of latrodectism in southern Africa⁷⁻¹² have either been based on the series of Finlayson⁴ or on publications from Europe, North America and Australia.

The term latrodectism is used to describe the systemic symptoms and signs of envenomation in humans caused by the bite of the *Latrodectus* spider species. The widow spiders are also locally known as the black and brown button spiders.

Methods

Black widow (*L. indistinctus*) and brown widow (*L. geometricus*) spider bites dealt with by the Tygerberg Pharmacology and Toxicology Consultation Centre from the summer of 1987/88 to the summer of 1991/92 were entered into this study. Criteria for admission include a positive identification of the spider species involved and/or symptoms and signs of latrodectism severe enough to warrant administration of antivenom, which led to a positive response within 6 - 12 hours. On account of the general uncertainty regarding the toxicity of brown widow spider venom, very strict admission criteria were maintained in that only cases in which *L. geometricus* was positively identified were included in the series.

Results

Of a total of 45 cases entered into the series, 30 were black widow (*L. indistinctus*) and 15 brown widow (*L. geometricus*) spider bites. The majority of bites took place in the summer, 65% occurring during the peak months of January, February and March. No bites were recorded in the winter months of June, July and August.

The most prominent symptoms and signs of black and brown widow spider bites documented in this series are summarised in Fig. 1. Thirty-two of the patients bit-

Department of Pharmacology, University of Stellenbosch, Parowvallei, CP

G. J. MÜLLER, B.SC., M.B. CH.B., B.SC. HONS
(PHARMACOLOGY), M.MED. (ANAESTH.)

Accepted 25 Aug 1992.

ten were adults, 2 were aged 13 - 19 years and 11 were children; 26 were male and 19 female. Of the 11 children, 9 were in the black widow and 2 in the brown widow spider group. Half the black widow bites took place in the home environment, 8 inside the house and 7 outside. The other half occurred in the veld, and of these 9 were associated with farming activities. Most of the brown widow bites, with the exception of 1 which occurred in a vineyard, took place inside the house (9) or in its immediate environs (5). Seventeen of the black widow bites were inflicted below the waist (lower abdomen and buttocks 5, legs 12) and 13 above the waist (arms and shoulder 8, neck 3, upper abdomen 1, back 1). In contrast, 10 of the brown widow bites were on the upper part and 5 on the lower part of the body (arms 4, chest 3, upper abdomen 1, head 1, lip 1, buttocks and legs 5). The exact time of 22 of the 30 black widow bites was known; in these cases symptoms and signs of latrodectism developed within 15 - 60 minutes of the bite.

A high degree of restlessness was evident in children in both the brown and black widow spider groups (73%). The two children (aged 4 and 10) in the brown widow spider group both had generalised muscle cramps and difficulty in walking. One presented with abdominal rigidity and the other with extreme restlessness and diaphoresis.

In all but 1 case, in which envenomation had been mild, patients bitten by black widow spiders received antivenom. The standard dose was 5 ml intramuscularly. Twenty patients received antivenom within 12 hours after the bite, 3 between 12 and 24 hours and 3 after 3 - 5 days. In 3 cases the exact time of antivenom administration was not documented. All the patients responded within 6 - 12 hours. In 19 cases the symptoms and signs cleared up completely within 6 hours

and in 7 the response was described as dramatic, with marked improvement within 30 - 60 minutes. Two patients received a follow-up dose of 5 ml antivenom within 6 hours after the first dose. Three patients in the brown widow spider bite group (2 children and 1 adult) received antivenom, 2 within 6 hours of the bite and 1 on day 5. Four patients, 3 of whom had been bitten by a black and 1 by a brown widow spider, remained ill until antivenom was administered on days 3 - 5. No allergic or other adverse reactions to the antivenom were reported. Other drugs given, either to relieve symptoms or to minimise the effects of a possible allergic reaction to the antivenom, included calcium gluconate, neuroleptics (promethazine and hydroxyzine), benzodiazepines (diazepam), antispasmodics (hyoscine), opioids (pethidine, morphine and tilidine), glucocorticosteroids and non-steroidal anti-inflammatory agents. Laboratory and/or radiographic evaluations were performed on 10 patients. The only consistent or positive finding was a moderately raised white cell count in 6 patients, ranging from 11 to $18 \times 10^9/l$. In 1 of 2 cases in which creatine kinase assays were performed the value was raised to 1 901 U/l. All the patients made a complete and uneventful recovery.

L. indistinctus was positively identified in 6 cases of black widow spider bite (20%). In 10 cases of brown widow spider bite the spider was brought in and identified by an expert as *L. geometricus*, and in the remaining 5 identification was based on a satisfactory description of the spider and its egg sac.

Discussion

Three species of the genus *Latrodectus* are found in South Africa.^{1,9,10} *Latrodectus indistinctus* (black widow or

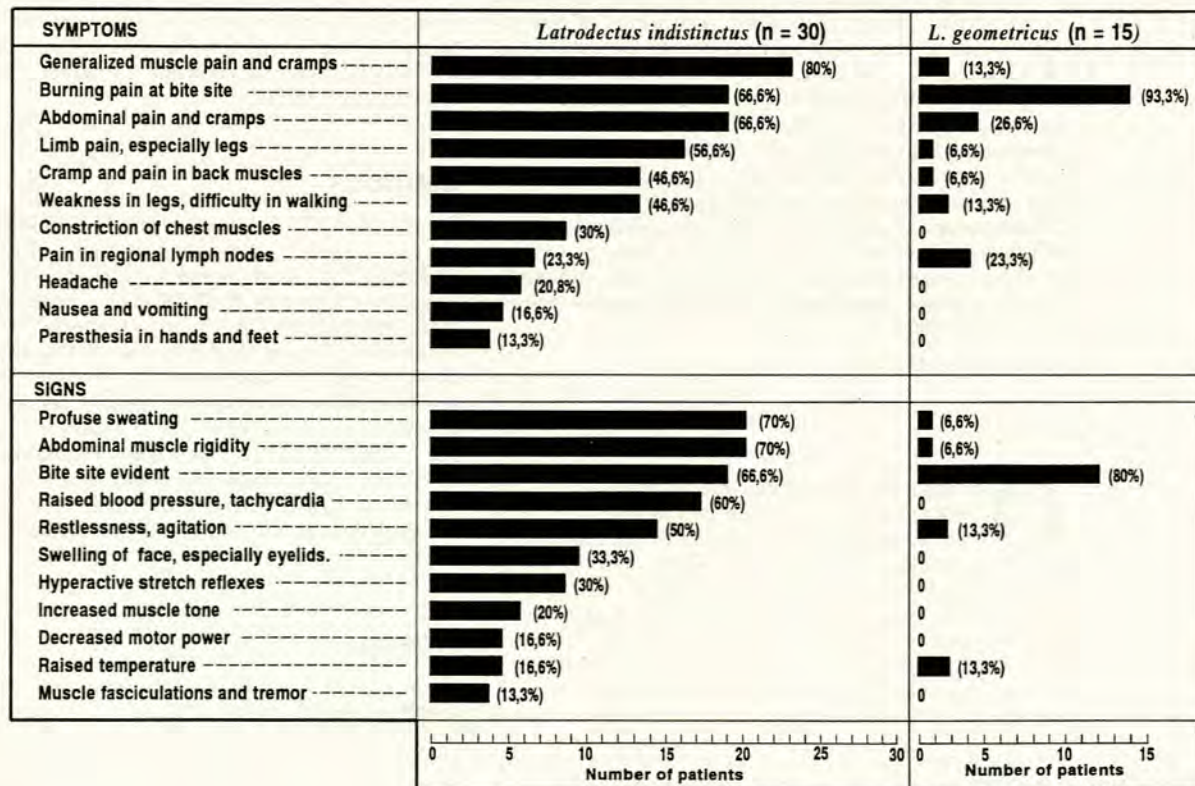


FIG. 1.

Prominent symptoms and signs of latrodectism documented in this case series.

black button spider) is endemic to South Africa, whereas *L. geometricus* (brown widow or brown button spider) is a cosmopolitan species. Both are widely distributed in this country. *L. rhodesiensis* Mackay, 1972 (Rhodesian widow spider) was first identified in Zimbabwe. It has since also been found in the Transvaal (various localities around Pretoria, Rust de Winter and Bronkhorstspuit, as well as on the Witwatersrand).^{1,9,10}

Descriptions of the morphology of the spiders refer to the females, since the males are not of medical importance.

L. indistinctus is a pitch-black or dark brown spider with an average body length of 12 - 15 mm. Young specimens have a prominent median red stripe or transverse red stripes on the middle to posterior third of the dorsal aspect of the abdomen. These stripes diminish with age until only a red spot remains above the spinnerets (Fig. 2). In some specimens the red spot fades and may disappear completely. Most adult females have irregularly distributed white to yellowish spots or speckles dorsally on the abdomen. There are no ventral markings on the abdomen. The legs are evenly black in colour and the third pair is typically shorter than the rest. The globular or pear-shaped egg sacs, which measure 10 - 15 mm in diameter, are white to greyish yellow in colour with a smooth silky surface¹⁰ (Fig. 3). Although *L. indistinctus* is occasionally found in suburban gardens and bites have occurred inside the home, it is predominantly a veld species. The nests are constructed at the base of small bushes, shrubs, tufts of grass or stubble or among heaps of loose debris such as plankton, sheets of corrugated iron and hessian bags. The great strength of the individual strands of silk is a distinctive feature of the webs of the *Latrodectus* genus.^{2,8-15}



FIG. 2. Black widow (button) spider (*L. indistinctus*) demonstrating a red, median stripe on posterior end of dorsal surface. The stripe diminishes with age until only a red spot remains above the spinnerets.



FIG. 3. Egg sacs of black widow spider.

L. geometricus is a slightly smaller and less robust-looking spider than *L. indistinctus*. The colour varies from creamy-yellow or greyish brown to dark brown. The dorsal surface of the abdomen displays an intricate pattern of well-demarcated geometric markings, ranging in colour from cream to brown to orange (Fig. 4). These patterns are less pronounced and almost absent in the darker specimens. *L. geometricus* is characterised by a consistent orange to red hourglass mark on the ventral surface of the abdomen (Fig. 5). The joints of the legs are darker and impart a banded light to dark brown appearance to the legs. The egg sacs can easily be distinguished from those of *L. indistinctus* by the numerous spicule-like projections distributed over the surface (Fig. 4). The webs of this cosmopolitan species are commonly found around homes throughout the RSA. They have a predilection for window sills, drain pipes, garden furniture, garden sheds, post boxes, barns, stables and outdoor toilets.^{2,8-15}



FIG. 4. Brown widow (button) spider (*L. geometricus*) with egg sac. The dorsal surface of the abdomen displays a pattern of well-demarcated, geometric markings.

Macroscopically *L. rhodesiensis* cannot be distinguished from *L. geometricus*. The egg sacs, however, differ from those of *L. geometricus* in that they are about 2½ times larger and have a woolly appearance without the spicule-like projections. Although nothing is known about their toxicity, this species must be considered potentially venomous.^{9,10}

Spiders which are often confused with black and brown widow spiders must be mentioned and described briefly. The *Steatoda* spider species (family: Theridiidae), also known as false button or false widow spiders or cob-web spiders, are often confused with the black widow. Ten species are known to occur in South Africa.¹⁶ These spiders are slightly smaller than the *Latrodectus* sp.; they are dark to blackish brown with a



FIG. 5.
Brown widow spider (*L. geometricus*). Note the orange hourglass mark on the ventral surface of the abdomen.

sickle moon-shaped mark on the anterodorsal part of the abdomen. In most species there is a beige to light-brown ventral mark on the abdomen, resembling an hourglass¹⁶ (Fig. 6). They are very abundant in the domestic environment of the western Cape and are commonly found in drains or under loose bricks, water-meter covers and debris in the garden and the farm-yard.¹³ Results of an investigation of the toxicity of *Steatoda foravae* Dippenaar-Schoeman and Müller, 1992 indicate that they are much less venomous than the brown widow spider and are of insignificant medical importance.¹⁷ Another group of spiders known as false button spiders belong to the genus *Theridion* (family: Theridiidae). These relatively small spiders, also known as the comb-footed house spiders, measure 3 - 5 mm in length. The creamy or greyish brown abdomen is globular and shiny with a distinct, well-demarcated median notched pattern ranging in colour from grey to dull red (Fig. 7). In some specimens a dull brown mark can be detected on the ventral surface of the abdomen. The legs are long, often banded with the first pair longest and the third pair shortest. It is often found inside the house in hidden crevices, under widow frames, on the ceiling, in the bathroom and on verandahs (patios). Although the toxicity of the local species is unknown, they must be considered potentially venomous.¹³ A garden spider variety, *Araneus* sp. (family: Araneidae), is often confused with *L. geometricus* because one of the species has a red hourglass-shaped marking on the ventral surface of the abdomen. This fairly big spider, also known as the hairy field spider, measures 15 - 25 mm in length and ranges from greyish brown to dark brown to green in colour. It differs from *L. geometricus* in that it is hairy with much shorter legs, the third pair being much

shorter than the body length. No reliable documentation with regard to its toxicity exists.⁹



FIG. 6.
S. foravae. The *Steatoda* spider species are also known as the false widow (button) or cob-web spiders. Note the beige to light-brown hourglass-shaped mark on the ventral surface.



FIG. 7.
A *Theridion* spider species, known as the comb-footed house spider or false button (widow) spider. Note the median notched pattern on the dorsal surface of the abdomen, ranging in colour from grey to dull red.

The venom of the *Latrodectus* and *Steatoda* spider species contains a 120 - 130 kDa protein neurotoxin known as α -latrotoxin which binds with high affinity to a specific presynaptic receptor (M_r 200 000), creating ionic pores and setting a process in motion resulting in a massive release of neurotransmitters. It displays no selectivity for specific types of synapses, has no effect on non-neuronal cell types, whether excitable or not, and is devoid of any detectable enzymatic activity.¹⁸⁻²¹ The massive release of the two main peripheral neurotransmitters, acetylcholine and noradrenaline, accounts for the entire clinical picture of latrodectism. A bite, especially by the more venomous *L. indistinctus*, induces a hyperactive state, initially characterised by a generalised stimulation of the somatic and autonomic nerve endings; this is followed by a phase of relative paralysis due to the depletion of neurotransmitters. The central nervous system is not affected owing to the apparent inability of the toxin to cross the blood-brain barrier.

The relative toxicity and polypeptide composition of the venom of *L. indistinctus* and *L. geometricus* have recently been studied by us.¹ It was shown that both contain α -latrotoxin and that, according to LD_{50} tests performed on mice, *L. indistinctus* was 3 - 4 times more venomous than *L. geometricus*. A follow-up study compared the toxicity, neurotransmitter releasing potency and polypeptide composition of the venoms from *S. foravae* (false button or widow spider), *L. indistinctus*

and *L. geometricus*.¹⁷ Alpha-latrotoxin was also found to be present in the venom of *S. foravae*. In neurotransmitter releasing experiments the crude venom of *L. indistinctus* was found to be 10 - 20 times more potent than that of *S. foravae* and 3 - 4 times more potent than *L. geometricus*. As was expected, the LD₅₀ of *S. foravae* venom in mice was 12 times that of *L. indistinctus*.

From the foregoing, as well as the symptoms and signs described in Table I, the typical clinical features and circumstances of black and brown widow spider bites can be described as follows.

Black widow spider bites usually cause a burning pain at the bite site, although some victims are not aware of being bitten. Since the majority of bites occur on an extremity, the pain typically spreads to the inguinal or axillary region, depending on the site, within 5 - 15 minutes. Pain in the regional lymph nodes soon after the bite probably indicates that the venom is transported via the lymphatic system. Within an hour the patient develops generalised muscular pain and cramps, especially in the abdomen, chest, back and thighs. The pain in the bigger muscle groups rapidly increases in severity and is sometimes described as excruciating. There is a feeling of weakness in the legs and difficulty in walking. A feeling of tightness in the chest, which is interpreted by some victims as difficulty in breathing, is often described. An erection is occasionally experienced, especially in children. The patient appears anxious and sweats profusely (Fig. 8); the clothes and bedding are often soaked with sweat. The regional lymph nodes are tender and occasionally palpable. A board-like rigidity of the abdomen is characteristic and the general position of flexion the patient may assume is a sign of increased muscle tone. Coarse involuntary movements and brisk tendon reflexes are often observed. An interesting (although not a regular) feature is a flushed and oedematous face, especially peri-orbitally, with accompanying conjunctival injection. The blood pressure is usually markedly raised and the pulse rate is rapid, although the occasional patient may present with marked bradycardia. A slight fever is sometimes present. The bite site can usually be located, but the local inflammatory reaction is mild and often unimpressive. No bite mark is detectable in 30% of cases, even in the presence of severe systemic symptoms and signs of envenomation. Laboratory and radiographic investigations are of little value as an aid in the diagnosis. In patients not treated with antivenom the condition may become protracted, without improvement for days to a week or more. This can lead to a general state of exhaustion and dehydration.

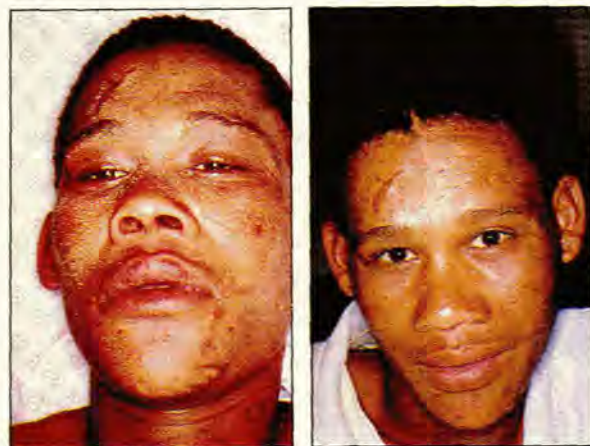

FIG. 8. Left: patient with severe latrodectism after a black widow spider bite demonstrating profuse sweating and slight swelling of face; right: the same patient, 12 hours after administration of antivenom.

Patients particularly at risk are small children, the elderly and those with cardiovascular and respiratory disease. The development of complications will obviously also be related to the duration and severity of the intoxication. Two cases of pulmonary oedema have been described as a complication of latrodectism.^{5,22} A case of peripheral neuritis following a black widow spider bite has also been reported.²³ Latrodectism in a woman who was 16 weeks pregnant has also been described.²⁴ She responded dramatically to the administration of antivenom, and the incident did not affect the course of the pregnancy. A normal baby was delivered at term by caesarean section. Although no deaths as a result of widow spider bites have been documented in recent times, accounts by various authors^{25,26} before the mid-1960s report a mortality rate of 1 - 6%.

Although the black widow spider is primarily a veld species, this study shows that a surprisingly high number of victims are bitten in the home environment. In spite of this no black widow spider webs have as yet been found inside or outside the house in localities usually inhabited by the brown widow. It is assumed that the spiders are picked up in clothing during gardening activities and carried into the house. In the past black widow spider bites have usually been associated with farming activities, but the mechanisation of crop harvesting has led to a drop in the risk to the farm labourer.

The bite of the brown widow spider usually causes a mild form of envenomation characterised chiefly by local symptoms and signs. Most adult patients complain of a local burning sensation which often spreads to the regional lymph nodes. Paraesthesiae in the surrounding skin and stiffness of the local muscles are often described. In a small percentage of patients abdominal and general muscular pain, as well as weakness in the legs, are experienced. On examination the bite site can usually be identified. It often manifests as a red macular spot or centrally blanched area surrounded by a 2 - 3 cm erythematous reaction. Occasionally there is localised increase in sweat secretion in the form of small droplets. A low-grade raised temperature is sometimes noted. The condition is self-limiting and usually clears up within 1 - 2 days, although some patients may experience a feeling of local discomfort for an extended period. Children may present with hyperactivity or restlessness and are more inclined to develop symptoms and signs of systemic envenomation.

The diagnosis of latrodectism, especially when the patient is unaware of being bitten or in cases where the culprit has not been identified, can be difficult. Acute medical and surgical conditions which should be considered in the differential diagnosis and have led to the misdiagnosis of latrodectism include the following:

Cytotoxic spider bites. Bites caused by the cytotoxic spiders, for example *Cheiracanthium* (sac spider) and *Loxosceles* (violin spider) spp., should be considered. They give rise to local tissue destruction and ulcer formation.^{9,11,12,27} The extent of the local tissue reaction and the absence of neurotoxic symptoms and signs should help in the differential diagnosis.

Scorpion sting. Although different mechanisms of action are involved, both widow spider and scorpion venom cause an increase in the release of peripheral neurotransmitters, resulting in some similarities between latrodectism and scorpionism. Classic symptoms and signs of scorpionism not found in latrodectism include dysphagia and loss of the gag reflex, which is associated with marked sialorrhoea, difficulty in breathing, visual disturbances and pronounced general hyperaesthesia. Scorpionism does not give rise to abdominal rigidity and increased sweating is not a prominent feature. Owing to the immediate and often excruciating pain of the sting, the scorpion is usually seen by the victim.²⁸

Snakebite. In a substantial proportion of widow spider bites and scorpion stings, the bite site is either insignificant or cannot be located. The same problem applies to serious neurotoxic snake bites. However, the earliest systemic symptoms and signs of a neurotoxic snake bite are visual disturbances, ptosis and dysphagia, features which are not associated with widow spider bites.^{29,30} The local tissue damage and inflammatory response of cytotoxic snakebites are usually so pronounced that it is not considered in the differential diagnosis.^{29,30}

Acute abdomen. Misdiagnosing latrodectism as an acute abdomen, for example a perforated peptic ulcer or acute appendicitis with peritonitis, has often led to unnecessary laparotomies.^{3,25} Other acute abdominal conditions which have been considered in latrodectism include renal colic, acute pancreatitis and a leaking abdominal aneurysm. Although the abdomen may be plank-hard, there is no marked local tenderness and no rebound tenderness, and the bowel sounds are normal.²⁵

Myocardial infarction. A 60-year-old man working in an onion field suddenly became ill, with a feeling of tightness and pain in the chest, abdominal pain and anxiety, increased perspiration with a cold, clammy skin, and nausea and vomiting. He was admitted to Tygerberg Hospital with the diagnosis of a myocardial infarction. Three days after admission a diagnosis of latrodectism was considered after all the special investigations performed had been found to be negative. He responded dramatically to the administration of antivenom and recovery was uneventful.

Alcohol withdrawal. A known alcoholic was admitted to a psychiatric ward with the diagnosis of delirium tremens. After complaints from friends that the history of a black widow spider bite had been ignored, a diagnosis of latrodectism was considered. The patient responded dramatically within 2 hours after the administration of antivenom and recovery was uneventful.

Organophosphate poisoning. The possibility of organophosphate poisoning is occasionally considered in the differential diagnosis in patients with suspected latrodectism. Both organophosphates and α -latrotoxin give rise to an increase in acetylcholine concentration in the synaptic cleft and it is not surprising, therefore, that there are similarities between the clinical profiles. Both can cause a state of anxiety and restlessness, a feeling of tightness in the chest, abdominal tightness and cramps, nausea and vomiting, increased sweating, muscular twitching, a raised blood pressure and tachycardia. Determination of the plasma cholinesterase level should resolve the problem.

Other conditions which have been considered in the differential diagnosis of latrodectism include tetanus, meningitis, pneumonia and poliomyelitis.²⁵

Management

The administration of specific black widow antivenom is the only effective treatment for severe latrodectism.²⁵ It is the author's experience that the state of systemic intoxication can be drawn out for a week or even longer, causing the patient to become exhausted, dehydrated and prone to the development of complications. For this reason it is recommended that antivenom be administered to patients presenting with systemic symptoms and signs. Although most authors agree with this approach,^{25,31,32} there are those who advocate a more conservative approach.³³ The spider antivenom is a refined equine antispider serum globulin, supplied in 5 ml ampoules. The standard dose is 5 ml intramuscularly for both adults and children. An additional dose of 5 ml can be administered after 4 to 6 hours should the response to the first dose be inadequate. Allergic reac-

tions to the antivenom are possible, as is the case with all serum preparations of animal origin.

Intravenous fluids should be administered to keep the patient well hydrated and urine flowing. Opioids and other central nervous system depressants, for example the benzodiazepines, are not only relatively ineffective but potentially dangerous because they can precipitate respiratory depression in an already compromised patient. The only effective agent for the relief of muscular pain and cramps is intravenous calcium gluconate, but its effect lasts for only 20 - 30 minutes and there is a limit to the amount which can be given. The use of neuroleptic agents, for example promethazine and hydroxyzine, is not recommended except when given for their antihistaminic properties to dampen the effects of a possible allergic reaction.

A spider bite, like any other wound, may easily become infected and cases of tetanus have been reported.²⁶ The administration of tetanus toxoid is therefore recommended.

This paper forms part of a Ph.D. project registered at the University of Stellenbosch by G. J. Müller.

The author is indebted to Mr John Visser, P O Box 916, Durbanville, 7550, for kind permission to use his photos (Figs 4, 5, 6 and 7). I would also like to thank Dr J. G. L. Strauss, Chief Medical Superintendent of Tygerberg Hospital, for permission to publish.

REFERENCES

- Müller GJ, Koch HM, Kriegler AB, Van der Walt BJ, Van Jaarsveld PP. The relative toxicity and polypeptide composition of the venom of two southern African widow spider species: *Latrodectus indistinctus* and *Latrodectus geometricus*. *S Afr J Sci* 1989; **85**: 44-46.
- De Meillon B, Gear J. A note on three noxious arthropods occurring on the Witwatersrand. *S Afr Med J* 1947; **21**: 407-410.
- Theron L. Button spider. *S Afr Med J* 1968; **42**: 1276.
- Rayner BL. The bite of *Latrodectus indistinctus* (button spider). *S Afr Med J* 1987; **71**: 716.
- Visser LH, Khushi SN. Pulmonary oedema from a widow spider bite: a case report. *S Afr Med J* 1989; **75**: 338-339.
- Finlayson MH. Specific antivenene in the treatment of 'knoppie-spider' bite. *S Afr Med J* 1937; **11**: 163-167.
- Finlayson MH. 'Knoppie-spider' bite in southern Africa. *Med Proc* 1956; **2**: 634-638.
- Zumt F. Latrodectism in South Africa. *S Afr Med J* 1968; **42**: 385-390.
- Newlands G. Review of medically important spiders in southern Africa. *S Afr Med J* 1975; **49**: 823-826.
- Dippenaar-Schoeman AS, Newlands G. The button spiders of South Africa. *Farming in South Africa* 1980; **146**: 1-4.
- Newlands G, Atkinson P. Review of southern African spiders of medical importance, with notes on the signs and symptoms of envenomation. *S Afr Med J* 1988; **73**: 235-239.
- Newlands G. Arthropods that sting or bite man — their recognition and treatment of the patient. *CME* 1989; **7**: 733-784.
- Prins A, Leroux V. *South African Spiders and Scorpions: Identification, First Aid, and Medical Treatment*. Cape Town: Anubis Press, 1986: 19-40.
- Smithers RHN. Contributions to our knowledge of the genus *Latrodectus* (Araneae) in South Africa. *Ann S Afr Mus* 1944; **36**: 263-313.
- Martindale CB, Newlands G. The widow spiders: a complex of species. *S Afr J Sci* 1982; **78**: 78-79.
- Dippenaar-Schoeman AS, Müller GJ. A new species of *Steatoda* (Araneae: Theridiidae) from South Africa. *Phytophylactica* 1992; **24**: 9-13.
- Müller GJ, Kriegler AB, Van Zyl JM, Van der Walt BJ, Dippenaar-Schoeman AS, Van Jaarsveld PP. Comparison of the toxicity, neurotransmitter releasing potency and polypeptide composition of the venoms from *Steatoda foravae*, *Latrodectus indistinctus* and *L. geometricus* (Araneae: Theridiidae). *S Afr J Sci* 1992; **88**: 113-116.
- Tzeng M-C, Siekevitz P. The effect of the purified major protein factor (α -latrotoxin) of black widow spider venom on the release of acetylcholine and norepinephrine from mouse cerebral cortex slices. *Brain Res* 1978; **139**: 190-196.
- Scheer H, Madeddu L, Dozio N, Gatti G, Vicentini LM, Meldolesi J. α -Latrotoxin of black widow spider venom: an interesting neurotoxin and a tool for investigating the process of neurotransmitter release. *J Physiol* 1984; **79**: 216-221.
- Scheer H, Meldolesi J. Purification of the putative α -latrotoxin receptor from bovine synaptosomal membranes in an active binding form. *EMBO J* 1985; **4**: 323-327.
- Meldolesi J, Scheer H, Madeddu L, Wanke E. Mechanism of action of α -latrotoxin: the presynaptic stimulatory toxin of the black widow spider venom. *Trends Pharmacol Sci* 1986; **7**: 151-155.

22. Salez Vazquez M, Biosca Florensa M. Contribucion al estudio del araneidismo. *Medna Clin* 1949; **12**: 244 (as cited in ref. 25).
23. Jacobs W. Possible peripheral neuritis following a black widow spider bite. *Toxicon* 1969; **6**: 299-300.
24. Russell FE, Marcus P, Streng JA. Black widow spider envenomation during pregnancy: report of a case. *Toxicon* 1979; **17**: 188-189.
25. Maretic Z. Latrodectism: variations in clinical manifestations provoked by *Latrodectus* species of spiders. *Toxicon* 1983; **21**: 457-466.
26. Bogen E. Poisonous spider bites: newer developments in our knowledge of arachnidism. *Ann Intern Med* 1932; **6**: 375-388.
27. Newlands G, Atkinson P. Behavioural and epidemiological considerations pertaining to necrotic araneism in southern Africa. *S Afr Med J* 1990; **77**: 92-95.
28. Müller GJ. Scorpionism in South Africa: a report of 42 serious scorpion envenomations. *S Afr Med J* 1993; **83**: 405-411 (this issue).
29. White JAM. Snakebite in southern Africa. *CME* 1985; **3** (No. 5): 37-46.
30. Visser J. Dangerous snakes and snake bite. John Visser, P O Box 916, Durbanville, 7550.
31. Wiener S. Red back spider bite in Australia: an analysis of 167 cases. *Med J Aust* 1961; **11**: 44-49.
32. Rauber AP. The case of the red widow: a review of latrodectism. *Vet Hum Toxicol* 1980; **22**: suppl 2, 39-41.
33. Moss HS, Binder LS. A retrospective review of black widow spider envenomation. *Ann Emerg Med* 1987; **16**: 188-191.