

The value of percutaneous trephine biopsy in the diagnosis of lesions of the vertebral column

T. ODENDAAL, L. B. LEMMER

Summary

The results obtained in 55 adult patients with sinister lesions of vertebral bodies, who were subjected to percutaneous trephine biopsy, are presented. A positive diagnosis was made on histopathological examination of specimens from 24 patients (44%). In the remaining 31 patients (56%), pathological features were seen in 25, but no specific diagnosis was possible. There were 4 false-negative results. The lack of diagnostic specificity in a large proportion of the patients is explained by the fact that they presented at an advanced stage of disease (probably tuberculosis) when the process of healing had already started. In bony malignant conditions the results were very satisfactory. Percutaneous trephine biopsy is therefore a valuable diagnostic tool for positive diagnosis in a large proportion of patients with osseous lesions and for the exclusion of malignant disease.

S Afr Med J 1991; 79: 21-23.

The vertebral column is relatively inaccessible due to its deep anatomical situation. Vertebrae are not only affected by disease themselves but frequently mirror disease processes elsewhere in the body. They are the most frequent site of metastases¹ and, in developing countries such as South Africa, tuberculosis. Making a definite diagnosis of a vertebral lesion on the basis of clinical features, laboratory tests, radiographs and even specialised investigative techniques is difficult and sometimes even impossible.²

A large proportion of the patients seen in the Spine Clinic at Ga-Rankuwa Hospital are children in whom the clinical picture and radiological appearance are so typical of advanced tuberculous spondylitis as to render protracted investigation superfluous. The situation is more complicated in adults with spinal disease in whom not only is the tuberculous lesion usually less extensive, and hence less 'typical' than in children, but two other common conditions also enter into the differential diagnosis — myeloma and metastases. It is frequently not possible to arrive at a firm diagnosis using indirect means of investigation.

Since October 1984 every adult patient seen at the clinic who had a sinister-looking vertebral lesion on standard radiography was subjected to percutaneous trephine biopsy of the lesion when any doubt existed about the diagnosis. Our results are presented and comment is made on the efficacy of this procedure in arriving at a diagnosis.

Department of Orthopaedics Ga-Rankuwa Hospital, Pretoria

T. ODENDAAL, M.B. CH.B., M.MED. (ORTHOP.)

Department of Anatomical Pathology, Medical University of Southern Africa and Ga-Rankuwa Hospital, Pretoria

L. B. LEMMER, M.B. CH.B., M.PRAX. MED., M.MED. (PATH.)

Patients and methods

Between October 1984 and August 1989, 55 patients with sinister-looking lesions of the vertebral bodies were selected for trephine biopsy. There were 30 men and 25 women (age range 18 - 73 years; mean 43,8 years). A total of 98 vertebrae were involved (Fig. 1). Twenty-eight patients had multiple level involvement, ranging from 2 to 7 vertebrae.

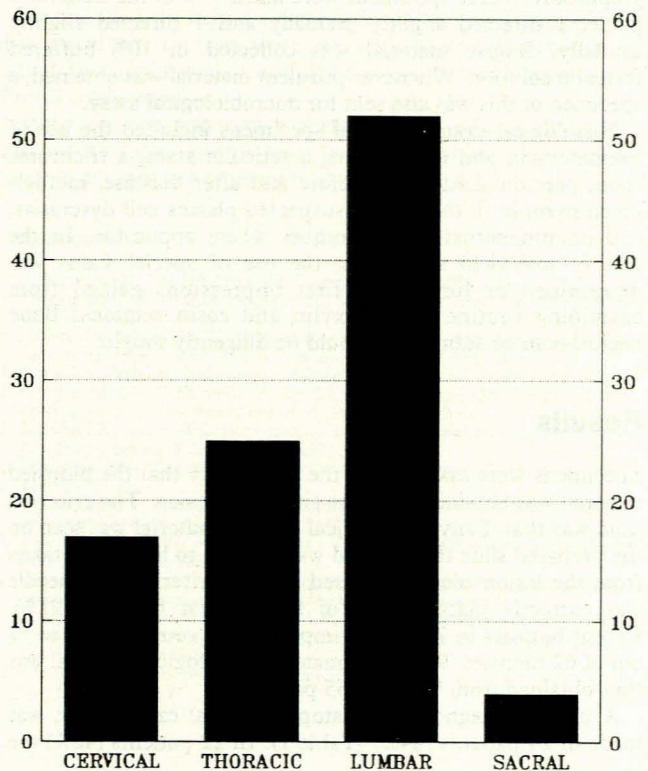


Fig. 1. Distribution of vertebrae.

No standard investigative routine was followed. A full blood count as well as serum urea and electrolyte determinations were obtained for all patients. Based on the clinical findings, the initial radiographs and the differential diagnosis formulated from these appropriate additional special investigations were decided upon and requested. It was decided at the outset that heavy reliance would be placed on the direct approach through percutaneous trephine biopsy and histopathological diagnosis.

Forty-eight patients were biopsied once and 7 had a repeat biopsy, giving a total of 62 biopsies. The procedures were performed in a clean orthopaedic operating room by, or under direct supervision of one of the authors (T.O.). General anaesthesia was used in all but 2 patients, who were judged to be too ill. Cervical vertebrae were biopsied with the patient supine. C1 and C2 were approached trans-orally through the posterior pharyngeal wall. C3 - 7 were biopsied through a right anterolateral approach, medial to the sternocleidomastoid

muscle in the fascial plane between the carotid sheath on the lateral side and oesophagus/larynx or trachea on the medial side. T1 - S1 vertebrae were trephined from a left posterolateral approach, with the patient in the right lateral position and the lower limbs flexed to flex the spine.

Trephining techniques have been described elsewhere¹⁻¹⁰ and will not be repeated here, except for the elucidation of certain important points. A Jamshidi bone biopsy trocar and cannula (internal diameter 3,5 mm) set was used in all cases. Since all but 1 of our patients had lesions of the vertebral body with collapse, a kyphosis usually marked the site of disease in the thoracic and lumbar spines. The needle point of entry was at the level corresponding to the widest interspinous distance in the kyphosis at a distance of 1 - 5 or 6 cm from the midline, this distance being determined by the exact vertebral level. The needle was advanced anteromedially at an angle of 35 - 45° to the sagittal plane until the vertebral body was reached, when the position of the needle tip was verified radiographically. Three specimens were taken — 1 in the transverse plane, 1 directed slightly cranially and 1 directed slightly caudally. Biopsy material was collected in 10% buffered formalin solution. Whenever purulent material was obtained, a specimen of this was also sent for microbiological assay.

Histological examination of specimens included the use of haematoxylin and eosin stains, a reticulin stain, a trichrome stain, periodic acid-Schiff before and after diastase, methyl-green pyronin in the case of suspected plasma cell dyscrasias, and immunoperoxidase techniques where applicable. In the case of low-yield specimens, the use of special stains was determined or limited by first impressions gained from examining routine haematoxylin and eosin sections. Bone necrosis can be subtle and should be diligently sought.

Results

Specimens were assessed for the probability that the biopsied material was obtained from the site of the lesion. The criterion used was that if any pathological osseous material was seen on the prepared slide the material was deemed to have been taken from the lesion biopsied. Based on this criterion, the needle was correctly placed in 50 of the 55 first biopsies (91%). Repeat biopsies in 7 patients improved the retrieval rate to 57 out of 62 biopsies (92%). Ultimately, pathological material was thus obtained from 53 of the 55 patients.

A positive diagnosis on histopathological examination was made in 24 patients (44%) (Table I). In 22 patients (40%) the

TABLE I. ANALYSIS OF POSITIVE DIAGNOSES ON HISTOLOGICAL EXAMINATION

Diagnosis	No. of patients
Definite tuberculosis	13
Purulent osteomyelitis (<i>Staphylococcus aureus</i> cultured)	1
Osteoid osteoma	1
Myeloma	2
Mesenchymal chondrosarcoma	1
Metastatic undifferentiated carcinoma	1
Metastatic, moderately differentiated, mucus-producing adenocarcinoma	1
Metastatic prostatic carcinoma	2
Metastatic carcinoma, possibly urothelium	1
Metastatic squamous cell carcinoma	1
Total	24

histological features were nonspecific and did not contribute towards the diagnosis, while in the remaining 9 patients the features neither positively confirmed nor excluded disease (Table II). In the latter group of 31 patients, necrosis and/or fibrosis was a common feature (occurring in 22), while reactive bone marrow was seen not infrequently.

TABLE II. ANALYSIS OF EQUIVOCAL FEATURES ON HISTOLOGICAL EXAMINATION

Results of analysis	No. of patients
Fibrosis and necrosis	7
Necrosis	5
Bone necrosis and hypercellular marrow	4
Necrosis and haemosiderosis	1
Necrotic bone and soft tissue	1
Necrosis and chronic inflammation in surrounding soft tissue	1
Reactive bone marrow and necrotic tissue	1
Chronic osteitis (radiologically tuberculosis)	1
Fibrosis and normal bone	1
Reactive changes and fibrosis, probably fracture	1
Pleomorphic plasma cell aggregation	1
Hypercellular marrow, haemosiderosis, osteoporosis	1
Reactive bone marrow	2
Normal bone marrow	2
Material not diagnostic	2
Total	31

There were 4 false-negative trephine biopsies. One patient had definite features of tuberculosis on histological examination of an open biopsy specimen subsequently taken during surgery. The other 3 patients were proved to have myeloma — 2 by open biopsy during surgery and 1 by serum protein electrophoresis. In the latter patient the material obtained by trephine biopsy was inadequate for diagnosis by histological examination.

Two patients who had previously been diagnosed as having carcinoma of the cervix and who had received radiotherapy, presented with lumbar vertebral lesions. Trephine biopsy in both cases showed bone necrosis and reactive marrow.

Complications

In 2 patients the dura was penetrated; in 1 there were no sequelae but in the other (suspected of having vertebral tuberculosis) meningitis developed, although the causative organism was never identified. She improved slowly over many months on antituberculosis therapy.

In the third instance of complications, the patient had a biopsy of the cervical spine by the anterolateral route. The patient had chronic pyogenic spondylitis and the planes of cleavage had become obliterated. Torrential haemorrhage followed perforation of the internal jugular vein, which stopped after prolonged firm external pressure. There were no after-effects.

Discussion

The low yield of positive diagnoses by histopathological examination in this study (44%) was as surprising as it was disap-

pointing. Published results vary but are superior to ours. Craig⁴ obtained conclusive results from 5 trephine biopsies in as many patients. Ottolenghi *et al.*⁵ had a 79% diagnostic rate in 34 patients, and Ottolenghi² quoted 29 personal cases in 1965 with a 92% positive rate and reported on 1078 biopsies where the positive diagnostic rate was 73%. Murphy *et al.*¹¹ reviewed the results in 164 patients and found a 94% overall accuracy rate but used 'true-negative' results in a positive sense, i.e. disease was proved to be absent. Other positive concurrence rates have been reported by Tehranzadeh *et al.*⁸ (72%) and Fyfe *et al.*⁹ (90,4% for specimens 2 mm or more in diameter).

Although the firm diagnostic yield in our study was only 44%, material suggesting disease was obtained from 25 of 31 patients with equivocal features on histological examination. The high frequency of necrosis and fibrosis suggested that the trephining might have been performed when healing was already under way. This is supported by the fact that our patients tend to seek medical help only at an advanced stage of illness, usually when they have been paraplegic for some weeks or months. Tuberculosis is endemic in the region served by this hospital and was, in fact, the provisional clinical diagnosis or featured in the differential diagnosis in 38 of the 55 patients in the present study. Seventeen of the 31 patients with equivocal or negative biopsy results were put on a course of antituberculosis medication on clinical grounds; 15 returned for variable follow-up periods and 11 were cured or improved. It seems not unreasonable to conclude that the bulk of our patients were suffering from vertebral tuberculosis at various stages in the natural history of the disease. Bony tuberculosis is known to be capable of spontaneous healing.¹² Tuberculosis was, in fact, the diagnosis most commonly made on histological examination of specimens in this study where a positive diagnosis was possible, which lends substance to this hypothesis.

The 4 proven false-negative biopsies (3 cases of myeloma and 1 of tuberculosis) demonstrate the fallibility of the technique, and this should be borne in mind.

There were confusing results in the 2 patients with known carcinoma of the cervix who presented with lesions in the lumbar spine. In both (L2 and L3, respectively) features of necrosis and a reactive bone marrow were found on histological examination. Since cervical carcinoma seldom metastasises to vertebral bodies (except in advanced cases through direct spread) and since the lesions in both these patients occurred relatively high up in the spine, the conclusion was drawn that

the bone necrosis probably resulted from radiotherapy that both patients had previously received.

Conclusion

Our overall positive diagnostic rate does not compare with published series. However, we are satisfied that this is not the result of technical error, since pathological material was obtained from all but 2 of our 55 patients. In our opinion, the explanation lies in the natural tendency towards healing in secondary tuberculosis and therefore in the stage of healing at which tuberculosis is seen in our clinic.

The great value of trephining was demonstrated in this study by the clarity with which primary and secondary (but not bone marrow) malignant disease was demonstrated. A negative biopsy result from a suspicious-looking vertebra can therefore safely be assumed to have excluded malignant disease.

Despite the high negative diagnostic rate in lesions suggestive of tuberculosis, 13 cases were positively identified. This permitted the institution of antituberculosis chemotherapy with clinical confidence.

Based on our experience therefore, we will continue to employ the technique of percutaneous trephine biopsy as a valuable adjunct to our diagnostic armamentarium.

REFERENCES

1. Ackermann W. Vertebral trephine biopsy. *Ann Surg* 1956; **143**: 373-385.
2. Ottolenghi C. Aspiration biopsy of the spine. *J Bone Joint Surg [Am]* 1969; **51**: 1531-1544.
3. Siffert RS, Arkin AM. Trephine biopsy of bone with special reference to the lumbar vertebral bodies. *J Bone Joint Surg [Am]* 1949; **31**: 146-149.
4. Craig FS. Vertebral body biopsy. *J Bone Joint Surg [Am]* 1956; **38**: 93-102.
5. Ottolenghi CE, Schajowicz F, De Schant FA. Aspiration biopsy of the cervical spine. *J Bone Joint Surg [Am]* 1964; **46**: 715-733.
6. Jamshidi K, Swain WR. Bone marrow biopsy with unaltered architecture: a new biopsy device. *J Lab Clin Med* 1971; **27**: 335-342.
7. Gladstein MO, Grantham SA. Closed skeletal biopsy. *Clin Orthop* 1974; **103**: 75-79.
8. Tehranzadeh J, Freiburger RH, Ghelman B. Closed skeletal needle biopsy: review of 120 cases. *AJR* 1983; **140**: 113-115.
9. Fyfe IS, Henry APJ, Mulholland RC. Closed vertebral biopsy. *J Bone Joint Surg [Br]* 1983; **65**: 140-143.
10. Hayes MMM. Poor biopsy technique: an obstacle course for the general pathologist (Correspondence). *Am J Dermatopathol* 1984; **6**: 414.
11. Murphy WA, Destouet JM, Gilula LA. Percutaneous skeletal biopsy, 1981: a procedure for radiologists — results, review and recommendations. *Radiology* 1981; **139**: 545-549.
12. Glatthar E. *Tuberculosis: Basic Perspectives*. Pretoria: Medical University of Southern Africa, 1977.