

Normal left ventricular function does not protect against propafenone-induced incessant ventricular tachycardia

R. N. SCOTT MILLAR, J. B. LAWRENSON, D. A. MILNE

Abstract Propafenone is a class Ic anti-arrhythmic agent with mild β -blocking properties which has recently become available in South Africa. We have used the drug in 3 patients with sustained monomorphic ventricular tachycardia not due to ischaemic heart disease. All had normal left ventricular function; 1 had Wegener's granulomatosis and 2 had arrhythmogenic right ventricular dysplasia. In the latter 2, propafenone provoked incessant monomorphic ventricular tachycardia which persisted for more than 24 hours despite repeated efforts at termination. The morphology was similar to the patients' spontaneous ventricular tachycardia, but the rate was slower and the QRS complexes broader, consistent with propafenone's marked ability to slow intraventricular conduction. It is postulated that incessant tachycardia results from perpetuation of re-entry due to marked conduction slowing produced by the drug. Previous reports have suggested that this is most likely to occur in patients with poor left ventricular function, but our experience indicates that those with normal left ventricular function are also at risk, particularly if the substrate for re-entry is present.

Propafenone, like all other powerful anti-arrhythmic agents, may provoke life-threatening arrhythmias and should be used with great caution after due consideration of the indications, even in patients with normal left ventricular function.

S Afr Med J 1993; 83: 256-259.

The potential hazards of anti-arrhythmic drugs are becoming better known, particularly since publication of the Cardiac Arrhythmia Suppression Trial (CAST) study.¹ In this trial the class Ic agents, flecainide and encainide, were shown to increase the risk of death by approximately threefold in patients with asymptomatic ventricular premature complexes after myocardial infarction. Although not altogether surprising, this result has led to re-evaluation of the role of powerful anti-arrhythmic agents in the treatment of relatively trivial arrhythmias. While the results of this study cannot be extrapolated directly to other agents and other patient groups, it is now recommended that this class of drug be reserved for patients with life-threatening ventricular arrhythmias, particularly those that have proved to be resistant to more commonly used agents.

Propafenone is a class Ic anti-arrhythmic agent with mild additional β -blocking properties² which has recently been released for general use in South Africa. It has been widely used in Europe for the past 10 years and has a reasonable safety record.³ The package insert⁴ correctly suggests that its use should be confined to patients with 'life-threatening' ventricular arrhythmias and cautions against its use in patients with significantly reduced left ventricular function.

We have used propafenone in selected patients since it became available in South Africa. This paper reports our experience with the drug in 3 patients with episodes of symptomatic sustained monomorphic ventricular tachycardia (VT) unrelated to ischaemic heart disease. These 3 patients had normal left ventricular function.

Patients and methods

The 3 patients are described below. They form part of a group of 7 patients who have received propafenone at Groote Schuur Hospital since its introduction in September 1990. All patients were admitted to the Coronary Care Unit for monitoring over the period of 5-7 days during which administration of the drug was started and the dose adjusted. This was done in anticipation of possible pro-arrhythmic effects and is our

Cardiac Clinic, Department of Medicine, Groote Schuur Hospital and University of Cape Town

R. N. SCOTT MILLAR, F.C.P. (S.A.)

J. B. LAWRENSON, F.C.P. (S.A.)

D. A. MILNE, F.C.P. (S.A.)

Accepted 10 Jun 1992.

Reprint requests: Professor R. N. Scott Millar, Cardiac Clinic, E25, Groote Schuur Hospital, Observatory, 7925 RSA.

policy in all patients who are being started on treatment with major anti-arrhythmic agents (class I or class III). Monitoring included surveillance by highly trained intensive care unit nurses, a computerised arrhythmia detection system in the bedside monitors, and Holter monitoring at intervals. Electrophysiological studies were performed using standard techniques.⁵ Programmed ventricular stimulation was done according to the following protocol: the right ventricle was paced starting at a cycle length ($S_1 - S_1$) of 600 ms and a premature stimulus (S_2) was introduced starting in late diastole after every eighth cycle. $S_1 - S_2$ was reduced by 10 ms decrements until the ventricular refractory period was reached. S_2 was then increased by 50 ms and a second stimulus (S_3) was then introduced. $S_2 - S_3$ was then progressively decreased until the ventricle became refractory to S_3 , after which $S_1 - S_2$ was decreased until S_3 again captured. This was continued until the ventricle became refractory to S_2 . If sustained VT had not been induced, the procedure was repeated at shorter drive cycle lengths of 500 and 400 ms. Finally, up to three timed extra stimuli were used at a drive cycle length of 500 ms. Ventricular tachycardia was considered non-inducible if sustained (longer than 30 s) tachycardia did not occur during the above stimulation sequence. Left and right ventricular function was estimated by standard echocardiographic or radionuclide techniques.

Case 1

A 30-year-old man with Wegener's granulomatosis, diagnosed in 1987 on the basis of typical biopsy findings and nasal bone, pulmonary, eye and skin involvement, was admitted in July 1990. At the time of a flare-up in disease activity, he experienced syncope. He was found to be in complete heart block and a dual-chamber pacemaker was inserted. His left ventricular ejection fraction was 60%. While being monitored, he was noted to have episodes of sustained and non-sustained VT. Mexiletine was tried without success and the patient was commenced on sotalol. He was re-admitted in October 1990 following recurrence of syncope as a result of pacemaker lead perforation. At the time of admission it was noted that VT was recurring. An increased dose of sotalol was tried and then propafenone was used as a single agent. The spontaneous occurrence of VT was not suppressed. The morphology of the tachycardia occurring during therapy did not differ from the patient's 'usual' tachycardia.

Sotalol was added to the regimen and a combination of sotalol and propafenone has been successful in suppressing arrhythmias.

Case 2

A man was diagnosed in 1988 as having idiopathic ventricular tachycardia causing palpitations and syncope. Various agents were tried but were discontinued either because of lack of effect or because of side-effects. The echocardiogram was normal (ejection fraction 60%). Sustained VT with a normal axis and left bundle morphology was easily induced by programmed electrical stimulation. This was similar to his spontaneous VT (Fig. 1). A diagnosis of idiopathic right ventricular outflow tract tachycardia was considered. Oral quinidine did not prevent the spontaneous onset of tachycardia. Treatment with propafenone was started (150 mg 8-hourly \times 6 doses, 300 mg 12-hourly \times 3 doses) and after 3 days of therapy electrophysiological studies were repeated. Minimal stimulation resulted in the provocation of a broad-complex tachycardia of similar morphology but slower than his 'usual' tachycardia. After DC cardioversion, repetitive monomorphic VT recurred with occasional sinus beats separating runs of tachy-

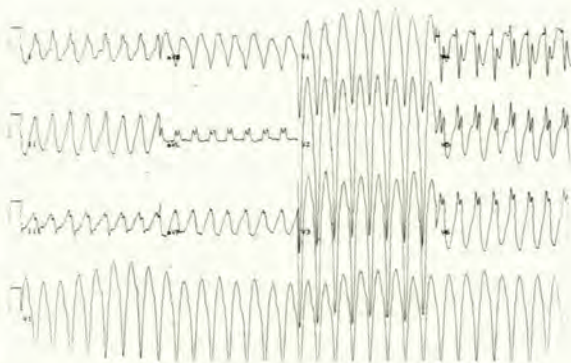


FIG. 1.
Case 2. 12-lead ECG plus rhythm strip during spontaneous VT (188/min). The QRS axis is normal with a left bundle-branch block pattern.

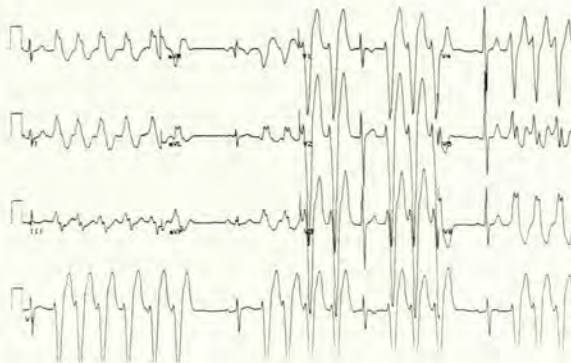


FIG. 2.
Case 2. Repetitive VT after propafenone. The pattern is similar to the patient's spontaneous VT but the QRS is wider (200 ms v. 160 ms) and the rate is slower (136/min).

cardia of variable duration (Fig. 2). Lignocaine did not result in sustained sinus rhythm. Hypertonic saline (600 ml of 5% NaCl) appeared to terminate the tachycardia for about 20 minutes, after which sustained VT recurred. Initially, the VT was well tolerated but after about 24 hours, he became hypotensive and sweaty. A lignocaine infusion slowed the rate and appeared to facilitate subsequent electrical cardioversion.

The patient has subsequently been shown to have arrhythmogenic right ventricular dysplasia. Surgery has been successfully performed, isolating the electrically 'malevolent' areas of the right ventricle from the rest of the heart.

Case 3

A man was diagnosed in 1979 as having idiopathic ventricular tachycardia. Cardiac catheterisation and endomyocardial biopsy performed then were normal. In 1986, radionuclide angiography showed a left ventricular ejection fraction of 61%. The first-pass study of the ventricles suggested that the right ventricle was dilated, raising the possibility of right ventricular dysplasia. The left axis, left bundle-branch block pattern during VT was compatible with this diagnosis (Fig. 3).

He was admitted in November 1990 for the withdrawal of aprinidine therapy after the tachycardia had recurred 4 times during the past year. Treatment with sotalol was started and progressively increased to 480 mg twice daily. The tachycardia remained easily inducible and treatment was changed to propafenone.

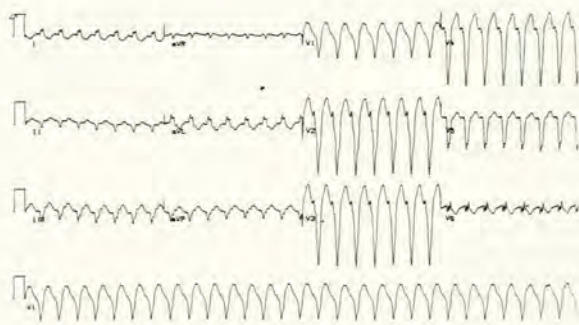


FIG. 3. Case 3. 12-lead ECG showing spontaneous sustained monomorphic VT (179/min) with a QRS axis of -50° and a left bundle-branch block pattern.

After a wash-out period of 5 days, propafenone therapy was started and the dosage increased to 150 mg 3 times a day over a period of 3 days. The patient developed spontaneous VT (150/min) (Fig. 4). The morphology was similar to his previous VT, but the rate was slower and the QRS complex considerably wider, suggesting propafenone toxicity. He was distressed by the tachycardia but remained haemodynamically stable. Electrical cardioversion failed. A lignocaine infusion was started. Sinus rhythm was briefly re-established (for about 2 hours) but VT recurred and persisted despite the infusion for a further 18 hours. Successful electrical cardioversion was then possible. The patient has also recently undergone successful surgery.

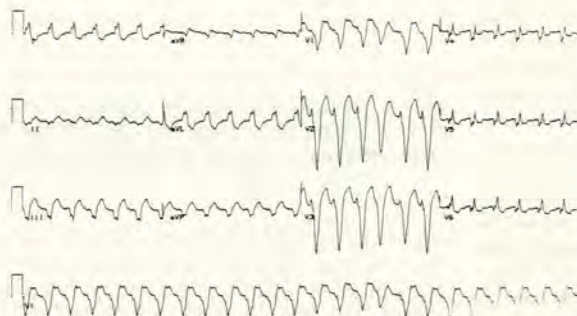


FIG. 4. Case 3. VT after propafenone showing slower rate (148/min) and wider QRS (210 ms v. 170 ms) but similar pattern to spontaneous VT.

Discussion

Serious and potentially fatal ventricular arrhythmias may be precipitated by the use of drugs given to suppress arrhythmias. The best known of these is 'quinidine syncope', first clearly described in 1960.⁶ This is the archetypical form of drug-induced polymorphic VT, subsequently labelled as torsades de pointes⁷ because of the common appearance of the QRS complexes, which appear to twist about an axis. This arrhythmia occurs as a consequence of prolongation of repolarisation, recognisable by an increase in the QT interval on the ECG, and is thought to originate from early after-depolarisations interrupting repolarisation.⁸ It may complicate treatment with class Ia agents such as quinidine, disopyramide⁹ and procainamide¹⁰ and also class III agents such as sotalol¹¹ and amiodarone.¹² Deaths have undoubtedly resulted, and a recent meta-analysis of controlled trials in which quinidine was compared with placebo in the prevention of recurrences of atrial fibrilla-

tion has suggested an approximately threefold increase in mortality in the quinidine-treated group compared with placebo.¹³ This is similar to the excess mortality observed in the active treatment group receiving flecainide or encainide in the CAST study.¹ The type of ventricular arrhythmia resulting from treatment with class Ic agents is different from that caused by class Ia and class III drugs. The class Ic agents (flecainide, encainide and propafenone) do not prolong repolarisation to any significant extent and do not cause the torsades de pointes type of polymorphic VT. They cause sustained monomorphic VT, which is characterised by a marked increase in QRS duration. It is often relatively slow but tends to be incessant, i.e. persistent or recurring within a very short time after termination.^{8,14,15} There are a number of reports of deaths resulting from this arrhythmia because of inability to terminate it by usual methods such as drugs or DC cardioversion. The mechanism of this pro-arrhythmic effect is speculative, but it is likely to be due to the very marked slowing of His-Purkinje and intra-ventricular conduction produced by these agents, which are very powerful blockers of the fast sodium channels.¹⁶ Blockade of the fast sodium channels is a property common to all class I anti-arrhythmic agents,¹⁶ and results in delay in the upstroke of the action potential (phase 0), which slows conduction and is probably an important anti-arrhythmic property under certain circumstances. However, the very marked slowing of conduction produced by class Ic agents may encourage re-entry by allowing extra time for refractory tissue to recover, thus allowing it to be re-excited.¹⁷

The conditions for re-entry may be so enhanced in a susceptible patient that the tachycardia becomes incessant and is reinitiated immediately after it is terminated. This is particularly likely to occur when a substrate for ventricular re-entry already exists, as demonstrated by 2 of our 3 patients. Each had both spontaneous and inducible sustained monomorphic VT, which was probably due to re-entry. They are unusual in that the underlying cause was not scar tissue from previous myocardial infarction, and left ventricular systolic function was normal. Patient 3 had been shown to have angiographically normal coronary arteries at the time of his initial presentation and was subsequently shown to have arrhythmogenic right ventricular dysplasia.¹⁸

Patient 1 has Wegener's granulomatosis. Ventricular tachycardia probably resulted from myocardial granuloma with scarring.^{19,20} Patient 2 has also been shown to have arrhythmogenic right ventricular dysplasia. All 3 patients had normal left ventricular systolic function, in contrast to many of the patients who have been observed to develop VT from class Ic anti-arrhythmic drug toxicity.

It is always difficult to be certain in an individual patient that an arrhythmia occurring during treatment with an anti-arrhythmic agent is due to the drug. However, the nature of the arrhythmia in our 2 affected patients is very suggestive of propafenone. The QRS morphology was similar to that of these patients' spontaneous tachycardias, suggesting that the same re-entry pathway was being used, but the QRS complexes were wider, and the initial tachycardia rates slower, than their spontaneous VT. It seems likely, therefore, that the incessant VT was provoked by excessive conduction slowing. In both patients, the tachycardia persisted more than 24 hours before it was successfully terminated for longer than a few minutes. During that time it was fortunately reasonably well tolerated. Over the 24-hour period the tachycardia gradually accelerated, consistent with the effects of the drug wearing off. Interestingly, the tachycardia in patient 2 appeared to stop abruptly for a while after infusion of hypertonic saline (600 ml

5% NaCl). This was tried after reading the report of a case with severe intractable VT caused by encainide,²¹ which was only controlled after large volumes of hypertonic saline had been infused. This patient survived despite the need to treat the subsequent hypernatraemia. The rationale for treating this arrhythmia with hypertonic saline is to overcome the effects of the sodium channel blockade by raising extracellular sodium concentration.²² In our patient, the apparent beneficial effect of the saline was short-lived and we did not persist in view of his relative haemodynamic stability. DC cardioversion appeared to be facilitated in both patients after 24 hours by the use of intravenous lignocaine.

Many patients suffering from serious ventricular arrhythmias have left ventricular dysfunction. It has become clear that these patients are at greater risk from the ill-effects of anti-arrhythmic drugs, both in terms of worsening left ventricular function and aggravation of arrhythmia.²³ It has been assumed that good left ventricular function protects against such effects, but cases such as those reported in this paper indicate that this is not so. It may be argued that occult left ventricular disease may have been present, and this cannot be entirely discounted. Perhaps more importantly, the abnormal right ventricles in the 2 affected patients were the site of origin of the ventricular tachycardias and left ventricular function was therefore irrelevant as far as the risk of pro-arrhythmia was concerned. Other reports^{24,25} have shown that malignant ventricular arrhythmias can also occur in patients receiving class Ic agents for supraventricular arrhythmias without previous evidence of ventricular arrhythmia or left ventricular dysfunction. This underlines the difficulty in predicting the risk in an individual patient.

Conclusion

The apparent provocation of incessant ventricular tachycardia by propafenone in 2 out of 3 patients with non-ischaemic sustained VT indicates the need for extreme care in the use of this agent. While propafenone may be less toxic in patients with less severe arrhythmias²⁶ or a different arrhythmogenic substrate, this represents a 'catch 22' situation in that it may be most toxic in those most likely to need powerful anti-arrhythmic treatment. Normal left ventricular systolic function does not preclude the aggravation of ventricular tachycardia by propafenone.

We believe that these potential deleterious effects should be widely known so that precautions can be taken. At the very least, any patient in whom this drug is used should be carefully monitored in hospital so that the drug can be withdrawn at the earliest sign of toxicity and the patient supported until its effects have worn off. The decision to use propafenone or any other major anti-arrhythmic drug should not be taken lightly.

We thank the Medical Superintendent of Groote Schuur Hospital for permission to publish and Ms V. Walters for preparation of the manuscript.

REFERENCES

1. Cardiac Arrhythmia Suppression Trial (CAST) Investigators. Preliminary report: effect of encainide and flecainide on mortality in a randomised trial of arrhythmia suppression after myocardial infarction. *N Engl J Med* 1989; **321**: 406-412.
2. Funck-Bretano C, Kroemer HK, Lee TJ, Roden DM. Propafenone. *N Engl J Med* 1990; **322**: 518-524.
3. Schlepper M. Propafenone, a review of its profile. *Eur Heart J* 1987; **8**: suppl A, 27-32.
4. Rythmol. Package insert. Knoll Pharmaceuticals South Africa (Pty) Ltd.
5. Ward DE, Camm AJ. *Clinical Electrophysiology of the Heart*. London: Edward Arnold, 1987.
6. Selzer A, Wray HW. Quinidine syncope: paroxysmal ventricular fibrillation occurring during treatment of chronic atrial arrhythmias. *Circulation* 1964; **30**: 17-26.
7. Dessertenne F. Ventricular tachycardia with two variable foci. *Cardiovasc Drugs Ther* 1990; **4**: 1171-1176.
8. Levine JH, Morganroth J, Kadish AH. Mechanisms and risk factors for pro-arrhythmia with type Ia compared with Ic anti-arrhythmic drug therapy. *Circulation* 1989; **80**: 1063-1069.
9. Tzivoni D, Keren A, Stern S, Gottlieb S. Disopyramide induced torsades de pointes. *Arch Intern Med* 1981; **141**: 946-947.
10. Strasberg B, Sclarovsky S, Erdberg A, et al. Procainamide-induced polymorphous ventricular tachycardia. *Am J Cardiol* 1981; **47**: 1309-1314.
11. Kuck KH, Kunze KP, Roewer N, Bleifeld W. Sotalol induced torsades de pointes. *Am Heart J* 1984; **107**: 179-180.
12. Westveer DC, Gadowski GA, Gordon S, Timmis GC. Amiodarone induced ventricular tachycardia. *Ann Intern Med* 1982; **97**: 561-562.
13. Coplen SE, Antman EM, Berlin JA, Hewitt P, Chalmers TC. Efficacy and safety of quinidine therapy for maintenance of sinus rhythm after cardioversion: a meta-analysis of randomised control trials. *Circulation* 1990; **82**: 1106-1116.
14. Buss J, Neuss H, Bilgin Y, Schlepper M. Malignant ventricular tachyarrhythmias in association with propafenone. *Eur Heart J* 1985; **6**: 424-428.
15. Stavens CS, McGovern B, Garan H, Ruskin JN. Aggravation of electrically provoked ventricular tachycardia during treatment with propafenone. *Am Heart J* 1985; **110**: 24-29.
16. Singh BN. Effects of anti-arrhythmic drugs on the cardiac action potential and in vivo cardiac electrophysiology. *Prog Cardiol* 1987; **15**: 37-86.
17. Singh BN. Controlling cardiac arrhythmias: to delay conduction or to prolong refractoriness. *Cardiovasc Drugs Ther* 1989; **3**: 671-674.
18. Marcus FI, Fontaine GH, Guiraudon G, et al. Right ventricular dysplasia: a report of 24 adult cases. *Circulation* 1982; **65**: 384-398.
19. Allen DC, Doherty CC, O'Reilly DPJ. Pathology of the heart and the cardiac conduction system in Wegener's granulomatosis. *Br Heart J* 1984; **52**: 674-678.
20. Schiavone WA, Ahmad M, Ockner SA. Unusual cardiac complications of Wegener's granulomatosis. *Chest* 1985; **88**: 745-748.
21. Gardner ML, Brett-Smith H, Batsford WP. Treatment of encainide pro-arrhythmia with hypertonic saline. *PACE* 1990; **13**: 1232-1235.
22. Pentel PR, Goldsmith SR, Salerno DM, Nasraway SA, Plummer DW. Effect of hypertonic sodium bicarbonate on encainide overdose. *Am J Cardiol* 1986; **57**: 878-880.
23. Pratt CM, Eaton T, Francis M, Woolbert S, Mahmarian J, Roberts R, Young JB. The inverse relationship between baseline left ventricular ejection fraction and outcome of antiarrhythmic therapy: a dangerous imbalance of risk-benefit ratio. *Am Heart J* 1989; **118**: 433-440.
24. Falk RH. Flecainide-induced ventricular tachycardia and fibrillation in patients treated for atrial fibrillation. *Ann Intern Med* 1989; **111**: 107-111.
25. Josephson ME. Anti-arrhythmic agents and the danger of pro-arrhythmic events. *Ann Intern Med* 1989; **111**: 101-103.
26. Morganroth J. Risk factors for the development of pro-arrhythmic events. *Am J Cardiol* 1987; **57**: 32E-37E.