



CASE REPORT

HYPERCALCAEMIA AND BONY LESIONS IN ASSOCIATION WITH PARATHYROID AND PROSTATIC CARCINOMA

F J L Kaplan, A B Fataar, N S Levitt

Parathyroid carcinoma is a rare disease accounting for 0.1 - 5% of cases of primary hyperparathyroidism.^{1,2} The pre-operative differentiation between parathyroid carcinoma and benign forms of primary hyperparathyroidism is difficult, as the presenting symptoms and signs are similar.³ Postoperatively the diagnosis may remain unclear as pathological differentiation can be equally difficult.⁴ The distinction is, however, important as primary hyperparathyroidism due to a benign adenoma has an excellent prognosis, while the average survival in a series of patients with parathyroid carcinoma was reported to be 40 months.⁵ Surgical removal of the tumour is at present the only effective therapy for parathyroid carcinoma.⁵

Primary hyperparathyroidism coexisting with prostatic carcinoma has rarely been described,⁶ although it is known that there is an increased incidence of gynaecological, thyroid and other malignancies in association with primary hyperparathyroidism.⁶ As prostatic carcinoma is an unlikely cause of hypercalcaemia,⁷ the presence of hypercalcaemia in a patient with prostatic carcinoma requires a search for an alternative underlying cause.

We present the first described case of hypercalcaemia secondary to parathyroid carcinoma in a patient with prostatic carcinoma, and highlight the use of nuclear imaging in diagnosis and management.

CASE REPORT

A 78-year-old man was referred to the Groote Schuur Hospital Endocrine Unit in February 1999 for investigation of

Associate Professor Dinky Levitt is head of the Endocrine Unit at Groote Schuur Hospital and the University of Cape Town. Her major research interests are the epidemiology of diabetes and its complications, diabetes health systems research and the fetal signs of chronic diseases. Dr Abdulbasier Fataar is a senior consultant in the Department of Nuclear Medicine, Groote Schuur Hospital. Dr Felicity Kaplan was senior registrar in the Endocrine Unit until February 2000, when she completed her training

hypercalcaemia. He had a background of prostatic carcinoma diagnosed in 1992 (prostatic specific antigen (PSA) 28 ng/ml, normal < 4 ng/ml), for which conservative treatment was recommended. In the same year a diagnosis of primary hyperparathyroidism was made, resulting in a parathyroidectomy. In addition he had a background of hypertension with associated renal impairment, mild cardiac failure and duodenal erosion. His medication included hydralazine, furosemide, Slow-K and aspirin.

In November 1998 he was admitted to his local hospital with a 1-year history of constipation, and was found to have faecal impaction. A barium enema was normal and he was treated with laxatives. He also complained of 3 - 4 months of pain in the left knee. A radiograph of the knee revealed a lytic lesion of the tibial plateau (Fig. 1) and a serum calcium level was found to be 3.63 mmol/l (normal 2.1 - 2.6 mmol/l). The urea level was 11 mmol/l and the creatinine level 319 μ mol/l. A diagnosis of metastatic prostatic carcinoma resulting in hypercalcaemia was considered, but thought to be unlikely as the tibial lesion was lytic rather than sclerotic. The patient was therefore referred to us with possible primary hyperparathyroidism.

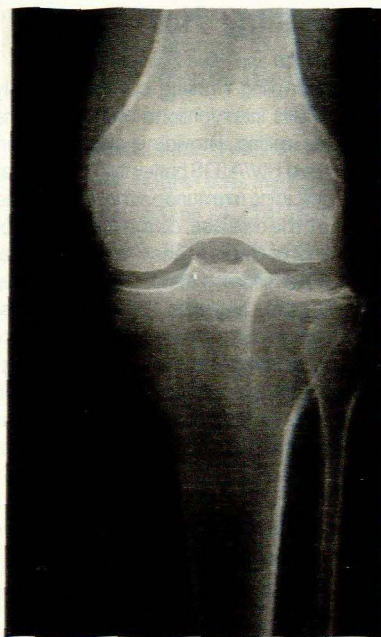

Fig. 1. Radiograph of the left knee showing a lytic lesion involving the lateral aspect of the tibial plateau.

At presentation to our clinic, his symptoms included a 27 kg weight loss over 1 year, progressive weakness, polydipsia, cold intolerance, dryness of the skin, insomnia and according to his daughter, occasional confusion. He also complained of vomiting which was responsive to cimetidine. There was no history of renal stones. On examination the patient appeared remarkably well and gave a good account of himself. The salient clinical findings were pallor, no lymphadenopathy, a parathyroidectomy scar, absence of a neck mass, hypertension, a mildly distended abdomen with palpable faecal loading, mild



proximal myopathy, delayed relaxation of the deep tendon reflexes and tenderness over the left proximal tibia. A rectal examination was refused.

The primary diagnosis was recurrence of his primary hyperparathyroidism with a brown tumour of the left tibial plateau. In addition there was clinical evidence of hypothyroidism. The results of biochemical investigations were: serum calcium 3.63 mmol/l (corrected for the albumin of 47 g/l), phosphate 1.47 mmol/l (normal 0.8 - 1.4 mmol/l), urea 17 mmol/l, creatinine 345 µmol/l, magnesium 0.9 mmol/l (normal 0.7 - 1.0 mmol/l), alkaline phosphatase 115 U/l (normal 30 - 70 U/l), parathyroid hormone level (PTH) 1 742 pg/ml (normal 12 - 72 pg/ml), serum protein electrophoresis negative and PSA 71 ng/ml. The phosphate level was relatively low for the degree of renal impairment, supporting a diagnosis of primary rather than tertiary hyperparathyroidism.

Assessment of thyroid function and the hypothalamo-pituitary-gonadal axis demonstrated evidence of sick euthyroid and sick gonadotroph syndromes, with normal prolactin and gastrin levels. The radiograph of his knee revealed a lytic lesion involving the lateral aspect of the left tibial plateau as well as smaller lesions involving the distal femoral shaft and proximal fibular shaft (Fig. 1). Diffuse osteopenia was evident on the skull radiograph and the chest radiograph revealed normal heart and lungs. A radiograph of his hands showed subperiosteal resorption and lesions compatible with brown tumours involving the left third metacarpal and proximal phalanx, and the proximal phalanx of the left thumb (Fig. 2). A whole-body Tc99m MDP bone scan revealed a 'super' bone scan compatible with a metabolic disorder together with areas of increased uptake involving the left lateral tibial plateau as well as the hands, ribs, pelvis and left femur.

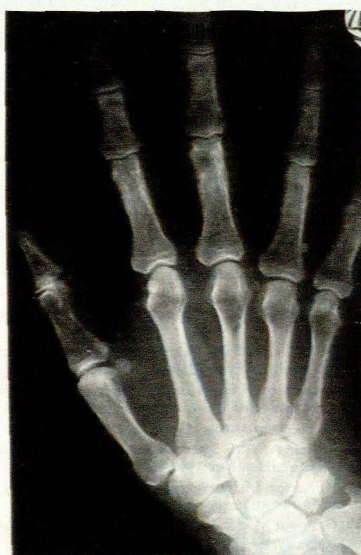

Fig. 2. Radiograph of the left hand showing subperiosteal resorption and lesions compatible with brown tumours involving the third metacarpal and proximal phalanx, and the proximal phalanx of the thumb.

Tc99m sestamibi parathyroid scan showed two areas of abnormally hyperfunctioning tissue in the region of the right lower pole of the thyroid and another just inferior to that area, compatible with hyperfunctioning parathyroid tissue (Fig. 3). The patient was referred for parathyroidectomy. Histological examination revealed a right inferior parathyroid gland neoplasm but it was unclear whether this was benign or malignant. Postoperatively the PTH and calcium levels remained persistently elevated at 1 045 pg/ml and 3.1 mmol/l respectively, while the sick euthyroid and gonadotroph syndromes resolved without replacement therapy.

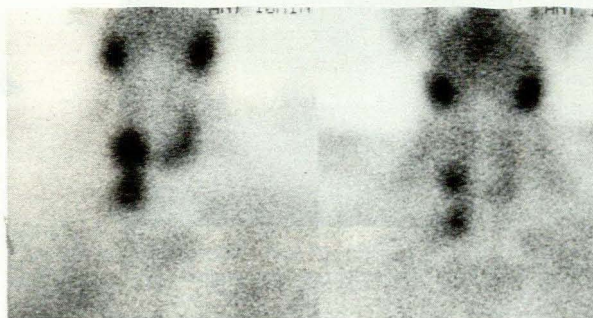


Fig. 3. Tc99m sestamibi parathyroid scan showing two areas of abnormally hyperfunctioning tissue in the region of the right lower pole of the thyroid and another just inferior to that area.

Further investigations were requested. Repeat sestamibi scan revealed an area of abnormally increased uptake below the right thyroid lobe. This correlated with a 1.5 cm soft-tissue mass in the right paratracheal region below the lower pole of the right thyroid lobe extending over a length of 3 cm, seen on computed tomography (CT) scan. The patient underwent repeat parathyroidectomy 4 months after the first procedure. On this occasion an adenocarcinoma of the right inferior parathyroid gland was diagnosed on histological examination. Postoperatively the serum calcium level fell to 1.65 mmol/l and the PTH to 256 pg/ml. The patient was treated with oral calcium and 1-alpha-hydroxycholecalciferol in anticipation of the increased calcium requirement during skeletal remineralisation for at least a year postoperatively. At his last follow-up visit 3 months postoperatively the patient's calcium level was 2.33 mmol/l and his phosphate level 1.31 mmol/l, and he felt remarkably well with minimal knee pain. A repeat radiograph of the knee showed filling of the previously lucent area (Fig. 4). Osteodensitometry demonstrated osteoporosis of the left hip (T-score -2.93 at the neck of femur), and osteopenia of the lumbar spine (T-score -2.22 at L 1-4), compatible with hyperparathyroidism in which the resorption of cortical bone exceeds that of cancellous bone. The case has been reviewed by the urologists who have recommended conservative treatment for the prostatic carcinoma. Future plans include repeat osteodensitometry in 1 year, as well as monitoring of the calcium level in view of the possibility of recurrence of parathyroid carcinoma.

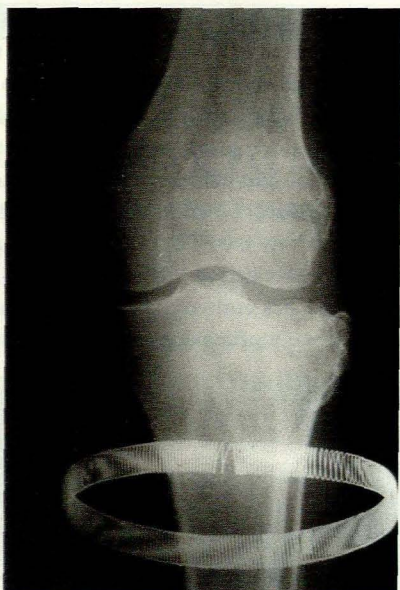


Fig. 4. Repeat radiograph of the left knee showing filling of the previously lucent area involving the tibial plateau.

DISCUSSION

Parathyroid carcinoma is a rare cause of primary hyperparathyroidism and is difficult to distinguish from benign forms of hyperparathyroidism. It should be suspected in hyperparathyroid patients with serum calcium levels > 3.5 mmol/l, markedly elevated PTH levels, a palpable neck mass, pre-operative imaging showing a tumour measuring 3 cm or more and recurrence of previously treated primary hyperparathyroidism.¹⁵ Cordeiro *et al.*¹ reported a series of cases with parathyroid carcinoma where PTH levels varied from 1.03 to 16.5 times the upper limit of the normal range, with an average of 7.2 times. Our patient had all of the above features: serum PTH 27 times the upper limit of normal, serum calcium 3.63 mmol/l, tumour size 3 cm before final surgery, and a history of previous parathyroidectomy. Ultimately, however, the diagnosis of malignancy depends on pathological evaluation and may only become apparent after the recurrence of a previously resected 'parathyroid adenoma', as in our case.⁸

Parathyroid carcinoma in a patient with prostatic carcinoma has not previously been described. The patient was initially thought to have metastatic prostatic carcinoma resulting in hypercalcaemia. Hypercalcaemia secondary to prostatic carcinoma is, however, extremely rare, typically occurring with advanced disease and widespread metastases.^{6,9} In contrast, hypercalcaemia is almost invariably present in parathyroid carcinoma, as non-functioning tumours are rare.^{10,11} There are a number of arguments against prostatic carcinoma as a cause for the bony lesions in our patient, including their lytic rather than sclerotic appearance and the distribution depicted on the Tc99m MDP bone scan. Brown tumours classically involve the facial bones, hands, pelvis, ribs and femurs,¹² while prostatic carcinoma typically metastasises to the spine where increased

osteoblastic activity results in the formation of new sclerotic bone.¹³

Nuclear imaging was particularly useful in our case, not only to demonstrate the brown tumours but also for localisation of the parathyroid tumour. Although surgical success in primary intervention for primary hyperparathyroidism exceeds 90% without localisation studies, localisation tests are essential for re-exploration. The sestamibi scan appears to be the most sensitive and accurate non-invasive test available today.¹⁴ Evidence suggests similar behaviour of parathyroid carcinoma and adenoma in technetium-MIBI scintigraphy.¹⁵⁻¹⁷ The sestamibi scan was used successfully in this patient to localise the tumour and guide surgery. Brown tumours may not only be detected, but also effectively followed up using sestamibi scintigraphy.¹⁸ This patient underwent limited-body sestamibi imaging which revealed areas of increased uptake corresponding to the brown tumours seen on plain radiography. It may be anticipated that these areas will disappear when repeat imaging is performed 9 months after successful treatment of his hyperparathyroidism. The whole-body Tc99m MDP bone scan could be used to monitor the response to surgery but could remain positive for up to a year postoperatively.

In view of the diverse biological behaviour reported for parathyroid carcinoma, prediction of prognosis for this patient is difficult. Long disease-free periods after surgery may precede recurrence, with shorter time intervals after repeated surgery.⁵ Mortality is related mainly to the inability to control hypercalcaemia.¹⁹ This patient's serum calcium level will therefore be closely monitored and repeat surgery considered in the event of recurrence.

1. Cordeiro AC, Montenegro FLM, Kulcsar MAV, *et al.* Parathyroid carcinoma. *Am J Surg* 1998; 175: 52-55.
2. Crescenzo DG, Shabahong M, Garvin D, Evans SR. Intrathyroidal parathyroid cancer presenting as a left neck mass. *Thyroid* 1998; 8: 597-599.
3. Park ST, Condemni G, Shakir KM, Larson D, Miller D, Ghosh BC. Parathyroid carcinoma: report of 3 cases and review of the literature. *Mil Med* 1998; 163: 246-249.
4. Obara T, Okamoto T, Kanbe M, Iihara M. Functioning parathyroid carcinoma: clinicopathologic features and rational treatment. *Semin Surg Oncol* 1997; 13: 134-141.
5. Favia G, Lumachi F, Polistina E, D'Amico DF. Parathyroid carcinoma: sixteen new cases and suggestions for correct management. *World J Surg* 1998; 22: 1225-1230.
6. Joe CA, Fiorica V. Parathyroid adenoma in patient with prostatic carcinoma and hypercalcaemia. *Urology* 1987; 30: 382-384.
7. George AL, Remler RB, Heim CR, Warner JJ. Hypercalcaemia in carcinoma of the prostate: case report and review of the literature. *J Urol* 1987; 137: 309-311.
8. Sandelin K, Auer G, Bondeson L, *et al.* Prognostic factors in parathyroid cancer: a review of 95 cases. *World J Surg* 1992; 16: 724-731.
9. Van Dijk JM. Hypercalcaemia in prostatic cancer: case report and review of the literature. *Am J Clin Oncol* 1993; 16: 329-331.
10. Holmes EC, Morton DI, Ketcham AS. Parathyroid carcinoma: a collective review. *Ann Surg* 1969; 169: 631-640.
11. Berland Y, Olmer M, Lebreuil G, Grisoli J. Parathyroid carcinoma, adenoma and hyperplasia in a case of chronic renal insufficiency on dialysis. *Clin Nephrol* 1982; 18: 154-158.
12. Basarab RM, Manni A, Harrison TS. Dual isotope subtraction parathyroid scintigraphy in the preoperative evaluation of suspected hyperparathyroidism. *Clin Nucl Med* 1985; 10: 300.
13. Mundy GR. Mechanics of bone metastasis. *Cancer* 1997; 80: 1546-1556.
14. Shaha AR, Sarkar S, Strashun A, Yeh S. Sestamibi scan for preoperative localisation in primary hyperparathyroidism. *Head Neck* 1997; 19: 87-91.
15. Sandrock D, Merino MJ, Norton JA, Neumann RD. Parathyroid imaging by Tc/Tl scintigraphy. *Eur J Nucl Med* 1990; 16: 607-613.
16. Kitapci MT, Tastekin G, Turgut M, *et al.* Preoperative localization of parathyroid carcinoma using Tc-99m MIBI. *Clin Nucl Med* 1993; 18: 217-219.
17. McHenry CR, Rosen IB, Walfish PG, Cooter N. Parathyroid crisis of unusual features in a child. *Cancer* 1993; 71: 1923-1927.
18. Pai M, Park CH, Kim B-S, Chung Y-S, Park H-B. Multiple brown tumors in parathyroid carcinoma mimicking metastatic bone disease. *Clin Nucl Med* 1997; 22: 691-694.
19. Shaha E, Bilezikian JP. Parathyroid carcinoma: a review of 62 patients. *Endocr Rev* 1982; 3: 218.