



PAINTBALL OCULAR INJURIES

L P Kruger, J K Acton

Introduction. Six cases of ocular injury following paintball injuries sustained during war games are described. A CO₂-powered rifle shoots a 14 mm plastic-coated paintball at participants. The muzzle velocity of the gun is 250 ft/sec (76 m/sec). Locally manufactured paintballs are harder than the more expensive imported varieties and may account for the severity of our reported injuries.

Method. Six patients presented to a retinal specialist with various ocular injuries, predominantly of the posterior pole.

Results. All patients were young males. There were no cases of ocular penetration. A variety of retinal pathologies was noted, with three cases requiring surgery; however this did not significantly improve the visual outcome.

Conclusions. These cases highlight the severe ocular injuries that may occur from paintball injuries. Recommendations to avoid ocular injury are made.

S Afr Med J 1999; 89: 265-268.

The purpose of this report is to detail 6 cases of serious ocular injury following paintball injuries sustained during war games.

In the war game two teams of 20 - 50 players each try to capture the opponents' flag. Camouflaged players 'kill' the enemy by shooting them with a carbon dioxide-powered repeater gun.^{1,2} The 'game' is played following instructions and the issuing of protective eyewear.

The gun shoots a 14 mm coloured 'bullet' that in the USA is made of gelatin, glycerin, water, coloured dyes, polyethyleneglycol and titanium oxide.¹ These bullets are layered with a semi-soft coating and are intended to shatter on impact, marking the item that is hit. However, owing to the costs of importation, locally made paintballs with a plastic coating are manufactured in South Africa. This coating is considerably harder than the American variety (Inspector A Rosenberg, South African Police Services ballistics expert — personal communication). The muzzle velocity of the gun is set at about 250 ft/sec or 76 m/sec.

In this game the participants are able to enjoy simulated combat situations in a competitive setting. The literature on non-powder firearm-related ocular injuries reflects an increase in the number and severity of ocular injuries that have been occurring. As in a true war setting such as Operation Desert Storm, the eye is especially vulnerable to serious injury from particles that might minimally affect other sites of the body.³

CASE REPORTS

We report on paintball injuries occurring in 6 patients between 1993 and 1995. The patients were referred by a general practitioner or general ophthalmologist to a retinal specialist. A profile of the type of injury to the posterior segment of the eye emerges.

Case 1

A 13-year-old male scholar presented, having shot himself in the right eye. He was initially treated by a general ophthalmologist. He was referred after 45 days for an opinion, with persistent loss of central vision. On presentation he had a visual acuity of 0.05 OD. On examination the anterior segment and intra-ocular pressure were found to be normal. In the posterior segment he had extensive chorioretinal atrophy and evidence of old subretinal haemorrhage involving the macula (Fig. 1). No further treatment was indicated and a poor prognosis for improvement in visual acuity was expected.

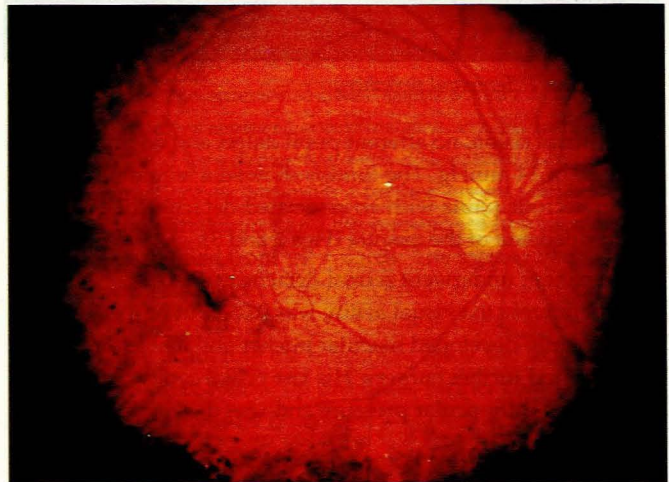


Fig. 1. Case 1. Chorioretinal atrophy.

Case 2

A 20-year-old male student presented with an ocular injury despite wearing protective goggles. The projectile had entered adjacent to the airhole of the goggles. He had presented with count fingers vision OD and was initially treated for a conjunctival laceration and hyphaema. The intra-ocular pressure remained at 20 mmHg. On presentation for a retinal opinion 3 days after the injury, he was noted to have hand

22 Hocky Ave, Northcliff, Johannesburg

L P Kruger, FRCS, FRC Ophth

Department of Ophthalmology, University of Stellenbosch and Tygerberg Hospital, Tygerberg, W Cape

J K Acton, FCS (SA) Ophth

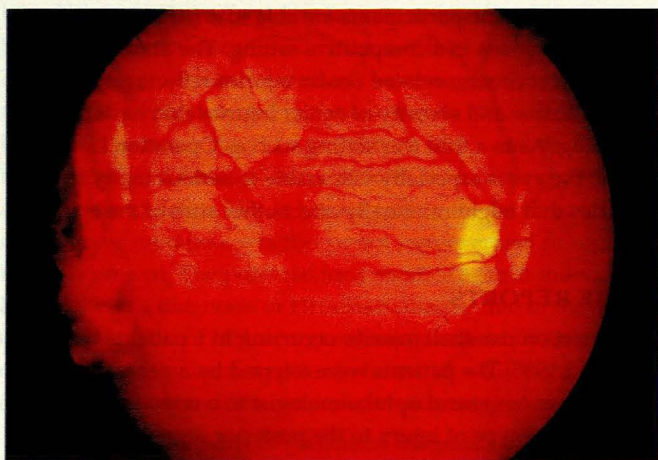


Fig. 2. Case 2. Posterior pole.

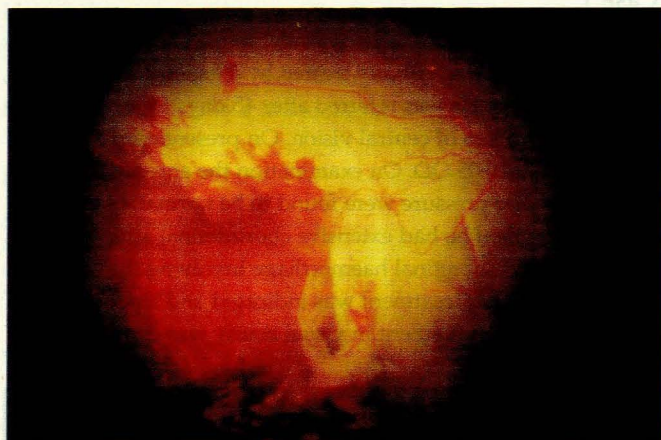


Fig. 3. Case 2. Temporal periphery.

movements vision, no afferent pupil defect and an intra-ocular pressure of 14 mmHg. The fundus showed a temporal giant tear in necrotic retina with an associated detachment and Berlin's oedema of the macula (Figs 2 and 3).

The patient underwent retinal detachment repair. Postoperatively the visual acuity was 0.05, but he subsequently developed macular pucker and a hole (Fig. 4) that required further surgery. His last visual acuity was 0.1. He had normal intra-ocular pressure and was developing a cataract.

Case 3

A 14-year-old male scholar presented following a self-inflicted injury after looking down the barrel of his gun. At presentation he had visual acuity of 1.0 OD with a contusion of the upper lid. There was an inferior vitreous haemorrhage in the posterior segment and the rest of the fundus was normal. He did not return for further follow-up.

Case 4

A 16-year-old male scholar was referred after 9 days, having

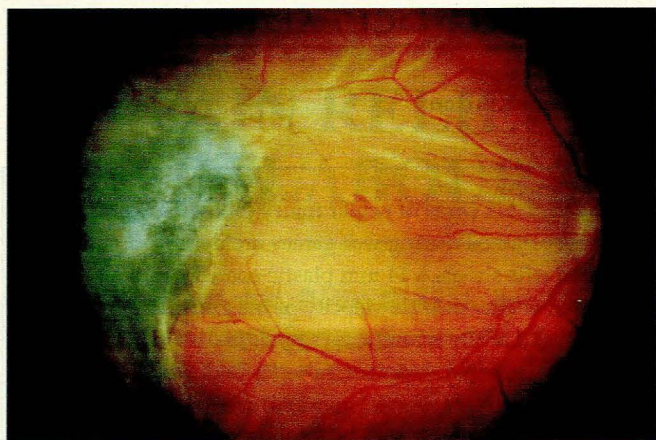


Fig. 4. Case 2. Macular pucker and hole.

initially been treated for a hyphaema. His visual acuity was 0.16 OD. The fundus showed a vitreous haemorrhage with a large retinal tear temporally, with the edges elevated. Significant traction was not suspected and the break was lasered. This was repeated, by which time the vision was 0.2. He subsequently developed macular pucker that became vascularised (Fig. 5), as demonstrated on fluorescein angiography (Figs 6 and 7). This required surgery and at the last follow-up after 696 days the intra-ocular pressure was 23 mmHg, necessitating treatment. The best corrected visual acuity was 0.2.

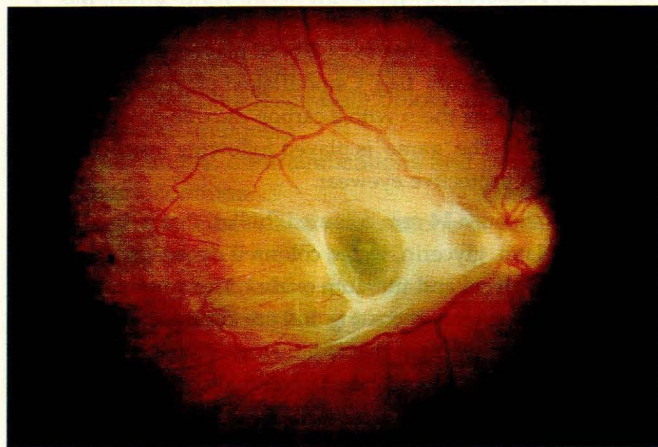


Fig. 5. Case 4. Vascularised macular pucker.

Case 5

A 26-year-old male student presented following an injury sustained at tactical war games 3 years previously. On examination he had a visual acuity of 0.5 OS, an intra-ocular pressure of 9 mmHg and a subfoveal choroidal rupture without clinical evidence of a choroidal neovascular membrane (Fig. 8).

Case 6

A 25-year-old male builder was referred, following initial

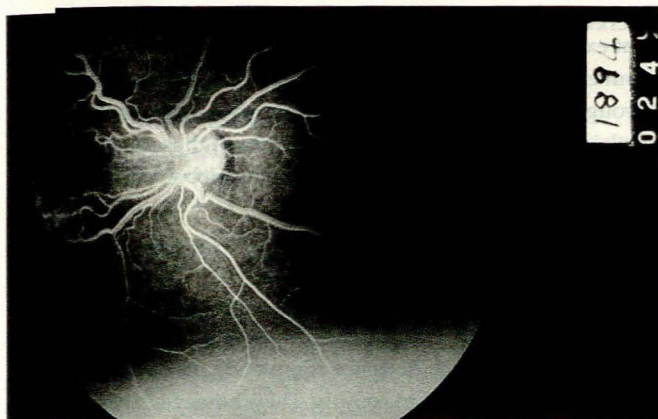


Fig. 6. Case 4. Early phase of fluorescein angiogram.

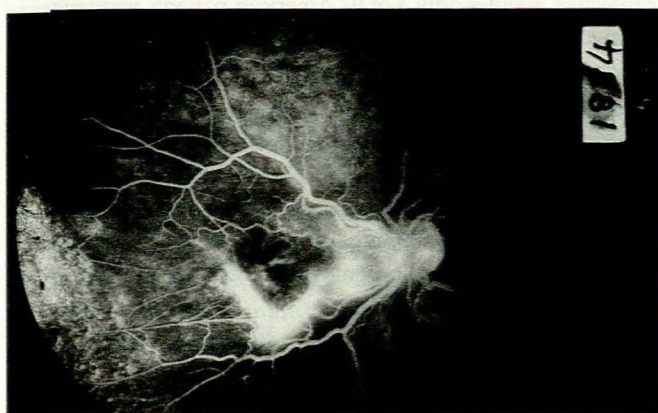


Fig. 7. Case 4. Late phase of fluorescein angiogram.

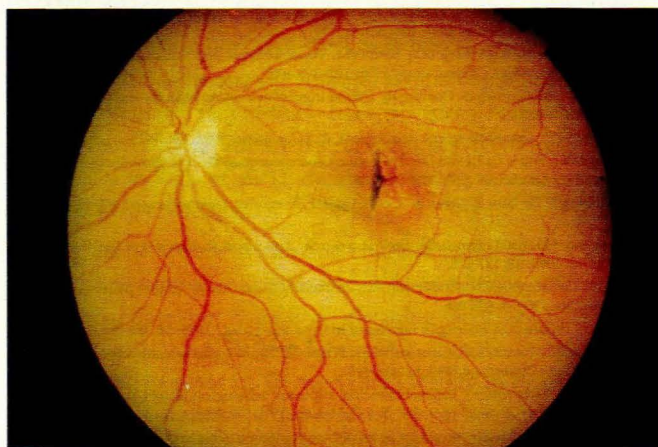


Fig. 8. Case 5. Subfoveal choroidal rupture.

treatment, with pain and decreased vision. He had been injured 27 days previously. On examination, the affected eye had hand movements vision OD. There was corneal oedema, and a dislocated, cataractous, leaking lens with an active anterior segment. There was no fundal view. B-scan ultrasonography revealed Berlin's oedema of the retina, which was attached. The intra-ocular pressure was 10 mmHg. Following treatment

with steroids topically and subconjunctivally, surgery was performed. At surgery, a horseshoe break associated with a superotemporal retinal detachment was noted. The retinal detachment repair was completed, and at the last follow-up (364 days) the intra-ocular pressure was 20 mmHg. The retina was attached but a persistent bullous keratopathy necessitated referral for penetrating keratoplasty.

DISCUSSION

These patients have a similar profile to other patients who have sustained airgun-related injuries, viz. all were young males, with an average age of 18.8 years (range 13 - 26 years).

All the patients had previously had normal eyes. In 5 of the 6 cases the right eye had been injured, and in 2 cases the injury was self-inflicted when the patient looked down the gun. One patient was injured despite wearing his protective goggles (a similar case is reported in the literature⁴). The remaining patients had removed their protective gear for various reasons and had been 'attacked'.

These case reports illustrate the serious nature of the injuries, except for 1 case where the initial impact was against the lid (case 3). Also of note was that initial visual acuity was a good predictor of final outcome, with only mild improvements occurring, this despite surgical intervention in 3 cases. A similar finding was noted in a study attempting to identify predictors of ocular survival and final visual acuity after ocular trauma. It was found that significant predictors included the initial visual acuity and the mechanism of injury. Blunt and missile injury had a poor prognosis.⁵

In reviewing the anterior segment injuries, only 1 patient had significant anterior segment complications, viz. bullous keratopathy and lens disruption with dislocation. A hyphaema was present in 2 cases, although a further 2 were seen some time after the initial injury and the presence of hyphaema could not be verified from the records. The intra-ocular pressure was elevated in 1 patient (case 4) at follow-up, in fact the longest follow-up (696 days). This was due to angle recession. In considering the remaining cases, the lack of sufficient length of follow-up precludes further comment on the intra-ocular pressure outcomes.

In reviewing the posterior segment, it was noted that 4 of the 6 patients had vitreous haemorrhages of varying degrees. The remaining 2 patients were seen 6 weeks and 3 - 5 years after injury, and the presence of an initial vitreous haemorrhage could therefore not be verified from the records. A variety of retinal lesions was present in this series, similar to those mentioned in the literature,^{6,7} although no dialyses were noted in these cases. Although surgery was required in 3 cases it did not significantly improve the visual outcome.

Ocular trauma is a significant cause of blindness. The devastating effects of ocular injuries from airguns are well



known and have been comprehensively documented in the medical literature.^{3,6,8-11} A review of the literature reveals that the vast majority of these cases of trauma are due to 'BB's or pellets from airguns, and are mainly penetrating injuries. There were no cases of ocular penetration in our series of paintball injuries sustained during tactical war games. The last report of airgun-related ocular injuries in South Africa was in 1978 when Sevel and Atkins¹² surveyed pellet-gun injuries nation-wide and considered steps to reduce the occurrence of these injuries.

The earliest study of war-game injuries is from Easterbrook and Pashby.¹ They reported on 44 ocular injuries by the end of 1987, with only 14 recovering to 20/20 vision, and 17 left legally blind. In a further 13 cases the final visual acuity was less than 20/40. None of their patients was wearing goggles at the time of injury. Their article was followed by further case reports.^{2,4,13}

Clues to the pathophysiology of the posterior segment findings can be found in studies by Johnston⁷ and Wood and Richardson.¹⁴ Johnston reviewed a series of traumatic retinal detachments following ocular contusion. His series included the following types of retinal breaks: oral dialyses; irregular breaks in necrotic retina, of which immediate retinal detachment is a feature; horseshoe breaks and giant tears.

Blunt object injury causes direct damage at the site of impact, and indirect injury by transmitted forces causes damage at distant intra-ocular sites. This has been well recognised as a cause of rhegmatogenous retinal detachment.⁷ Experimental evidence has shown that retinal breaks occur at the moment of ocular impact.⁷ Although we noted no dialyses, a giant tear within necrotic retina (case 2) was noted as well as retinal breaks including horseshoe tears.

Necrotic breaks have been discussed by Cox.¹⁵ They result from direct concussion damage to the retina and represent impact necrosis. Fluorescein angiography has confirmed the retinal vascular damage and disintegration of capillary walls with marked ischaemia and outpouring of fluid.

Choroidal ruptures due to blunt trauma have also been studied in the literature. In the study by Wood and Richardson¹⁴ a distinction between diffuse and focal-impact injuries and their resultant pattern of choroidal ruptures are discussed. The paintball injuries of our series may fall between the two patterns described due to the size of the projectile (relatively large), but with a significant velocity at close range. In the posterior segment of our cases features of both focal type, severe impact causing retinal impact necrosis (case 2) and diffuse-type impact causing choroidal ruptures, peripapillary in nature (case 5), occurred.

Wood and Richardson's discussion highlights the difficulties with the theory of the contrecoup mechanism of injury. Concussional injuries occur due to the effect of trauma at the site of impact or from the transmitted force effect. The authors suggest that their pattern of choroidal ruptures in focal injuries

(as in case 5) does not fit with a contrecoup mechanism and that experimental work on pigs suggests that injury results from energy transmission via the walls of the globe and not through contrecoup injury.¹⁴ Contrecoup theory may therefore explain skull/brain-related injuries but not those sustained by a resilient deformable sphere such as the globe.

CONCLUSION

Our cases highlight the severe ocular injuries that may occur in a sport such as 'war games'. Despite the injunction to wear protective gear, which does not completely preclude ocular injury, participants fail to comply. They, however, are not alone, as a report of ocular injuries from Operations Desert Shield and Desert Storm indicated that despite having been issued with protective goggles only 3 of 92 American patients were wearing them at the time of injury.³

Recommendations that would assist in reducing the occurrence of ocular injuries include protective goggles (made of polycarbonate) to be worn at all times; no shooting towards the head or at close range; and alcohol and drugs to be forbidden before and during the game. Participants in paintball war games need to remember that an injury which would be trivial elsewhere in the body may be serious when it affects the eye.

References

1. Easterbrook M, Pashby TJ. Ocular injuries and war games. *Int Ophthalmol* 1988; **28**: 222-224.
2. Ryan EH, Lissner G. Eye injuries during 'war games'. *Arch Ophthalmol* 1986; **104**: 1435-1436.
3. Heier JS, Enzenauer RW, Wintermeyer SF, et al. Ocular injuries and diseases at a combat hospital in support of Operations Desert Shield and Desert Storm. *Arch Ophthalmol* 1993; **111**: 795-798.
4. Martin PL, Magolan JJ, Raleigh NC. Eye injury during "war games" despite the use of goggles. *Arch Ophthalmol* 1987; **105**: 321-322.
5. Esmali B, Elnor SG, Schork MA, Elnor VM. Visual outcome and ocular survival after penetrating trauma. *Ophthalmology* 1995; **102**: 393-400.
6. Moore AT, McCartney A, Cooling RJ. Ocular injuries associated with the use of airguns. *Eye* 1987; **1**: 422-429.
7. Johnston PB. Traumatic retinal detachment. *Br J Ophthalmol* 1991; **75**: 18-21.
8. Schein OD, Enger C, Tielsch JM. The context and consequences of ocular injuries from air guns. *Am J Ophthalmol* 1994; **117**: 501-506.
9. Sternberg P, De Jaun E, Green WR, et al. Ocular BB injuries. *Ophthalmology* 1984; **91**: 1269-1277.
10. Lawrence HS. Fatal nonpowder firearm wounds: case report and review of the literature. *Pediatrics* 1990; **85**: 177-178.
11. Sharif KW, McGhee CNJ, Tomlinson RC. Ocular trauma caused by airgun pellets: a ten year survey. *Eye* 1990; **4**: 855-866.
12. Sevel D, Atkins AD. Pellet gun injuries of the eye. *S Afr Med J* 1978; **54**: 566-568.
13. Marmalis N, Monson MC, Farnsworth ST, White GL. Blunt ocular trauma secondary to "war games". *Ann Ophthalmol* 1990; **22**: 416-418.
14. Wood CM, Richardson J. Indirect choroidal ruptures: aetiological factors, patterns of ocular damage, and final visual outcome. *Br J Ophthalmol* 1990; **74**: 208-211.
15. Cox MS. Retinal breaks caused by blunt non-perforating trauma at the point of impact. *Trans Am Ophthalmol Soc* 1980; **78**: 414-466.

Accepted 1 May 1998.