

Evaluation of reflux oesophagitis with technetium-99m-labelled sucralfate

J. H. van Zyl, M. G. Nel, A. C. Otto,
H. de K. Grundling, E. Reinecke, J. M. Botha

Sucralfate binds with denuded protein to form a stable complex to protect the damaged mucosa. By utilising this property, technetium-99m-labelled sucralfate can be used to demonstrate ulceration in the upper gastro-intestinal tract.

Aim. The aim of this study was to evaluate ^{99m}Tc-labelled sucralfate in the diagnosis of grade II - III reflux oesophagitis.

Methods. Ten patients with endoscopic proof of grade II - III reflux oesophagitis and 10 patients with normal findings on oesophagoscopy were evaluated after they had swallowed 5 ml ^{99m}Tc sucralfate. Radionuclide imaging was done until activity in the oesophagus had ceased.

Results. Retention of activity from 10 minutes up to 1¹/₂ hours could be demonstrated in 9 patients with endoscopically proven oesophagitis. In the control group complete clearance of activity was seen in 7 patients. Gastro-oesophageal reflux could be demonstrated in 4 patients.

Conclusion. ^{99m}Tc sucralfate is a sensitive and specific method for the non-invasive diagnosis of oesophagitis compared with endoscopy.

S Afr Med J 1996; **86**: 1422-1424.

Sucralfate is an aluminium salt of a sulphated disaccharide that becomes viscous and adhesive in diluted acid. This property enables it to form stable complexes with protein by way of strong electrostatic interactions. The therapeutic effect of sucralfate involves its binding to protein to protect denuded mucosa.¹

Sucralfate can be labelled with technetium-99m, which is optimal for gamma camera imaging and thus a non-invasive method of demonstrating ulceration in the upper gastro-intestinal tract.² Peptic ulcer disease and inflammatory

Departments of Internal Medicine (Division: Gastroenterology),
Nuclear Medicine and Biophysics, University of the Orange Free
State, Bloemfontein

J. H. van Zyl, M.B. CH.B., M.MED. (INT.) GASTROENTEROL.

M. G. Nel, M.B. CH.B.

A. C. Otto, M.B. CH.B., M.MED. (INT.), M.SC. (NUCL. MED.)

H. de K. Grundling, M.B. CH.B., M.MED. (INT.) GASTROENTEROL.

E. Reinecke, NAT. DIP. NUCL. MED.

J. M. Botha, M.SC. (CHEM.)

bowel disease were previously demonstrated with radio-labelled sucralfate,^{3,4} yet information about sucralfate retention with gastro-oesophageal reflux and oesophagitis is limited.⁵

The aim of our study was to evaluate ^{99m}Tc sucralfate retention in grade II - III reflux oesophagitis. This non-invasive technique was compared with endoscopy results.

Patients and methods

Twenty patients with symptoms of oesophageal reflux who had been referred for gastroscopy were studied. The study group consisted of 10 patients with endoscopically proven grade II - III oesophagitis (8 men, 2 women, mean age 49.9 years, range 21 - 81 years). Two of these patients had hiatus hernia as well. The control group consisted of 10 patients without oesophagitis on endoscopy, but 5 of them had hiatus hernia (6 men, 4 women, mean age 51.4 years, range 31 - 73 years). Patients on antisecretory drugs, mucosal protectives, anticholinergics, prokinetics, calcium antagonists, nitrates and those who had had anti-reflux surgery or gastrectomy were excluded from the study. Informed written consent was obtained from all persons before enrolment. The protocol was also approved by the local ethical and radiation control committees.

In all patients routine gastroscopy and grading were done by two experienced endoscopists according to the Savary Millar classification. ^{99m}Tc human serum albumin (^{99m}Tc HSA) sucralfate was locally prepared according to the method originally described by Vasquez *et al.*² with certain modifications. Three hundred and seventy (370) MBq ^{99m}Tc-pertechnetate with 2.5 ml saline were added to 10 mg HSA and thoroughly mixed. After 10 minutes 5 ml sucralfate suspension were added, again thoroughly mixed and left standing for another 10 minutes. Quality control was by means of paper chromatography (acetone/saline — 9:1). The patient was asked to swallow 5 ml (148 MBq) of labelled suspension after an overnight fast. To exclude possible mucosal irritation caused by oesophagoscopy, the sucralfate scan was done after 24 hours.

Radionuclide imaging was done in the upright position with a gamma camera with a large field of view fitted with a low-energy all-purpose collimator to include the anterior view of the oesophagus and upper gastro-intestinal tract. Initially a dynamic acquisition, including 42 views of 2 seconds each, was performed. Static images were subsequently obtained at 5, 15, 30, 60 and 90 minutes. Visual interpretation of the ^{99m}Tc sucralfate scans was done blindly by two different

experienced observers. Cessation of activity in the oesophagus during the dynamic phase (84 seconds) was considered normal (Fig. 1). Retention of oesophageal activity from 10 minutes onwards was considered abnormal (Fig. 2). Oesophageal reflux during the 90-minute period was seen as intermittent activity with higher intensity (Fig. 3).




Fig. 2. Study of retention of activity.




Fig. 3. Study with retention of activity and episodic reflux. (Note the difference in intensity of the column of reflux at various times.)

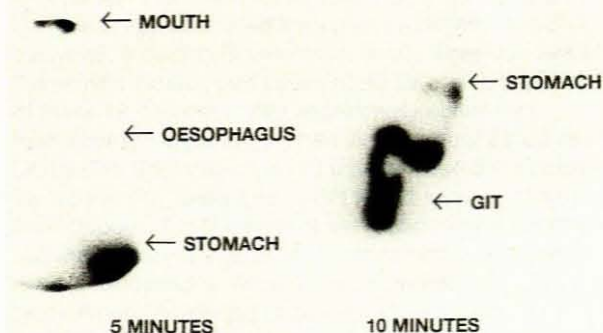


Fig. 1. Normal study.

Sensitivity and specificity of ^{99m}Tc -labelled sucralfate retention were determined using the endoscopy results as standard.

Results

The labelling efficiency of ^{99m}Tc to sucralfate was higher than 90% in all cases. The results of the study are given in Table I.

Table I. Results

Group A (grade II - III oesophagitis)			
Patient No.	Endoscopic results	^{99m}Tc reflux	^{99m}Tc retention (min)
1	Grade II	-	0
2	Grade II	-	10
3	Grade II	-	10
4	Grade II	-	10
5	Grade II + HH	+	90
6	Grade II + HH	+	30
7	Grade III	-	10
8	Grade III	-	60
9	Grade II	-	10
10	Grade III	+	90

Group B (no oesophagitis)			
Patient No.	Endoscopic results	^{99m}Tc reflux	^{99m}Tc retention (mins)
1	N + HH	+	0
2	N + HH	+	0
3	N + HH	-	30
4	N	-	0
5	N + HH	-	30
6	N	-	0
7	N	+	0
8	N	-	0
9	N + HH	+	30
10	N	-	0

HH = hiatus hernia; N = normal.

In the study group 9 out of 10 patients with endoscopically proven oesophagitis showed abnormal (> 10 minutes) retention of activity, i.e. a sensitivity of 90%. In two of the positive cases, a hiatus hernia was present and both patients showed reflux as well. Since the study group included only 3 patients with grade III oesophagitis, no correlation with retention time was attempted.

In the control group, 3 patients showed false-positive retention, but all of them had hiatus hernia, i.e. a specificity of 70%. In normal people the specificity was 100% without hiatus hernia.

Discussion

The pharmacological binding of sucralfate to protein of inflamed or denuded mucosa, forms the basis for this study. Labelling of sucralfate with ^{99m}Tc does not change this feature.^{3,4}

Conventional barium swallow is an accepted technique to detect oesophagitis. Endoscopy is the gold standard to

diagnose oesophagitis, but is invasive and has limitations in respect of repeatability and certain clinical situations, e.g. bleeding tendencies, HIV-positive patients and small children.⁵

We found a high sensitivity and specificity for detection of oesophagitis with this non-invasive technique. In the absence of hiatus hernia, the specificity was even higher. It is safe, repeatable and comfortable, with low risk and low radiation; the total body radiation is 0.98 mSv in comparison with a barium swallow total body radiation of 3.83 mSv. It is also inexpensive. Oesophageal reflux is often detected at the same time.

The technique may find specific application in the therapeutic follow-up of patients with oesophagitis as well as those in whom endoscopy is difficult or contraindicated.

Conclusion

In conclusion we found ^{99m}Tc sucralfate to be a more sensitive and specific method for the non-invasive diagnosis of grade II - III oesophagitis when compared with endoscopy.

REFERENCES

- Nagashima R. Development and characteristics of sucralfate. *J Clin Gastroenterol* 1981; **3**: 147-152.
- Vasquez TE, Evans DG, Hartman MT, Hagan P, Fardin M, Ashburn WC. Radionuclide imaging using technetium 99m-labelled sucralfate and potassium sucrose sulfate to detect gastric and duodenal ulcers. *J Nucl Med Allied Sci* 1986; **30**: 141-142.
- Dawson DJ, Khan AN, Miller V. Detection of inflammatory bowel disease in adults and children: Evaluation of a new isotope technique. *BMJ* 1985; **291**: 1227-1230.
- Vasquez TE, Pretorius HT, Greenspan G. Radiolabelled sucralfate: A review of clinical efficacy. *Nucl Med Comm* 1987; **8**: 327-334.
- Vasquez TE, Bridges RI, Braunstein P, Jansholt A, Meshkinpour H. Work in progress. Gastrointestinal ulcerations: Detection using a technetium 99m labelled ulcer avid agent. *Radiology* 1983; **148**: 227-231.
- Wynchank S, Mann MD. Scintigraphy and gastro-oesophageal disease. *S A Family Practice* 1995; **16**: 586-587.

Accepted 30 July 1996.