

SHORT REPORT

Paradoxical symmetry of the chest in neonates — a new clinical sign in the diagnosis of a unilateral pneumothorax

Suzanne D. Delport

Paradoxical symmetry of the chest in neonates is a new clinical sign of pneumothorax which, together with hyperresonancy, facilitates the undelayed diagnosis of this life-threatening condition.

S Afr Med J 1996; 86: 1465-1466.

A prompt clinical diagnosis of pneumothorax in a neonate is of the essence. Reliance on a chest radiograph for the diagnosis will delay drainage of the extrapulmonary air and may have fatal consequences. The clinical signs indicative of pneumothorax in a neonate are well described¹ and include: (i) hyperresonancy of the ipsilateral hemithorax; (ii) contralateral displacement of the mediastinum, involving the trachea and apex beat; (iii) downward displacement of the liver in the event of a right-sided pneumothorax; (iv) abdominal distension; (v) decreased breath sounds over the ipsilateral hemithorax; and (vi) hypertension and tachycardia followed by hypotension, bradycardia, shock and death. Of these signs, the most reliable is increased resonancy. Downward displacement of the liver is also a reliable clinical sign but occurs only in the event of a right-sided pneumothorax. Decreased breath sounds on the ipsilateral side and displacement of the trachea and apex beat are difficult to detect, especially in premature infants.

A new clinical sign, paradoxical symmetry, is described. A normal neonate invariably lies with its neck rotated so that its head is turned to one side.² Rotation of the neck causes the hemithorax on the side to which the head is turned to be less prominent than on the other side (Figs 1 and 2). The degree of asymmetry will vary, depending on the angle which the examiner's line of vision forms with the surface of the chest (Figs 1 and 2). The degree of asymmetry will become more obvious if the examiner views the chest from the foot end of the bed and the line of vision is aligned with the surface of the neonate's chest (Fig. 2). Absolute symmetry of the chest will return if the head of the infant is placed centrally (Fig. 3). The radiological appearance of the chest in the presence of neck rotation shows that the intercostal spaces on the side to which the head is turned

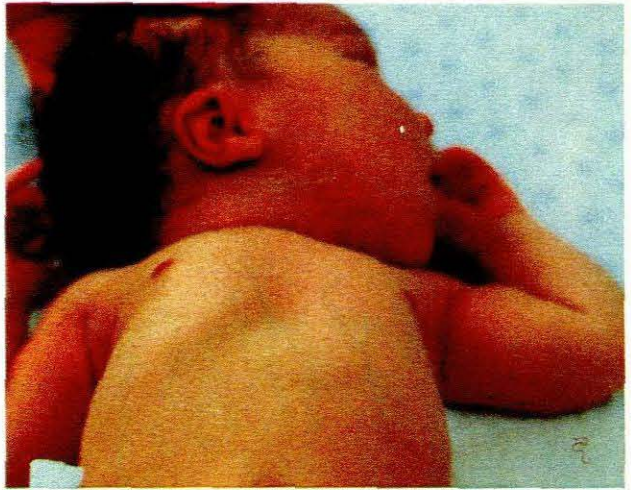


Fig. 1. Normal asymmetry of the chest with rotation of the neck. The hemithorax on the side to which the head is turned is less prominent than the other side.

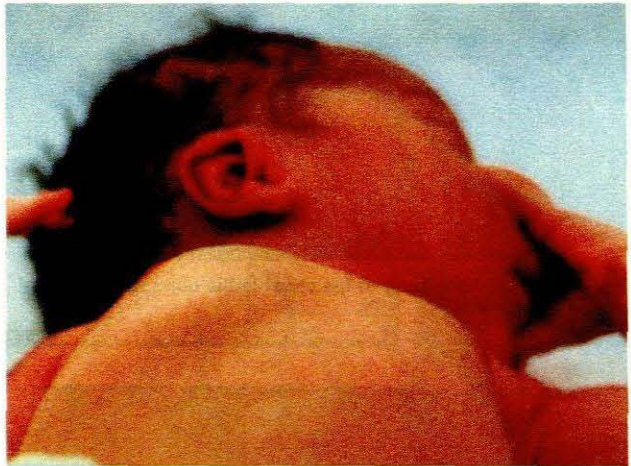


Fig. 2. The normal asymmetry of the chest with neck rotation becomes more pronounced if the examiner's line of vision from the foot end of the bed approaches the surface of the chest.

are narrow compared with the contralateral side (Fig. 4).

The mechanism by which rotation of the neck produces asymmetry of the rib cage in normal neonates is not known. It has been suggested (M. Klein — personal communication) that rotation of the neck stretches the sternocleidomastoid muscle on the side opposite to that to which the head is turned, giving that muscle a mechanical advantage over the sternocleidomastoid muscle on the other side in its action on the rib cage.

Symmetry of the chest in a neonate lying with its head to one side is not an expected clinical finding and can be described as paradoxical symmetry. This finding indicates that the hemithorax on the side to which the head is turned is as prominent as the contralateral side, which is contrary to the norm. The visual perception of paradoxical symmetry in the presence of neck rotation can be confirmed by turning the infant's head to the other side, in which case depression of the hemithorax on that side should be present.

Department of Paediatrics, University of Pretoria and Kalafong Hospital, Pretoria

Suzanne D. Delport, M.B. CH.B., M.MED. (PAED.), M.PHARM.MED., PH.D.

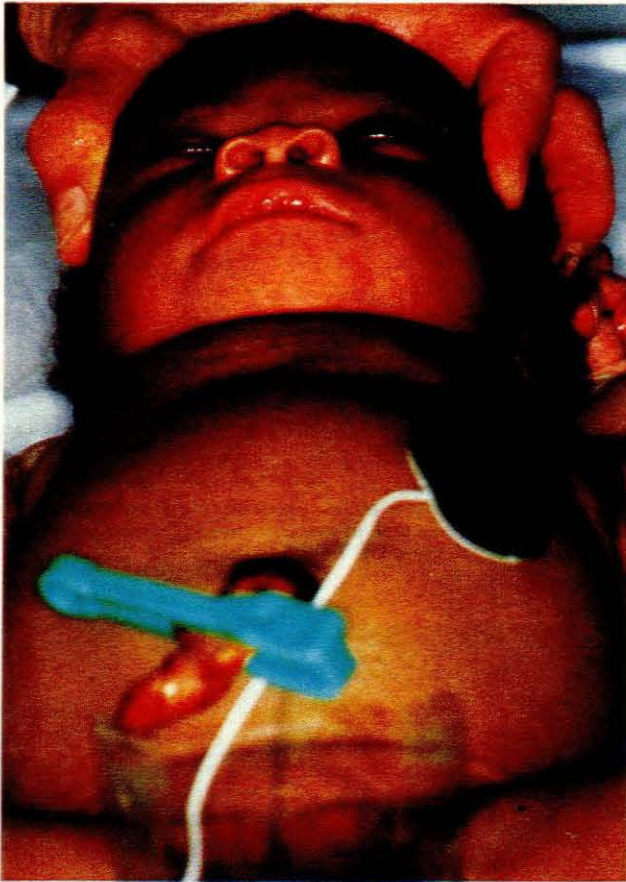

Fig. 3. Absolute symmetry of the chest is the norm with the head placed centrally.

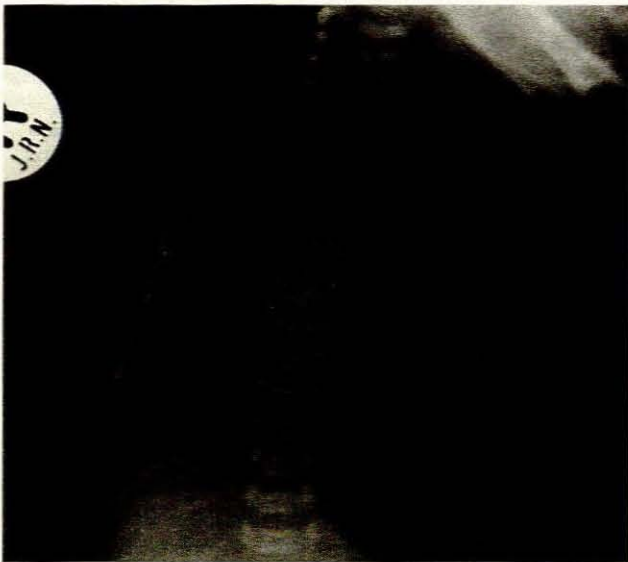

Fig. 4. The radiographic appearance of the chest with the neck rotated to the left. Crowding of the ribs is present on the left, the side to which the head is turned.

Clinical application

Paradoxical symmetry of the chest in a neonate has been found to be a useful clinical sign of a unilateral pneumothorax. The latter is a space-occupying condition which abolishes the normal asymmetry of the chest. The hemithorax on the side of the pneumothorax becomes as prominent as the contralateral side if the head is turned to the side of the pneumothorax — the neonate will therefore be looking to the side of the abnormality. If hyperresonancy is elicited, the presence of a pneumothorax must be considered.

Other unilateral space-occupying conditions which should also lead to paradoxical symmetry of the chest in neonates are lobar emphysema, hydrothorax, haemothorax, chylothorax and masses. However, these conditions are rare and occur less commonly than a pneumothorax.

I thank Professor Steve Rossouw for his expert photographic assistance.

REFERENCES

1. Hodson WA, Truog WE. Principles of management of respiratory problems. In: Avery GB, Fletcher M, MacDonald MG, eds. *Neonatology*. Philadelphia: JB Lippincott, 1994: 496-497.
2. Volpe JJ. Normal neurological examination. In: Volpe JJ, ed. *Neurology of the Newborn*. Philadelphia: WB Saunders, 1987: 78.

Accepted 17 July 1996.