

A prospective study of electrical cardioversion for sustained tachycardias by emergency unit personnel

M. J. van der Watt, A. A. Aboo, R. N. Scott Millar

Acute symptomatic tachyarrhythmias are commonly seen by emergency unit personnel. Electrical cardioversion is often used at Groote Schuur Hospital to treat such patients because of concerns about the safety and efficacy of intravenous anti-arrhythmic agents. All patients presenting with acute symptomatic tachyarrhythmias who were managed only by the staff of the Emergency Unit were entered into the study to assess the efficacy and safety of direct current (DC) cardioversion. Those with sinus tachycardia or atrial fibrillation of more than 24 hours' duration were excluded. Staff, on joining the unit, were instructed in the use and technique of DC cardioversion, and given simple guidelines for the management of acute tachyarrhythmias.

Fifty-three patient events were seen over a period of 16 months: 7 patients had ventricular tachycardia, 21 had atrial flutter, 20 had paroxysmal junctional re-entry tachycardia, 4 had atrial fibrillation and 1 had multifocal atrial tachycardia. Fifty-two were successfully converted to sinus rhythm. One patient with atrial flutter and 9 with paroxysmal junctional re-entry tachycardia reverted after undergoing vagal manoeuvres or receiving intravenous verapamil. Of the remaining 43 patients, 42 (98%) were cardioverted with synchronised DC shock under midazolam sedation (7/7 ventricular tachycardia, 20/20 atrial flutter, 11/11 paroxysmal junctional re-entry tachycardia, 4/4 atrial fibrillation, 0/1 multifocal atrial tachycardia). Four patients had their sedation electively reversed with flumazenil. No complications occurred. DC cardioversion was only considered inappropriate in the 1 patient with multifocal atrial tachycardia.

This study shows that if simple guidelines are followed, non-cardiologist junior medical personnel can safely and effectively manage sustained, acute, symptomatic tachyarrhythmias by employing DC cardioversion as and when appropriate.

S Afr Med J 1995; **85**: 508-511.

Emergency Unit and Cardiac Clinic, Department of Medicine,
University of Cape Town and Groote Schuur Hospital, Cape Town

M. J. van der Watt, F.C.P. (S.A.) (Present address: Royal Postgraduate
Medical School, Ducene Road, London)

A. A. Aboo, F.C.P. (S.A.)

R. N. Scott Millar, F.C.P. (S.A.)

Synchronised direct current (DC) cardioversion has been used extensively in the management of cardiac tachyarrhythmias since Lown *et al.*¹ introduced this mode of therapy in 1962. However, this procedure is viewed with some trepidation and wariness by junior medical staff. Furthermore, with the advent of a wide variety of anti-arrhythmic medication, and the ready availability of experienced cardiological staff at most major hospitals, this procedure appears to be seldom used by junior staff in the emergency room setting.

Of concern is the ever-growing number of reports of serious complications associated with the use of anti-arrhythmic medication in the management of acute tachyarrhythmias.²⁻⁴ These have occurred most commonly when verapamil has been administered to patients with ventricular tachycardia or in those with Wolff-Parkinson-White syndrome complicated by atrial fibrillation.⁵ In view of similar experience at Groote Schuur Hospital, a policy was introduced some years ago whereby emergency unit staff managed acute symptomatic tachyarrhythmias in patients presenting to the emergency department, using DC cardioversion as first-line therapy in wide-complex tachycardia, atrial flutter, and in patients with haemodynamically unstable tachyarrhythmias.

A review of the literature revealed no prospective study in which this approach had been tested or examined. We therefore undertook a prospective study of patients presenting to the emergency department of our hospital with acute, symptomatic sustained tachyarrhythmias. The aim thereof was to determine the efficacy and safety of direct current cardioversion when used by non-cardiological junior staff in the treatment of patients presenting with acute symptomatic tachyarrhythmias at a general emergency unit in a large teaching hospital.

Patients and methods

Those patients presenting to the Emergency Unit with acute symptomatic sustained tachyarrhythmias who were managed exclusively by Emergency Unit staff were entered into the study. Patient demographics were recorded, along with specific details of presenting and past complaints, current medication, blood pressure, pulse rate, clinical assessment of organ perfusion, presence of congestive cardiac failure, ECG rate and complex width, presumptive diagnosis, vagal manoeuvres, drug treatment, sedation type and dose, number and energy levels of direct current countershocks given, outcome, complications, comments and clinical state post-cardioversion. These were recorded on a simple preprinted form and analysed at the end of the study. ECGs were subsequently reviewed by a cardiologist (R.N.S.M.). Medical staff working in the Emergency Unit were instructed in the appropriate use and technique of DC cardioversion and were given simple guidelines for the management of acute tachyarrhythmias.

Two tutorials were given by a cardiologist (R.N.S.M.) in which the principles of diagnosis and management of common arrhythmias were stressed. These were repeated every 6 months. The technique of synchronised DC cardioversion was taught to each new doctor who joined the Emergency Unit by the physician in charge (A.A.A.) or other

permanent staff members. Table I lists the main features of the common sustained tachycardias that the staff were taught to recognise. Patients presenting with haemodynamically unstable tachyarrhythmia, any wide-complex tachycardia or atrial flutter were managed with DC cardioversion (Fig. 1). Patients with haemodynamically stable tachycardia thought to be due to paroxysmal junctional re-entry were managed initially with vagal manoeuvres (carotid sinus massage and/or Valsalva manoeuvre). When this was unsuccessful, 5 - 10 mg verapamil were given intravenously. If the tachycardia persisted, the patient was electrically cardioverted. Patients with atrial fibrillation were managed according to the underlying condition. Only patients with acute (< 24 hours), haemodynamically unstable atrial fibrillation were electrically cardioverted.

Table I. Principal features used to teach tachycardia diagnosis to emergency unit personnel

Wide-complex tachycardia (QRS 0,12 s or greater)	Ventricular tachycardia
Narrow-complex tachycardias	
Irregular, no P waves	Atrial fibrillation
Regular with P waves visible before each QRS (blocked P wave in ST segment or hidden by QRS)	Atrial flutter
Regular; no P waves seen or P wave just after QRS	AV junctional re-entry tachycardia (due to AV nodal re-entry or accessory pathway)

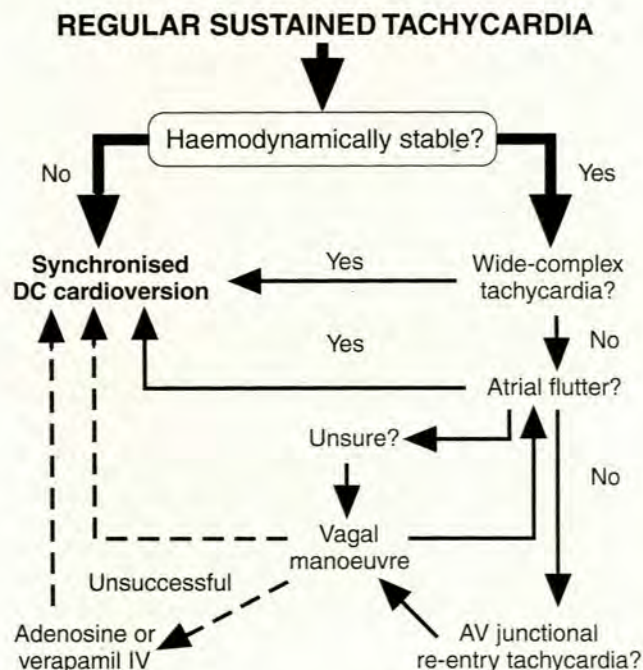


Fig. 1. Flow diagram for emergency unit treatment of sustained tachycardia other than atrial fibrillation. Verapamil was only used for tachycardia thought to be due to AV junctional re-entry if vagal manoeuvres had failed. Adenosine was not available at the time of the study, but is included for completeness. If vagal stimulation revealed atrial flutter, DC cardioversion was used.

Our DC cardioversion protocol was as follows: (i) all cardioversions were performed in a cubicle with full resuscitation equipment on hand; (ii) the patient was sedated with aliquots of intravenous midazolam, via a drip *in situ*, until he/she was sleeping and did not respond to his/her name; (iii) flumazenil was readily available to reverse sedation; (iv) oxygen was given by facemask; (v) the defibrillator was placed into synchronised mode. After the application of electrode jelly, the right paddle was placed under the right clavicle, adjacent to the sternum, and the left paddle against the left lateral chest. Firm pressure was applied; (vi) the initial energy setting was 50 joules. Energy was doubled after each unsuccessful shock to a maximum of 360 joules; (vii) the patient was observed in the high-care area post-cardioversion; and (viii) a 12-lead ECG was performed pre- and post-cardioversion.

Results (Table II)

Fifty-three events in 44 patients (28 women) were entered over a period of 16 months. Ventricular tachycardia was present in 7, atrial flutter in 21, paroxysmal junctional re-entry tachycardia in 20, atrial fibrillation in 4 and multifocal atrial tachycardia in 1. Fifty-two tachyarrhythmias were successfully managed in the Emergency Unit. Of these, 42 were electrically cardioverted. We had no serious complications, mild wheals at the site of paddle application being reported in a few patients.

Table II. Patient characteristics and outcomes

Rhythm	AFL	PJRT	AF	VT	MFAT	Total
Episodes	21	20	4	7	1	53
Patients						
Female	12	12	3	-	1	28
Male	4	8	1	3	-	16
Ventricular rate (min)	123 - 170	144 - 220	120 - 178	158 - 250	150	
Systolic BP < 100 mmHg	3/21	8/20	1/4	1/7	0/1	
Vagal manoeuvre successful	0/17	4/20	0/3	0/1		
Verapamil successful	1/1 (AF)	5/5				
DC shock successful	20/20	11/11	4/4		0/1	
Shock (joules)	30 - 200	30 - 200	100 - 300		200	

AFL = atrial flutter; PJRT = paroxysmal junctional re-entry tachycardia; AF = atrial fibrillation; VT = ventricular tachycardia; MFAT = multifocal atrial tachycardia.

Intravenous diazepam (3 patients) and flunitrazepam (1 patient) were given in addition to midazolam when sedation was thought to be inadequate. Four patients, who were either elderly and/or had significant chronic obstructive airways disease, had their sedation electively reversed with flumazenil. This was undertaken at the attending doctor's discretion.

Ventricular tachycardia

Two patients had recurring sustained monomorphic ventricular tachycardia, 1 presenting four times and the other twice. They were successfully cardioverted as a first-line measure on each occasion, only 1 requiring more than 100 joules (Table II). One 24-year-old man was thought to

have paroxysmal junctional re-entry tachycardia but on review was noted to have fascicular ventricular tachycardia (with a pattern resembling right bundle-branch block and left axis deviation). DC cardioversion was successful initially, but the tachycardia recurred. It was then terminated with intravenous verapamil. (This patient had previously been found to be sensitive to verapamil.)

Atrial flutter

Twenty episodes were managed with DC cardioversion as a first-line measure, all successfully. Two patients had recurring atrial flutter, 1 presenting three times, the other twice. One patient was given intravenous verapamil that converted his arrhythmia to atrial fibrillation, which then spontaneously reverted to sinus rhythm.

Paroxysmal junctional re-entry tachycardia

In this group of 20 patients, 8 were haemodynamically unstable and all were successfully electrically cardioverted. The remaining patients were managed as follows: 4 were cardioverted with vagal manoeuvres, 5 by intravenous verapamil (after vagal manoeuvres had failed), and 3 with DC shock (after vagal manoeuvres had failed). All patients were successfully treated.

Atrial fibrillation

Although atrial fibrillation is the most common arrhythmia in patients presenting to the Emergency Unit, the majority have either chronic atrial fibrillation or are haemodynamically stable. We therefore had only 4 patients in this group who required urgent management of this arrhythmia. These patients were either hypotensive, experiencing acute angina or severely symptomatic from their arrhythmia. All 4 were managed successfully with DC cardioversion.

Multifocal atrial tachycardia

One patient, who had taken an aminophylline overdose, presented with multifocal atrial tachycardia. She was initially assessed as having atrial flutter and unsuccessfully shocked three times before the error was discovered. She was then referred to the cardiologist on call for further management. This was our only treatment failure.

Discussion

Synchronised DC shock has been used to convert a wide variety of sustained tachyarrhythmias to sinus rhythm since 1962.^{6,7} It is commonly used by cardiologists to terminate chronic arrhythmias such as atrial fibrillation (after adequate anticoagulation)⁸ and acute arrhythmias such as ventricular tachycardia, particularly those that are haemodynamically unstable.^{4,9,10} A recent report¹¹ attests to its safety when used for outpatient termination of supraventricular tachycardias. It is being increasingly used to terminate ventricular arrhythmias automatically via an implantable cardioverter defibrillator.¹² On the other hand, the hazards of anti-arrhythmic agents are increasingly being recognised, particularly when used inappropriately; the worldwide

tendency to give verapamil intravenously to patients with wide-complex tachycardia is an example of such inappropriate use.³

In contrast to the high success rate of synchronised DC cardioversion in ventricular tachycardia,¹³ intravenous lignocaine can be expected to terminate only 30% of episodes of sustained ventricular tachycardia, albeit with acceptable safety.¹⁴ The more potent anti-arrhythmic agents may achieve a higher success rate; flecainide is reported to be 80% effective¹⁵ but with far higher pro-arrhythmic and negatively inotropic side-effects.¹⁴

In our experience, non-cardiologist emergency unit personnel have been reluctant to use DC shock to cardiovert patients with acute sustained tachyarrhythmias and prefer to use intravenous agents, such as verapamil, even when unsure of the diagnosis. The reasons for this may include reluctance to sedate an ill patient, uncertainty about technique and fears regarding its safety. We therefore embarked on a programme of instruction of emergency unit personnel in the basic diagnosis of arrhythmias and the use of cardioversion.

In view of the relatively poor efficacy of drugs in converting atrial flutter¹⁵ and ventricular tachycardia¹⁴ to sinus rhythm, emergency unit staff were encouraged to use synchronised DC cardioversion as a first-line measure for these arrhythmias, whereas regular, narrow-complex tachycardias thought to be due to AV junctional re-entry were given intravenous verapamil when the patient was haemodynamically stable and vagal manoeuvres had failed to restore sinus rhythm.

The results of the prospective study of this policy demonstrate that non-cardiologists in a medical emergency unit can terminate the vast majority of acute sustained tachyarrhythmias with reasonable safety by following these guidelines. DC cardioversion was used inappropriately in only 1 patient, in whom multifocal atrial tachycardia was mistakenly thought to be atrial flutter. No long-term ill effects resulted.

The need for general anaesthesia⁸ may be a factor in the reluctance to use electrical cardioversion. This study, like others,¹⁶ confirms that satisfactory sedation can be obtained with intravenous midazolam. Full resuscitation equipment was available but was not needed for any patient in this series. In a few instances, the doctor elected to reverse the effects of the midazolam with flumazenil. The availability of this agent should reduce the likelihood of prolonged respiratory depression.¹⁷ Other potential complications of cardioversion, such as hypotension, arrhythmias, emboli or pulmonary oedema,^{8,13} were not seen in this series. Nevertheless, while all these complications have been reported, they are not unique to electrical cardioversion and may occur with anti-arrhythmic drugs.^{3,14,15}

A limitation of this study is that we did not set out to compare electrical cardioversion with drugs. However, the success rate for conversion of atrial fibrillation, atrial flutter and ventricular tachycardia was 100%, which exceeds that reported for chemical cardioversion of these arrhythmias.^{8,14,15}

Verapamil may be expected to convert 90 - 95% of paroxysmal junctional re-entry tachycardias to sinus rhythm.^{18,19} It was effective in all 5 such patients to whom it was given (Table II), but DC cardioversion was used in

haemodynamically unstable patients if vagal manoeuvres failed. This was done because of the known tendency of verapamil to cause further hypotension in such patients.¹⁹

Adenosine is probably the treatment of choice for AV junctional re-entry tachycardias, even if the patient is haemodynamically unstable, because of its short half-life and high efficacy;²⁰ it was not available to us at the time of this study, however.

Conclusions

These results indicate that non-cardiologist medical staff in a busy medical emergency unit can be readily trained to recognise the common acute sustained tachycardias and to treat them safely and efficiently with synchronised DC cardioversion, where appropriate.

This approach obviates the common difficulties encountered with differential diagnosis of regular wide-complex tachycardias^{2,4} as electrical cardioversion is a broad-spectrum treatment that is not associated with the hazards of inappropriate use of drugs such as verapamil.^{3,5} While the availability of adenosine will allow safer diagnosis and conversion of paroxysmal junctional re-entry tachycardias,²⁰ electrical cardioversion will still be required for ventricular tachycardia, atrial flutter and acute atrial fibrillation, particularly if the patient is not haemodynamically stable.

REFERENCES

- Lown B, Amarasingham R, Neuman J. New method for terminating cardiac arrhythmias: use of synchronized capacitor discharge. *JAMA* 1962; **182**: 548-555.
- Dancy M, Camm JA, Ward D. Misdiagnosis of chronic recurrent ventricular tachycardia. *Lancet* 1985; **2**: 320-323.
- Buxton AE, Marchlinski FE, Doherty JU, Flores B, Josephson ME. Hazards of intravenous verapamil for sustained ventricular tachycardia. *Am J Cardiol* 1987; **59**: 1107-1110.
- Scott Millar RN. 'It looks like SVT' — the misuse of intravenous verapamil in broad-complex tachycardia. *S Afr Med J* 1989; **76**: 296-297.
- Gulamhusein S, Ko P, Klein GJ. Ventricular fibrillation following verapamil in the Wolff-Parkinson-White syndrome. *Am Heart J* 1983; **106**: 145-147.
- Resnekov L, McDonald L. Appraisal of electroconversion in treatment of cardiac dysrhythmias. *Br Heart J* 1968; **30**: 788-811.
- Vassaux C, Lown B. Cardioversion of supraventricular tachycardias. *Circulation* 1969; **39**: 791-802.
- Pritchett ELC. Management of atrial fibrillation. *N Engl J Med* 1992; **326**: 1264-1271.
- Zipes DP. The clinical application of cardioversion. *Cardiovasc Clin* 1970; **2**: 239-260.
- Hoffman JR. Emergency department management of life-threatening arrhythmias. *Emerg Med Clin North Am* 1986; **4**: 761-764.
- Lesser MF. Safety and efficacy of in-house cardioversion for treatment of supraventricular arrhythmias. *Am J Cardiol* 1990; **66**: 1267-1269.
- Mirowski M. The automatic implantable cardioverter-defibrillator: an overview. *J Am Coll Cardiol* 1985; **6**: 461-466.
- DeSilva RA, Graboyes TB, Podrid PJ, Lown B. Cardioversion and defibrillation. *Am Heart J* 1980; **100**: 881-895.
- Griffith MJ, Linker NJ, Garratt CJ, Ward DE, Camm AJ. Relative efficacy and safety of intravenous drugs for termination of sustained ventricular tachycardia. *Lancet* 1990; **336**: 670-673.
- Nathan AW, Camm AJ, Bexton RS, Hellestrand KJ. Intravenous flecainide acetate for the clinical management of paroxysmal tachycardias. *Clin Cardiol* 1987; **10**: 317-322.
- Khan AH, Malhotra R. Midazolam as intravenous sedative for electrocardioversion. *Chest* 1989; **95**: 1068-1071.
- Fennelly ME, Powell H, Galletly DC, Whitwam JG. Midazolam sedation reversed with flumazenil for cardioversion. *Br J Anaesth* 1992; **68**: 303-305.
- Kuhn M. Verapamil in the treatment of paroxysmal supraventricular tachycardia. *Ann Emerg Med* 1981; **10**: 538.
- Ornato JP. Management of paroxysmal supraventricular tachycardia. *Circulation* 1986; **74**: Suppl IV, IV-108-10.
- Di Marco JP, Sellers TD, Berne RM, West GA, Belardinelli L. Adenosine: electrophysiologic effects and therapeutic use for terminating paroxysmal supraventricular tachycardia. *Circulation* 1983; **68**: 1254-1263.

Accepted 18 Apr 1994.