

Congenital syphilis associated with persistent pulmonary hypertension of the neonate — a clinico-pathological case study

Johan Smith, Johann W. Schneider

Congenital syphilis remains a significant clinical problem, especially in developing countries. We report a fatal case of congenital syphilis complicated by persistent pulmonary hypertension and hypoxic ischaemic encephalopathy.

Objective. To describe the association of congenital syphilis with persistent pulmonary hypertension of the newborn (PPHN).

Method. Case report of a single patient.

Results. Fatal outcome of one baby with congenital syphilis and associated PPHN despite maximal conventional treatment. Histological examination of the lungs revealed pulmonary oedema, intra-alveolar haemorrhages, localised bronchopneumonia and marked interstitial infiltrates of lymphocytes, plasma cells, macrophages and fibroblasts with interstitial fibrosis. Examination of peripheral pulmonary arteries revealed focal excessive muscularisation with increased adventitial connective tissue.

Discussion. Reviewing our own experience and available literature, this case study supports the infrequent association of congenital syphilis with PPHN. However, when it occurs, this combination appears to be fatal.

Conclusion. More research is warranted to clarify the role of inflammatory mediators in congenital syphilis of the lung.

S Afr Med J 1995; **85**: 1232-1235.

Although more common in underdeveloped and developing countries, congenital syphilis occurs among all social groups.¹⁻⁵ The spectrum of the disease varies from stillbirths and asymptomatic infected liveborn infants to overt syphilis-associated multisystem involvement.^{3,6} Apart from the classic clinical manifestation, unfamiliar disorders have been reported to occur in association with congenital syphilis.

Departments of Paediatrics and Child Health and Anatomical Pathology, Tygerberg Hospital and University of Stellenbosch, Tygerberg, W. Cape

Johan Smith, M.B. CH.B., M.MED. (PAED.)

Johann W. Schneider, M.B. CH.B., M.MED. (PATH.)

These include neonatal intestinal obstruction with or without ileal perforation,^{7,8} non-syndromatic paucity of intrahepatic bile ducts⁹ and necrotising funisitis.¹⁰ Recently, Spear *et al.*¹¹ described the first (to our knowledge) case of persistent pulmonary hypertension of the neonate (PPHN) with respiratory failure, associated with congenital syphilis. We report a neonate who presented with congenital syphilis-associated PPHN and superimposed intra-uterine hypoxia, illustrating the varying spectrum of clinical circumstances in which congenital syphilis should be a diagnostic consideration.

Case history

The patient, a male infant weighing 2 520 g, was the product of 38 weeks' gestation in a 34-year-old gravida 9, para 8 woman. The mother did not attend antenatal clinics and presented on the day of delivery in active labour. On examination, abdominal palpation revealed a singleton breech presentation. The cervix was 3 cm dilated and the membranes were intact. External fetal heart rate monitoring showed a basal heart rate of 150/min with extremely poor beat-to-beat variability of less than 5/min. Repeated late decelerations occurred. A lower uterine segment caesarean section was performed, yielding an infant with Apgar scores of 2 and 6 at 1 and 5 minutes, respectively. No meconium was noted. The placenta appeared large and weighed 700 g. The infant was intubated and ventilated. The initial physical examination revealed a hydropic and pale-looking infant. His abdomen was distended because of ascites and hepatosplenomegaly. Widespread skin desquamation and a truncal petechial rash were evident. Decreased capillary filling time, weakly palpable pulses, hypotension (blood pressure 40/19 mmHg) and active bleeding via the endotracheal tube were observed. Neurological findings included a depressed level of consciousness and generalised intermittent tonic seizures.

The initial chest radiograph (Fig. 1) showed interstitial lung involvement, right upper lobe opacification and an increased cardiothoracic ratio (0,64). The initial arterial blood gas analysis on a FiO_2 of 1,0 revealed the following: pH 7,17, partial arterial carbon dioxide pressure ($PaCO_2$) 5,5 kPa, partial arterial oxygen pressure (PaO_2) 7,0 kPa, bicarbonate 16 mmol/l, and an arterial-alveolar PO_2 ratio (a/APO_2) of 0,07. (The a/APO_2 ratio reflects the degree of compromise in arterial oxygenation and the ratio in a healthy baby is $\geq 0,75$.) The full blood count revealed a white cell count of $35 \times 10^9/l$ (neutrophils 18%, lymphocytes 66%, monocytes 6%, eosinophils 4%, band cells 2%, basophils 2%, metamyelocytes 2%); the haemoglobin concentration was 8,9 g/dl; the mean corpuscular volume (MCV) was 120 fl; and platelet count $43 \times 10^9/l$. The liver enzyme values were as follows: aspartate aminotransferase (AST) 287 U/l, alanine aminotransferase (ALT) 45 U/l, lactate dehydrogenase (LDH) 1 931 U/l and alkaline phosphatase 372 U/l. The C-reactive protein level was 31 $\mu g/ml$ and the infant's venereal disease research laboratory (VDRL) titre was 1:256. Fluorescent treponemal antibody absorption (FTA-ABS) and FTA-ABS IgM testing confirmed congenital syphilis. Other investigations revealed no laboratory evidence of cytomegaloviral or toxoplasmosis infection. The infant's

clinical course was complicated by severe PPHN and status epilepticus. The PPHN was confirmed by two-dimensional echocardiography which showed right-to-left shunting across the ductus arteriosus, tricuspid insufficiency and an estimated pulmonary artery systolic pressure of 48 mmHg. The pulmonary arterial hypertension initially responded to hyperventilation-induced alkalosis. No tolazoline or exogenous surfactant was administered. Further treatment included penicillin, dopamine, intravascular volume expansion and a continuous bicarbonate infusion. The ventilatory course of the patient is depicted in Fig. 2. The ventilation index (VI1), the product of ventilator respiratory rate and peak inspiratory pressure partly reflects severe respiratory compromise ($VI1 > 1\ 000$) and our approach to ventilation in some patients with PPHN, i.e. hyperventilation (higher VI1) to induce an alkalosis in an attempt to reduce pulmonary vascular resistance with subsequent improvement in oxygenation (higher a/APO_2 ratios). In Fig. 2, the effect of this approach on oxygenation is most evident at 18 hours of age. Despite attempts to stabilise the infant,

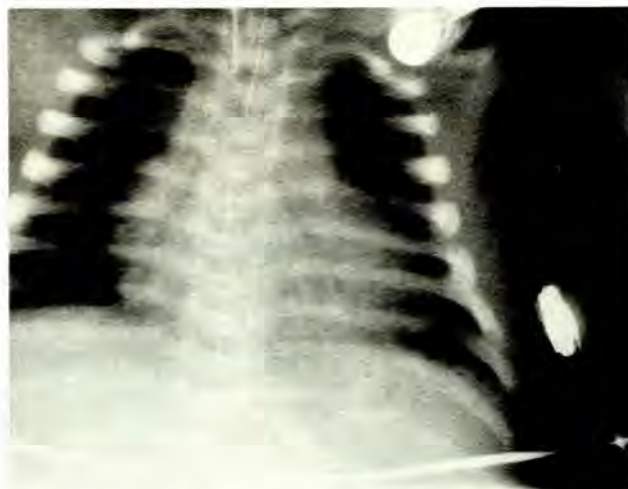

Fig. 1. Admission chest radiograph showing a bilateral streaky infiltrative pattern with opacification of the right upper lung lobe with associated air bronchogram. The cardiothoracic index is increased.

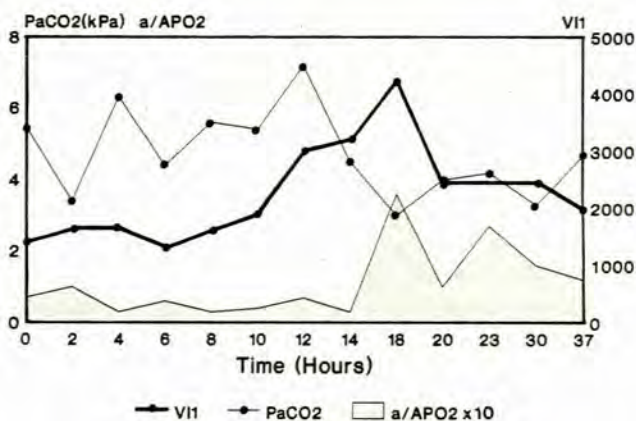


Fig. 2. The ventilatory course of the infant during hyperventilation ($VI1 = \text{maximum inspiratory pressure (cm H}_2\text{O)} \times \text{respiratory rate}$).

there were marked fluctuations in oxygen saturations (depicted in the a/APO₂ ratio changes) which coincided with recurrent convulsions. The convulsions were resistant to all forms of treatment including phenobarbitone, phenytoin, continuous lignocaine infusion and pentothal. Ultrasonographic studies of the brain demonstrated bilateral subependymal intracranial haemorrhages without hydrocephalus or brain swelling. In the light of the severe respiratory compromise and status epilepticus it was decided to withdraw life support therapy. The patient died 37 hours after birth.

Autopsy showed lungs of normal macroscopic size. There was a slightly increased combined lung mass of 46,5 g. Histopathological examination of lung sections (Fig. 3) revealed pulmonary oedema, intra-alveolar haemorrhages, localised bronchopneumonia and a marked interstitial infiltrate of lymphocytes, plasma cells and macrophages associated with fibroblast proliferation and mild interstitial fibrosis. Close examination of the peripheral pulmonary arterioles within the inter-alveolar septa showed focal muscularisation with associated increased adventitial connective tissue. These changes were observed in numerous sections representative of all the lung lobes. Meconium aspiration, intravascular thrombi and abnormalities of the pulmonary veins were absent. No evidence of obliterative fibrosis as described in 'pneumonia alba' was present.

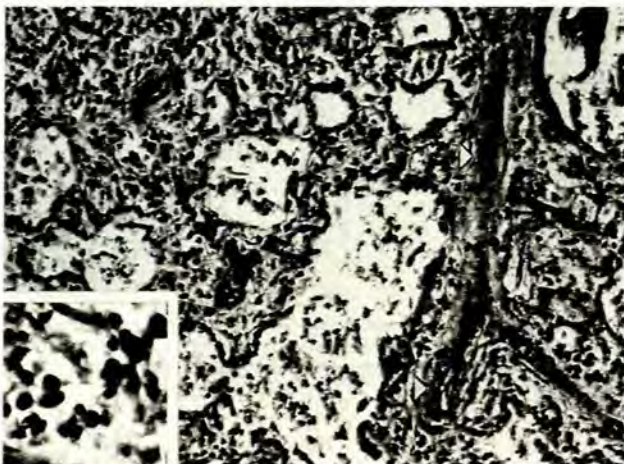

Fig. 3. The inter-alveolar septa are infiltrated by numerous macrophages, lymphocytes and plasma cells (inset) with associated fibroblasts and delicate fibrosis. Note the muscularisation of an intra-acinar arteriole (arrows)

Examination of the cardiovascular system revealed a patent foramen ovale and a ductus arteriosus. The brain showed no evidence of syphilitic involvement. A subependymal matrix haemorrhage without ventricular dilatation was present. Sections of the pancreas, hypophysis, epididymis, pharynx, submucosa of the small intestine, adrenals, kidneys and pericardium showed extensive interstitial fibrosis and inflammation.

Extramedullary haematopoiesis was a prominent finding in the liver, spleen, myocardium, lungs, adrenals and pancreas. The placenta was unavailable for histological assessment.

Discussion

PPHN remains a challenging clinical problem. The incidence varies, but accounts for 1 - 4% of all neonatal intensive care unit admissions per year.^{12,13} The clinical syndrome is characterised by severe hypoxaemia due to right-to-left shunting of blood through the ductus arteriosus and/or foramen ovale. Symptoms usually appear soon after birth in affected full-term or post-term babies.¹³ However, in developing countries, babies with this condition tend to be of both lower birth weight and gestational age.¹² PPHN was previously noted to occur equally frequently (50:50) with or without underlying lung disease. During the past 9 years, reports clearly show a shift towards a 25:75 ratio in favour of PPHN's occurring in association with lung disease or cardiac anomalies.¹³ The change particularly seems to reflect increasing awareness of PPHN associated with diseases such as hyaline membrane disease and pneumonia caused by a variety of organisms.¹⁴⁻¹⁷

Both animal studies and human case reports indicate that increased pulmonary vascular resistance occurs in association with Gram-negative organisms (*Pseudomonas* spp., *Escherichia coli*), group B *Streptococcus*, *Pneumococcus* and *Ureaplasma urealyticum* infections.¹⁴⁻¹⁷ In cases of neonatal sepsis it has been suggested that PPHN might be mediated or exacerbated by endogenous thromboxane A₂ release. Urinary metabolite (dinor-thromboxane B₂) excretion was found to be consistently higher early in the course of pulmonary hypertension associated with sepsis, compared with hypertension without sepsis.¹⁸

Recently, Waites *et al.*¹⁷ described 5 babies who suffered from *U. urealyticum* pneumonia associated with PPHN. Four of the 5 infants also had other concomitant bacterial infections, including *Staphylococcus epidermidis*, *Mycoplasma hominis* and a *Haemophilus* species. Nevertheless, both *U. urealyticum* and *M. hominis* have been shown to produce phospholipases which may be involved in the pathogenesis of PPHN via the liberation of arachidonic acid and subsequent thromboxane.¹⁹

In some cases, the sequence of events resulting in clinical PPHN suggests that perinatal hypoxia could have been the underlying 'trigger'. It is possible that thromboxane, released as a result of hypoxia, may mediate both platelet aggregation and pulmonary hypertension.¹⁸ There are considerable data to show that the pulmonary vasculature undergoes extensive remodelling in cases of smooth-muscle cell hyperplasia and that there is an increase in connective tissue when it is exposed to chronic hypoxia.^{20,21} The pathogenesis of the cellular hyperplasia is unclear, but may involve vascular endothelial injury, smooth-muscle cell and fibroblast interaction.^{20,22}

Pulmonary parenchymal involvement in infants with congenital syphilis is common and is a difficult problem to manage.²³ In premature babies with syphilis, the lung disease indicates a combination of surfactant deficiency, lung immaturity, interstitial scarring and extramedullary haematopoiesis; it is slow to resolve. The pulmonary involvement in the present case demonstrated a combination of pathological findings of which lymphocyte, macrophage and plasma cell infiltration of the interstitium was the most prominent. In addition to this, and previously

unreported, excessive focal intra-acinar arteriolar muscularisation was shown. It is not clear from the present case whether asphyxia and/or syphilis infection *per se* led to the development of the pulmonary hypertension. The evidence that hypoxia played a role is convincing (late decelerations, low Apgar score, severe metabolic acidosis at birth, hypoxic ischaemic encephalopathy). A review of the records of 37 infants with congenital syphilis who were admitted to our neonatal intensive care unit (1984 - 1991) revealed no documented PPHN (unpublished data).

The role of chemical mediators of inflammation and fibroblast proliferation released by macrophages and lymphocytes in the neonatal lung in cases of congenital syphilis has not been studied. Apart from the role of hypoxia, no hypothesis adequately explains the pathogenesis of treponemal infection of the neonatal lung. Despite the evidence for an immunopathy's causing syphilitic placentitis, we were unable to detect the typical vasculitic changes in the lung characteristic of a type III immunological reaction.²⁴ It is therefore unclear what pathogenetic role non-organ-specific serum auto-antibodies, such as rheumatoid factor or circulating immune complexes, play in the development of lung disease in babies with syphilis.^{25,26} Polymorphonuclear leucocytes infiltrate within 1 - 2 days following testicular injection of *Treponema pallidum* in rabbits. Serum immunoglobulin G is first detectable on day 3 and interleukin-2 (IL-2) is activated by day 4.²⁷ T lymphocytes infiltrate and proliferate by day 6.²⁸ Macrophages subsequently infiltrate infected tissues and phagocytose and secrete treponemocidal factors that kill and lyse *T. pallidum* in the presence of opsonic antibody.^{27,29,30} Fitzgerald²⁷ recently suggested that *T. pallidum* stimulates IL-2 production, delayed-type hypersensitivity reaction and gamma interferon production (Th₁ response) which up-regulate phagocytosis by macrophages. Subsequent oversecretion of prostaglandin E₂ by macrophages interrupts the continued cycle of macrophage activity (through inhibition of T-helper cell synthesis of gamma interferon), eventually culminating in chronic infection. Macrophages also release several mediators that stimulate lung fibroblast proliferation. Of these fibronectin, platelet-derived growth factor and insulin-like growth factor 1 are implicated in fibrosing conditions of the lung.

In summary, reviewing our previous experience with congenital syphilis as well as the present case, we have to conclude that the coexistence at birth of congenital syphilis and PPHN is a rare finding. This combination also appears to be poorly responsive to conventional therapeutic manoeuvres.¹¹ Further research is warranted to clarify the potential role of inflammatory mediators, circulating immune complexes, vascular endothelial damage and prostanoid production in the pathogenesis of prenatally acquired syphilitic lung disease associated with PPHN, before the 'great imitator' is definitely implicated as a cause of PPHN.

REFERENCES

- Delport SD. On site screening for maternal syphilis in an antenatal clinic. Proceedings of the 11th Conference on Priorities in Perinatal Care in South Africa, Caledon, W. Cape, 11 - 13 March 1992.
- Delport SD, Hay IT. Syphilis serology in mother-infant pairs. Proceedings of the 10th Conference on Priorities in Perinatal Care in South Africa, Malaga, E. Tvl, 12 - 15 March 1991.
- Judge DM, Tafari N, Naeye RL, Marboe C. Congenital syphilis and perinatal mortality. *Pediatr Pathol* 1986; **5**: 411-420.
- Rolls RT, Nakashima AK. Epidemiology of primary and secondary syphilis in the United States, 1981 through 1989. *JAMA* 1990; **264**: 1432-1437.
- Zenker PN, Berman SM. Congenital syphilis: trends and recommendations for evaluation and management. *Pediatr Infect Dis J* 1991; **10**: 516-522.
- Oppenheimer EH, Hardy JB. Congenital syphilis in the newborn infant: clinical and pathological observations in recent cases. *Hopkins Med J* 1971; **129**: 63-81.
- Heydenrych JJ, McCormick MV. Solitary gumma in a neonate. A case report. *S Afr Med J* 1988; **74**: 464-465.
- Siplovich L, Davies MR, Kaschula ROC, Cywes S. Intestinal obstruction in the newborn with congenital syphilis. *J Pediatr Surg* 1988; **23**: 810-813.
- Sugiura H, Hayashi M, Koshida R, et al. Nonsyndromic paucity of intrahepatic bile ducts in congenital syphilis. A case report. *Acta Pathol Jpn* 1988; **38**: 1061-1068.
- Fojaco RM, Hensley GT, Moskowitz L. Congenital syphilis and necrotising funisitis. *JAMA* 1989; **12**: 1788-1790.
- Spearl ML, Parker FP, Stefano JL. Case report: Congenital syphilis associated with persistent pulmonary hypertension of the newborn. *Del Med J* 1991; **63**: 223-227.
- Smith J, Kirsten GF. Persistent pulmonary hypertension of the neonate in a developing country; Does extracorporeal membrane oxygenation have a role to play? *S Afr Med J* 1993; **83**: 742-745.
- Weigel TJ, Hageman JR. National survey of diagnosis and management of persistent pulmonary hypertension of the newborn. *J Perinatol* 1992; **10**: 369-375.
- Bejar P, Curbelo V, Davis C, et al. Premature labor: II. Bacterial sources of phospholipase. *Obstet Gynecol* 1981; **57**: 479-482.
- Brus F, van Waarde WM, Schoots C, Bambang Oetonic S. Fatal ureaplasma pneumoniae and sepsis in a newborn infant. *Eur J Pediatr* 1991; **150**: 782-783.
- Rojas J, Stahlman M. The effect of group B streptococcus and other organisms on the pulmonary vasculature. In: Phillips JB, ed. *Clinics in Perinatology*. Philadelphia: WB Saunders Company, 1984.
- Waites KB, Crouse DT, Phillips JB, Canupp KL, Cassell GH. Ureaplasma pneumoniae and sepsis associated with persistent pulmonary hypertension of the newborn. *Pediatrics* 1989; **83**: 79.
- Kühl PG, Cotton RB, Schweer H, Seyberth HW. Endogenous formation of prostanoids in neonates with persistent pulmonary hypertension. *Arch Dis Child* 1989; **64**: 949-952.
- De Silva NS, Quinn PA. Endogenous activity of phospholipase A- and C in ureaplasma urealyticum. *J Clin Microbiol* 1986; **23**: 354-359.
- Hassoun PM, Thompson BT, Hales CA. Partial reversal of hypoxic pulmonary hypertension by heparin. *Am Rev Respir Dis* 1992; **145**: 193-196.
- Murphy JD, Rabinovitch M, Goldstein JD, Reid LM. The structural basis of persistent pulmonary hypertension of the newborn infant. *J Pediatr* 1981; **98**: 962-967.
- Reid LM, Davies P. Control of cell proliferation in pulmonary hypertension. In: Weir EK, Reeves JT, eds. *Pulmonary Vascular Physiology and Pathophysiology*. Marcel Dekker, 1989.
- Austin R, Melhem RE. Pulmonary changes in congenital syphilis. *Pediatr Radiol* 1991; **21**: 404-405.
- Samson GR, Meyer MP, Blake DRB. Syphilitic placentitis — an immunopathy. Proceedings of the 12th Conference on Priorities in Perinatal Care in South Africa, 1993.
- Dobson SRM, Taber LH, Baughn RE. Characterization of the components in circulating immune complexes from infants with congenital syphilis. *J Infect Dis* 1988; **158**: 940-947.
- Meyer MP, Maian AF. Rheumatoid factor in the diagnosis of congenital syphilis. *S Afr Med J* 1987; **72**: 668-669.
- Fitzgerald TJ. The Th₁/Th₂-like switch in syphilitic infection: Is it detrimental? *Infect Immun* 1992; **60**: 3475-3479.
- Lukehart SA, Baker-Zander MA, Lloyd RMC, Sell S. Characterization of lymphocyte responsiveness in early experimental syphilis. II. Nature of cellular infiltration and *T. pallidum* distribution in testicular lesions. *J Immunol* 1980; **124**: 461-467.
- Baker-Zander MA, Lukehart SA. Macrophage-mediated killing of opsonized *Treponema pallidum*. *J Infect Dis* 1992; **165**: 69-74.
- Podwinska J. Identification of cells producing anti-treponemal lymphotoxin. *Arch Immunol Ther Exp* 1987; **35**: 63-70.

Accepted 28 Aug 1995.