

Umbilical hernia in children in a developing country: Does the season have an effect on the occurrence of strangulation?

To the Editor: Umbilical hernia in a child is considered benign in developed countries, as complications seldom occur.^[1] In Africa, complications related to umbilical hernia, such as strangulation, are frequent.^[2,3] Strangulation often occurs if the hernia has a diameter of 0.5 - 1.5 cm. The theory of a foreign body in the hernial sac was raised by Papagrigoriadis *et al.*^[1] in London, and Brown *et al.*^[4] in South Africa. However, the actual causes of strangulation are unknown.

A retrospective study was conducted in the Unit of Paediatric Surgery, University Hospital Aristide Le Dantec, Dakar, Senegal from 1 May 2006 to 30 April 2009. All patients <16 years of age with a strangulated umbilical hernia were included in the study. Children who presented with an incarcerated hernia were excluded. Incarcerated hernia is characterised by a painful episode, with a momentary irreducibility of the hernia that yields spontaneously. All patients underwent emergency surgery. The study comprised 35 of 305 patients with strangulated hernias operated on during the study period. There were 20 boys and 15 girls (ratio 1.3). The average age was 34 months (range 2 months - 9 years). Sixty-five percent of children had rhinitis, asthma or pneumonia.

There are two different seasons in Senegal: a dry season (from October to June) and a rainy season (from July to September). During the dry season, we noted 33 cases

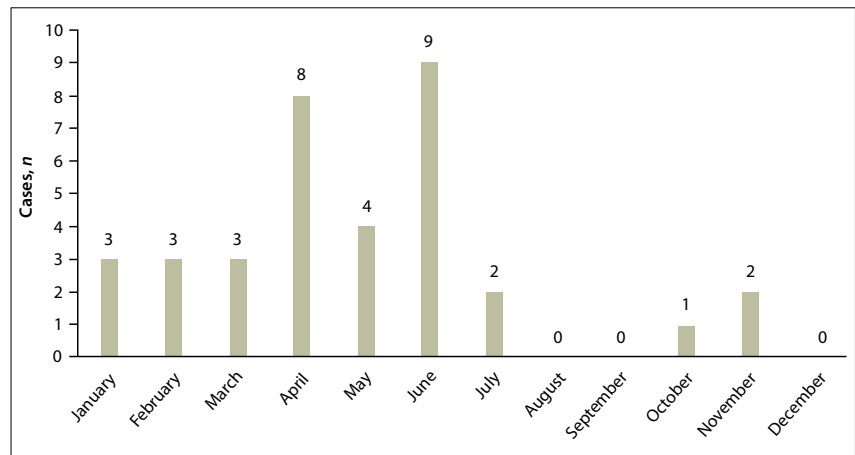


Fig. 1. Number of cases of strangulated umbilical hernias during the dry and rainy seasons in Senegal.

of strangulated umbilical hernias compared with two cases in the rainy season. Sixty percent of such hernias were seen in April, May and June (Fig. 1), i.e. almost exclusively during the dry season. Dry season in Senegal is marked by the presence of a cold, dry wind, the harmattan, which corresponds to the peak of strangulated hernias during these months. There are many factors, e.g. airborne allergens, which may lead to the onset of rhinitis, pneumonia or asthma. Patients with these respiratory conditions often develop a cough, which is responsible for increased abdominal pressure. The latter promotes visceral protrusion through the collar of the hernia, and causes discomfort. The loop continues to protrude and distend, and its increased volume makes it difficult and consequently impossible for reinsertion into the abdominal cavity. This promotes strangulation.^[5] We conclude that the dry wind in

Senegal, which causes a variety of respiratory conditions, is associated with strangulation of umbilical hernias.

G Ngom, F Gassama, A S Mohamed, O Ndour

Unit of Paediatric Surgery, University Hospital Aristide Le Dantec, Dakar, Senegal
gngom2004@yahoo.fr

- Papagrigoriadis S, Browse DJ, Howard ER. Incarceration of umbilical hernias in children: A rare but important complication. *Pediatr Surg Int* 1998;14(3):231-232. DOI:10.1007/s003830050711
- Ngom G. Umbilical hernia in African children: Same attitude than that of inguinal hernia. *J Indian Assoc Pediatr Surg* 2006;11(4):255. DOI:10.4103/0971-9261.29615
- Chirdan LB, Uba AE, Kidmas AT. Incarcerated umbilical hernia in children. *Eur J Pediatr Surg* 2006;16(1):45-48. DOI:10.1055/s-2006-923792
- Brown RA, Numanoglu A, Rode H. Complicated umbilical hernia in childhood. *S Afr J Surg* 2006;44(4):136-137.
- Flamant Y, Boudet MJ, Zeitoun G. Hernies et étran-glements. *Rev Prat* 1993;43:716-721.

S Afr Med J 2016;106(8):744.
DOI:10.7196/SAMJ.2016.v106i8.10947