



19. Misaki T, Watanabe G, Iwa T, et al. Surgical treatment of arrhythmogenic right ventricular dysplasia: long-term outcome. *Ann Thorac Surg* 1994; 58: 1380-1385.
20. CAST Investigators. Preliminary report: Effect of encainide and flecainide on mortality in a randomized trial of arrhythmia suppression after myocardial infarction. *N Engl J Med* 1989; 321: 406-412.
21. Scott Millar RN, Lawrenson JB, Milne DA. Normal left ventricular function does not protect against propafenone-induced incessant ventricular tachycardia. *S Afr Med J* 1993; 83: 256-259.
22. Pinamonti B, Miani D, Sinagra G, Bussani R, Silvestri F, Camerini F. Familial right ventricular dysplasia with biventricular involvement and inflammatory infiltration. *Heart* 1996; 76: 66-69.
23. Leclercq JF, Coumel P. Characteristics, prognosis and treatment of the ventricular arrhythmias of right ventricular dysplasia. *Eur Heart J* 1989; 10: Suppl D, 61-67.
24. Lemery R, Brugaga P, Janssen J, Cheriex E, Dugernier T, Wellens HJ. Nonischemic sustained ventricular tachycardia: clinical outcome in 12 patients with arrhythmogenic right ventricular dysplasia. *Am Coll Cardiol* 1989; 14: 96-105.
25. Canu G, Atallah G, Claudel JP, et al. Prognosis and long-term development of arrhythmogenic dysplasia of the right ventricle. *Arch Mal Coeur Vaiss* 1993; 86: 41-48.
26. Daubert C, Vauthier M, Mabo P, Laurent M, de Place C, Foulgoc JL. Long term prognosis of arrhythmogenic right ventricular disease: follow-up of 74 patients. *Am Coll Cardiol* 1994; 23: Abstr. Suppl. 203A.
27. Pinamonti B, Lenarda AD, Sinagra G, Silvestri F, Bussani R, Camerini F. Long-term evolution of right ventricular dysplasia-cardiomyopathy. *Am Heart J* 1995; 129: 412-415.
28. Kullo IJ, Edwards WD, Seward JB. Right ventricular dysplasia: The Mayo Clinic experience. *Mayo Clin Proc* 1995; 70: 541-548.
29. Rampazzo A, Nava A, Erne P, et al. A new locus for arrhythmogenic right ventricular cardiomyopathy (ARVD2) maps to chromosome 1q42-q43. *Hum Mol Genet* 1995; 4: 2151-2154.
30. Severini GM, Krajcinovic M, Pinamonti B, et al. A new locus for arrhythmogenic right ventricular dysplasia on the long arm of chromosome 14. *Genomics* 1996; 31: 193-200.

Accepted 6 June 1999.

Anaesthesia titles from Arnold Publishers

Paediatric Anaesthesia 2/e

Eds: D J Hatch & E Sumner

The previous edition of this well-respected text was identified as the top paediatric title in a listing of the best specialist text-books. In the new edition, the editors bring together an experienced team of international experts to share practical advice on the management of children and babies needing anaesthesia. The emphasis is on commonly encountered problems from everyday practice.

Oct 1999, c 512 pp, hard cover, R1 050

Pain: Acute and Chronic 2/e

Edward A Shtipov

The physician dealing with patients with acute, chronic or cancer pain needs a concise, practical but comprehensive guide to best management practice. This introductory clinical textbook examines all aspects of the assessment and management of pain at the basic level appropriate for the generalist physician requiring an overview of all aspects of pain, and pain control. It covers the physiology, pathology and clinical manifestations of different types of pain, and considers the physical, pharmacological and psychological interventions required to treat, and rehabilitate, patients with pain. Other issues include new modes of drug delivery, paediatric pain, AIDS-related pain, fibromyalgia, and the issue of self-help in pain control.

August 1999, 416 pp, soft cover, R375

Principles of Physiology for Anaesthetists

Ian Power and Peter Kam

The practice of anaesthesia, including intensive care medicine and pain management requires a considerable understanding of normal physiology. This book has been written to explain the fundamentals of physiology, using diagrams to aid understanding of difficult concepts. There is a separate section on pain.

Dec 1999, c 352 pp, paperback, R399

Clinical Problems in Obstetric Anaesthesia

Eds: G Lyons and L F Russell

A comprehensive, up-to-date treatise which describes the various clinical problems that the anaesthetist can face and outlines the best management practice that can be adopted.

1997, 304 pp, hard cover, R1 025

Short Practice of Anaesthesia

Eds: M Morgan and G Hall

Ideal for both trainee anaesthetists and as a ready reference for senior practitioners, the emphasis is on day to day practice and important clinical considerations in anaesthesia.

1997, 856 pp, hard cover, R1 280

Orders: The SA Medical Association, Private Bag X1, Pinelands

7430. tel (021) 531-3081, fax: (021) 531-4126,

e-mail: jstrydom@samedical.org Prepayment is required by cheque, Visa or MasterCard. Payment will not be taken until books are despatched.

NEW
EDITION

EXTRAORDINARY AROUSAL FROM SEMI-COMATOSE STATE ON ZOLPIDEM

A case report

R P Clauss, W M Guldenpfennig, H W Nel, M M Sathekge, R R Venkannagari

A young semi-comatose male patient was investigated using ^{99m}Tc hexamethyl-propylene amine oxime (^{99m}Tc HMPAO) brain single photon emission computed tomography (SPECT) before and after administration of the gamma-aminobutyric acid (GABA) agonist zolpidem. It was observed that 15 minutes after application of the drug the patient awoke from his semi-comatose condition and remained awake for the next 3 - 4 hours. When drug action subsided he returned to his semi-comatose state. Brain SPECT before drug application showed large hypo-active areas in certain parts of the brain. Brain SPECT after drug application showed a generalised cortical activation relative to the cerebellum and a marked and amplified activation of the areas that were hypo-active before drug application.

S Afr Med J 2000; 90: 68-72.

A semi-conscious patient was examined using ^{99m}Tc hexamethyl-propylene amine oxime (^{99m}Tc HMPAO) brain single photon emission computed tomography (SPECT) before and after application of the anti-insomnia drug zolpidem.

Consciousness may be defined as the ability to respond to sensory stimuli and to have subjective experiences. Impaired consciousness can range from mild suppression of consciousness to complete coma.¹ Coma is a state of unconsciousness from which the patient cannot be aroused.²

^{99m}Tc HMPAO is a lipophilic amine that crosses the blood-brain barrier and is used as a marker of brain perfusion and

Department of Nuclear Medicine, Medical University of Southern Africa, P O Box 83, Medunsa, 0204

R P Clauss, MB ChB, MMed (Nuc Med), MD

M M Sathekge, MB ChB, MMed (Nuc Med)

R R Venkannagari, BSc, MB BS, MMed (Nuc Med)

Little Company of Mary Medical Centre, Pretoria

W M Guldenpfennig, BSc Med, MB ChB, MMed (Neurol)

9 Media Road, Pollack Park, Springs

H W Nel, MB ChB



metabolism.³ When used in brain SPECT it delineates the grey matter of the brain. The cerebral hemispheres, cerebellum, thalamus and basal ganglia are therefore identified and their activity can be semi-quantified.

Zolpidem is a non-benzodiazepine agent belonging to the imidazopyridine class and is chemically distinct from sedatives such as barbiturates, antihistamines, benzodiazepines and cyclopyrrolones. It has a selectivity for stimulating gamma-aminobutyric acid (GABA) function and is used for the treatment of insomnia. It has a short half-life of 2.4 hours, with no active metabolite, and it does not accumulate with repeated administration. The drug is oxidised and hydroxylated by the liver to form inactive metabolites that are eliminated primarily through renal excretion.⁴

CASE REPORT

Ten milligrams of zolpidem was administered to a 28-year-old man who had been semi-comatose for 3 years following a motor vehicle accident. He had been normal and healthy before the accident other than suffering from retinitis pigmentosa since childhood.

On arrival at the hospital the patient's pupils were of equal size and reactive to light, but he was verbally unresponsive. The limbs flexed to pain with increase in tone, there was no evidence of meningeal irritation, and the cervical spine was normal. There was a flexor plantar response. A non-contrast computed tomography (CT) scan showed a small intra-cerebral haemorrhage in the left lentiform nucleus and thalamus area. Intra-ventricular blood was noted in the occipital horn of both lateral ventricles. A hyper-dense lesion was noted in the brainstem area in keeping with intracerebral haemorrhage in the area of the cerebellar peduncles. Full blood count and serum biochemistry were within normal limits. Epanutin, intravenous (IV) fluids and analgesics were administered to the patient. His mean arterial pressure was kept above 90 mmHg to assure good cerebral blood flow. On the second day following admission an intra-cranial pressure monitor was inserted, and the reading was 14 mmHg. The pressure did not rise above 15 mmHg in the subsequent days. The patient's temperature was kept below 37.5°C.

On neurological assessment at the time of hospital discharge the patient could open his eyes spontaneously. There was still no verbal response and the best motor response was flexion withdrawal on pain stimulus. He had right hemiplegia and a significant spasticity in both upper and lower limbs, with increased tone and reflexes. There was an asymptomatic posture owing to the right hemiplegia. The recommended treatment at the time of discharge from hospital was phenytoin 300 mg at night, enoxaparin 40 mg daily and paracetamol 6-hourly. The patient was admitted to a special home.

The abovementioned drugs were discontinued after some

time in the special home. In the subsequent months and years the patient developed fixed flexion contractures of his right arm and leg. Plantar flexion and an inversion contracture occurred in his left foot and there was shortening of his flexor and extensor hip muscles. He had hyperaesthesia (touch defensiveness), was generally restless and had developed chorea-type movements on the left side of his body. He could not feed himself and had no sphincter control. His mental state could be described as semi-comatose. He could open his eyes spontaneously but did not respond to speech or other stimuli. There was no verbal response to commands or questions. Since there was no evidence of cognitive skills, memory or reasoning, problem solving could not be tested. His emotional state could also not be determined. The maximum score on the Glasgow coma scale was 9/15.

In January 1999 the patient appeared extremely restless and 10 mg of zolpidem was prescribed to calm him. This drug was chosen because of its limited vascular and cerebral side-effects when compared with other insomnia medication. The patient regained consciousness 15 minutes after ingestion of the drug and greeted his mother for the first time in 3 years. It was the first time in over 2 years that he had uttered a sound.

Zolpidem was administered on the subsequent mornings. The patient regained consciousness for the duration of drug action, whereafter he relapsed into a semi-comatose state during the afternoon and night. After administering the drug there was initially a slight cough, followed by an improvement in skin colour. His eyes looked more awake and his upper lip became firm. He sighed and talked soon after these changes.

In his conscious phase the patient interacted spontaneously and responded to simple questions related to the environment and his relatives, providing short, appropriate answers. His cognition appeared to be intact, and he could perform simple calculations and write words dictated to him. The hyperaesthesia and spasticity decreased. He was able to pick up food and put it into his mouth. Eye opening was spontaneous and appropriate. Although he sometimes forgot time and place after being told, he did not appear confused. His immediate and remote memory were good. His emotional state was appropriate and his higher functions adequate, but he was still restricted by his physical disabilities.

Since his periodic regaining of consciousness some months ago, the patient has undergone an electro-encephalogram (EEG) study, a full biochemical assessment, and repeat CT scan. Biochemical investigations were normal and the brain pathology, as seen on the CT scan, remained unchanged. The most prominent change on an 8-channel EEG was the blocking of an underlying posterior 10 Hertz (Hz) activity when the patient opened his eyes after administration of zolpidem. Before administration of zolpidem posterior activity did not respond to eye opening. The patient was referred for a ^{99m}Tc HMPAO brain SPECT study.



METHOD

Two brain SPECT studies were completed on different days. The first study was completed during the semi-comatose state and the second study was performed 1 hour after application of 10 mg zolpidem (it had been noted that the patient's maximum arousal was 1 hour after drug application). The ^{99m}Tc HMPAO was prepared according to recommended protocols.^{5,6}

Acquisitions were completed 30 minutes after intravenous injection of 900 MBq ^{99m}Tc HMPAO, using a dual-head SOPHY DST XLi gamma camera. Acquisition parameters were 64 angular views over 360° at 45 seconds per view. Ultra-high resolution fanbeam collimation without zoom was used and a 20% symmetrical window over 140 kiloelectron-volts (keV). The images were reconstructed using a Metz pre-filter. Transaxial, sagittal and coronal slices were constructed without attenuation or scatter correction. The images before and after application of zolpidem were compared visually and semi-quantitatively by three experienced independent observers. Semi-quantification involved a left/right comparison of activity in comparative transaxial slices as well as between different segments of the brain.

RESULTS

The transaxial and three-dimensional images of the patient's brain before and after drug application are presented in Fig. 1. There is a generalised increased tracer uptake by the cerebrum relative to the cerebellum after drug administration. This may be due either to decreased cerebellar activity or increased cerebral activity.

The left occipital, parietal and posterior frontal lobe was 10 - 25% less active than the right in the semi-comatose state; this improved in most parts to approximately 5% difference after application of zolpidem (Fig. 2). The left temporal lobe was hypo-active before the medication when compared with the contralateral side, and had a very similar activity after the medication. The left nucleus lentiformis area was hypo-active before medication. The difference in activity between the left and right lentiform nuclei was more than 20%. This difference improved to less than 5% after application of the drug (Fig. 3). Activity in the anterior frontal lobes was equal before medication but the left anterior frontal lobe became more prominent than the right after medication.

DISCUSSION

Since the first application of the zolpidem the patient has shown progress in his emotional responses and communication. However, when the medication stops working the patient returns to his semi-comatose state. This case clearly documents clinical and objective physiological changes as seen

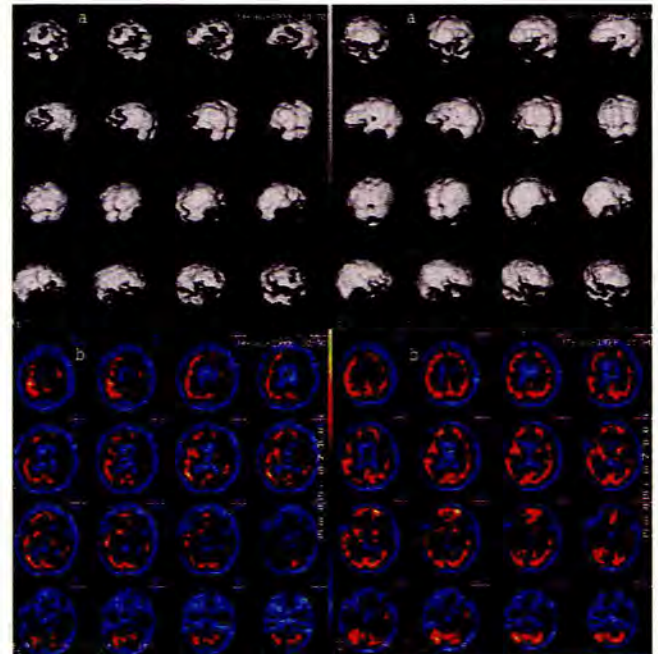


Fig. 1. Three-dimensional (a) and transaxial (b) images before and after application of zolpidem.

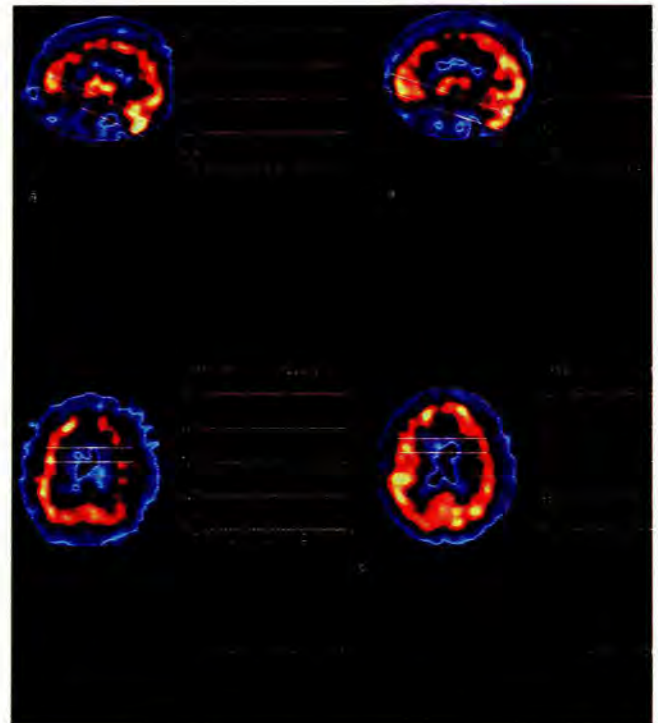


Fig. 2. Sagittal section through the right brain showing the difference of activity between the cerebellum and the cerebrum before and after medication (a), and through the left frontal and parietal lobe before and after medication (b).

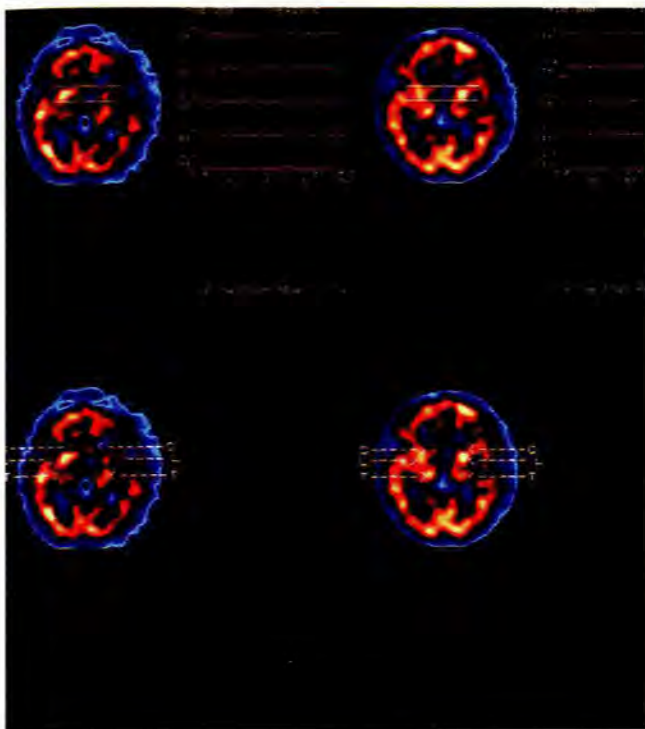


Fig. 3. Changes in the basal ganglia before and after medication (C = caudate nucleus, L = lentiform nucleus, T = thalamus).

on ^{99m}Tc HMPAO SPECT after medication. As far as we know this has not been described before.

Zolpidem is a preferential ω_1 and to a lesser extent ω_2 receptor agonist.^{7,8} These ω_1 and ω_2 receptors interact allosterically with the GABA-binding site,⁹ and increase chloride influx by means of GABA-independent mechanisms. GABA increases the permeability of post-synaptic membranes to potassium. Hence it drives the membrane potential away from the threshold for triggering the action potential, and in this way acts as an inhibitory neurotransmitter. GABA is formed by the decarboxylation of glutamate, a reaction catalysed by glutamate decarboxylase. It is inactivated by transamination to succinate semialdehyde, which is then oxidised to form succinate.¹⁰

GABA receptors are found all over the brain. Animal studies have shown that very high densities of ω_1 and ω_2 receptors occur in lamina IV of the neocortex, substantia inominata and in the molecular layer of the dentate gyrus. ω_1 receptor sites predominate in lamina IV of the sensorimotor cortical regions and in the extrapyramidal motor system (globus pallidus, ventral thalamic complex, subthalamic nucleus, substantia nigra and cerebellum).¹¹

It has been reported that catatonic patients may benefit from zolpidem.¹²⁻¹⁴ In one study, 7 out of 10 catatonic patients experienced a decrease in their catatonic symptoms 10 - 15

minutes after drug administration. This effect lasted 3 - 4 hours.¹² The drug also reduced agitation in patients with Alzheimer's disease.¹⁵

In a study of 10 patients with Parkinson's disease, it was found that there was an improvement in rigidity, akinesia, bradykinesia, posture and gait 45 - 60 minutes after zolpidem administration. The effect lasted for 3 - 4 hours.¹⁶ Our patient showed decreased rigidity after drug intake.

The changes investigated in the above studies followed administration of 10 mg zolpidem. However, it has been postulated that a lesser dose may achieve a similar result without hypnotic side-effects.¹⁵

Areas in the brain associated with particular movement disorders have been determined by means of cerebral imaging and autopsies, as well as by animal studies.^{17,18} Chorea has been most consistently associated with lesions in the caudate nucleus or putamen resulting in disinhibition of the external globus pallidus. Lesions of the subthalamic internal pallidal pathway may also result in chorea. The patient in this report has chorea-type movements in his semi-comatose state that improve after administration of zolpidem. On the brain SPECT a bilateral activity increase was noted in the caudate nuclei. Neurotransmitter abnormalities during chorea include deficient striatal GABAergic function and striatal cholinergic interneuron activity and dopaminergic hyperactivity in the nigrostriatal pathway.

Chorea and dystonia may result from hypoxia/ischaemia owing to global cerebral hypoperfusion or cellular hypoxia such as occurs in toxic mitochondrial dysfunction. Glutamate is the main neurotransmitter in the cortical neurons projecting to the striatum. Hypoxic ischaemic necrosis of the medium-sized spiny striatal neurons may be responsible for decreased concentrations of GABA. Global cerebral hypoxia/ischaemia may cause movement disorders in children and adults. Despite the global insult, patients often have focal or unilateral findings clinically and on imaging studies.¹⁹ Our patient had evidence of intracranial bleeding in the midbrain area at the time of his accident. On his brain SPECT there was a clearly decreased activity in the left lentiform nucleus that improved after administration of zolpidem. The basal ganglia receive cortical input and project back to the frontal cortex through the thalamus. Together with the circuits originating in the cerebellum, the basal ganglia-thalamocortical circuit modulates activity in the corticospinal motor system. In the above patient there was increased activity in both caudate nuclei and the left lentiform nucleus. Furthermore, there was a comparative generalised increase in the neural activity of the cerebrum compared with the cerebellum after administration of zolpidem. This was amplified in areas that were hypo-active in the semi-comatose state, such as the left frontal and parietal lobe.



CONCLUSION

There are two possibilities in terms of interpreting the above findings. Either ω_1 selective GABA-agonistic action results in bridging to the conscious state, or the drug has an unknown property that results in arousal to consciousness. It causes increased activity in the cerebrum compared with the cerebellum, which is selectively amplified in cortical regions that are hypo-active or hibernating in the semi-comatose state. These amplified cortical changes may well represent the 'switch on' effect that was observed clinically in this patient. We are now investigating other patients with similar clinical conditions.

We thank the following people for their input and support: Professor P Bartel, Drs E Allers, F J de Villiers, G I Grundling, J L Nienaber, C A Novis and D J Opperman. We also thank Synthelabo and A E C Amersham for their support.

References

1. Lindsay KW, Bone I. Coma and impaired conscious level. In: Lindsay KW, Bone I, Callender R, eds. *Neurology and Neurosurgery Illustrated*. 3rd ed. Churchill Livingstone, 1997: 81.
2. Ropper AH, Martin JB. Coma and other disorders of consciousness. In: Isselbacher KJ, Braunwald E, Wilson JD, Martin JB, Fauci AS, Kasper DL, eds. *Harrison's Principles of Internal Medicine*, Vol 1, 13th ed. McGraw-Hill, 1994: 150.
3. Costa DC, Ell PJ, Cullum ID, Jaritt PH. The *in vivo* distribution of ^{99m}Tc HMPAO in normal man. *Nucl Med Commun* 1986; 7: 647-658.
4. Salva P, Costa J. Clinical pharmacokinetics and pharmacodynamics of zolpidem. Therapeutic implications. *Clin Pharmacokinet* 1995; 29: 142-153.
5. Anderson AR. Technetium-99m-D,L-hexamethylene-propyleneamine oxime (^{99m}Tc HMPAO): basic kinetic studies of a tracer of cerebral blood flow. *Cerebrovascular and Brain Metabolism Reviews* 1989; 1: 288-318.
6. Newton MR, Austin MC, Chan JG, McKay WJ, Rowe CC, Berkovic SF. Ictal SPECT using technetium-99m-HMPAO: methods for rapid preparation and optimal deployment of tracer during spontaneous seizures. *J Nucl Med* 1993; 34: 666-670.
7. Arbilla S, Depoortere H, George P, et al. Pharmacological profile of the imidazopyridine zolpidem at benzodiazepine receptors and electrocorticogram in rats. *Naunyn-Schmiedeberg's Arch Pharmacol* 1985; 330: 248-251.
8. Langer SZ, Arbilla AS, Scatton B, et al. Receptors involved in the mechanism of action of zolpidem. In: Sauvaget JP, Langer SZ, Morselli PL, eds. *Imidazopyridines in Sleep Disorders*. New York: Raven Press, 1988: 55-70.
9. Biggio G, Concas A, Corda MG, et al. Enhancement of GABAergic transmission by zolpidem, an imidazopyridine with preferential affinity for type 1 benzodiazepine receptors. *Eur J Pharmacol* 1989; 161: 173-180.
10. Stryer L. Excitable membranes and sensory systems. In: Stryer L. *Biochemistry*. New York: WM Freeman, 1981: 895-896.
11. Dennis T, Dubois A, Benavides J, Scatton B. Distribution of central Ω_1 (benzodiazepine) and Ω_2 (benzodiazepine) receptor subtypes in the monkey and human brain. An autoradiographic study with [^3H] flunitrazepam and the Ω_1 selective ligand [^3H] zolpidem. *J Pharmacol Exp Ther* 1988; 247(1): 309-322.
12. Rasle C, Thomas P, Maron M, Mastain B, Ouldamar K, Goudemand M. Zolpidem: Pharmacological test in catatonia. Abstracts of the proceedings of the Xth World congress of Psychiatry, Madrid, Spain, 23 - 28 August 1996; 2: 333.
13. Thomas P, Rasle C, Mastain B, Maron M, Guillaume V. Test for catatonia with zolpidem. *Lancet* 1997; 349: 702.
14. Zaw ZF, Bates GDL. Replication of zolpidem test for catatonia in an adolescent. *Lancet* 1997; 349: 1914.
15. Jackson CW, Pitner JK, Mintzer JE. Zolpidem for the treatment of agitation in elderly demented patients. *J Clin Psychiatry* 1996; 57: 372-373.
16. Daniele A, Albanese A, Gainotti G, Gregori B, Bartolomeo P. Zolpidem in Parkinson's disease. *Lancet* 1997; 349: 1222-1223.
17. Young AB, Penney JB. Neurochemical anatomy of movement disorders. *Neurol Clin* 1984; 2: 417-433.
18. Hawker K, Lang AE. Hypoxic ischemic damage of the basal ganglia: case reports and review of the literature. *Mov Disord* 1990; 5: 219-224.
19. Janavs JL, Aminoff MJ. Dystonia and chorea in acquired systemic disorders. *J Neurol Neurosurg Psychiatry* 1998; 65: 436-445.

Accepted 27 Sep 1999.