



Surgical complications of bacille Calmette-Guérin (BCG) infection in HIV-infected children: Time for a change in policy?

J S Karpelowsky, A G Alexander, S Dix Peek, A J W Millar, H Rode

Aim. Bacille Calmette-Guérin (BCG) immunisation is well established as part of the South African national expanded programme for immunisation (EPI). The World Health Organization (WHO) currently recommends that BCG be given to all asymptomatic infants irrespective of HIV exposure at birth but does not recommend BCG vaccination for children with symptomatic HIV infection. This approach, however, has led to HIV-infected neonates who are asymptomatic at birth, developing severe vaccine-related complications. We present a surgical case series, representative of a minority of the cases in circulation, in support of a change to the timing of BCG administration to HIV-exposed neonates.

Methods. A case series of 17 HIV-infected patients with surgical complications of BCG vaccination.

Results. Seventeen patients are presented. The first two illustrate disseminated systemic BCG infection, resulting in BCG infection of the lymph nodes, liver, spleen and tibia, and the second with gastrointestinal involvement causing bowel obstruction. The other 15 patients represent a series of severe ulcerating lymphadenitis secondary to BCG.

Conclusion. The risks of BCG in HIV-infected infants are significant. Current recommendations are not satisfactory, and a change in policy is required to prevent the harmful effects of this vaccine in a high-risk group of patients. We believe that there is sufficient need to adequately stratify patients and vaccinate them according to a protocol that takes impaired immunity into consideration.

S Afr Med J 2008; 98: 801-804

Bacille Calmette-Guérin (BCG) immunisation is well established as part of the South African national expanded programme for immunisation (EPI). The World Health Organization (WHO) currently recommends that BCG be given to all asymptomatic infants irrespective of HIV exposure at birth. The same report, however, acknowledges the risks of disseminated BCG and does not recommend BCG vaccination for children with symptomatic HIV infection.¹ This recommendation does not take into consideration the fact that most vertically transmitted HIV-infected neonates are asymptomatic at birth, which has led to a significant number of immunocompromised patients developing severe vaccine-related complications.²⁻¹⁰ We present a surgical case series, representing a minority of the cases in circulation,^{3,4} in support of a change to the timing of BCG administration to HIV-exposed neonates.

Division of Paediatric Surgery, Red Cross War Memorial Children's Hospital and University of Cape Town

J S Karpelowsky, MD, FCS (SA), Cert Paed Surg (SA)
A G Alexander, MD, FCS (SA), Cert Paed Surg (SA)
S Dix Peek, MD, FCS (Ortho) (SA)
A J W Millar, MD, FRCS, FRACS
H Rode, MD, FCS (SA)

Corresponding author: J Karpelowsky (jonathan.karpelowsky@uct.ac.za)

Patients

Case 1

A 3-year-old HIV-infected boy first presented to our medical service at 11 months of age. He was noted to have firm, enlarged, matted axillary lymph nodes >3 cm in diameter; this was in keeping with BCG lymphadenitis of his right axilla. He also had pneumonia, oral thrush and neuro-developmental delay. He was subsequently started on highly active antiretroviral therapy (HAART). During this admission, he was diagnosed as having tuberculosis (TB), based on acid-fast bacilli (AFB)-positive gastric washings, and he was commenced on TB therapy. Owing to the presence of BCG adenitis, the systemic isolates of AFB were submitted to polymerase chain reaction (PCR) analysis and found to be *Mycobacterium bovis* rather than *M. tuberculosis*. He was discharged after 6 weeks of treatment, placed on 6 months of anti-TB treatment, and booked for regular follow-up, from which his caretakers defaulted. Almost a year later, he presented with multiple small subcutaneous abscesses evenly distributed over his trunk and limbs. Soft-tissue thickening over the tibial aspects of both lower legs was noted. Ultrasound of the abdomen revealed an enlarged spleen and liver; both revealed multiple focal hypodense lesions. The tibial thickening that had been detected clinically was not investigated further at the time. However, 2 months later he presented again with severe pain, subcutaneous inflammation and fluctuation over the



anterior surface of the medial aspect of the lower legs. X-ray changes included a localised osteopenia and a periosteal reaction (Fig. 1). Surgical intervention revealed bilateral tibial osteitis. Histological examination of bone biopsies confirmed osteitis secondary to *M. bovis* infection. In summary, this boy developed disseminated (lymph node, cutaneous, hepatic, splenic and osteal) BCG infection subsequent to routine immunisation.

Case 2

A 13-month-old HIV-infected boy presented with bile-stained vomiting and a distended abdomen. He was on HAART, and disseminated BCG was confirmed on PCR analysis of gastric washings. The initial working diagnosis was that of gastro-enteritis, but when the symptoms failed to resolve and abdominal distention became evident, he was referred for a surgical opinion. A diagnosis of small-bowel obstruction was made. Laparotomy identified a large group of ulcerating nodes, to which the omentum had attached and consequently caused the obstruction. The histology of node biopsy confirmed necrotising granulomatous inflammation due to disseminated BCG infection. There were no other bowel lesions.

Cases 3 - 17

In this series of 15 infants,¹¹ 14 had routine BCG vaccination, administered into the right deltoid area, during the first week of life. Vaccination was delayed for 2 weeks in 1 infant owing to perinatal sepsis. All the infants were HIV positive (PCR analysis). On average, the CD4 count was 664 cells/ μ l, with a range of 9 - 2 057 (normal values: 500 - 2 010). The average time from inoculation to the development of BCG complication was 6.8 months. Fourteen of the 15 infants were referred for surgery for management of right axillary abscesses or breakdown of nodes (Fig. 2). One child had disseminated disease as detected by gastric washings and positive PCR for *M. bovis*. Fourteen of the infants received HAART. In 10 patients, the implementation of HAART predated the complications of the BCG vaccine.

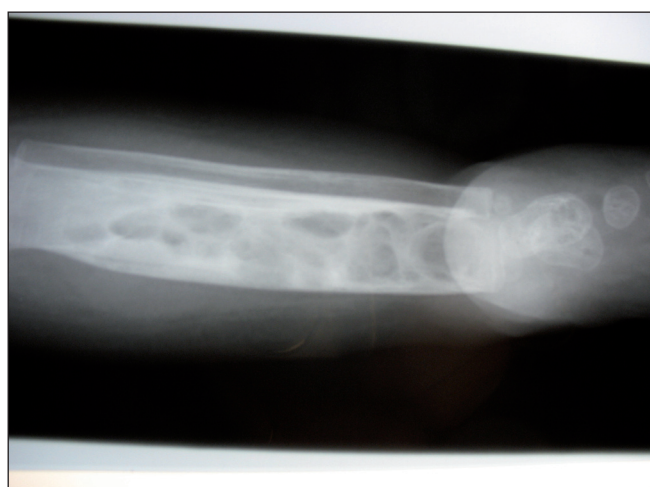


Fig. 1. X-ray of tibia: multiple lytic lesions.

The average time from starting HAART to the onset of symptoms was 1.4 months. Nine of the 15 infants were placed on TB treatment. A total of 22 interventions were performed

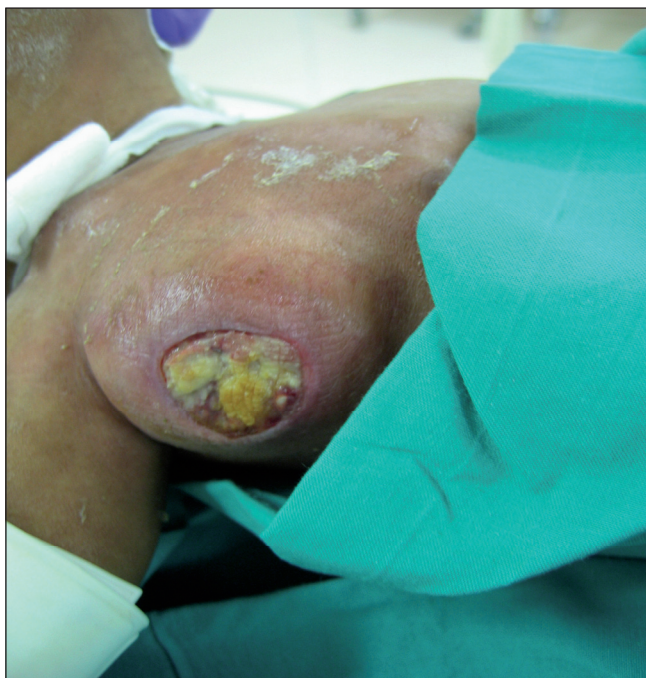

Fig. 2. Axillary BCG lymphadenitis with ulceration.

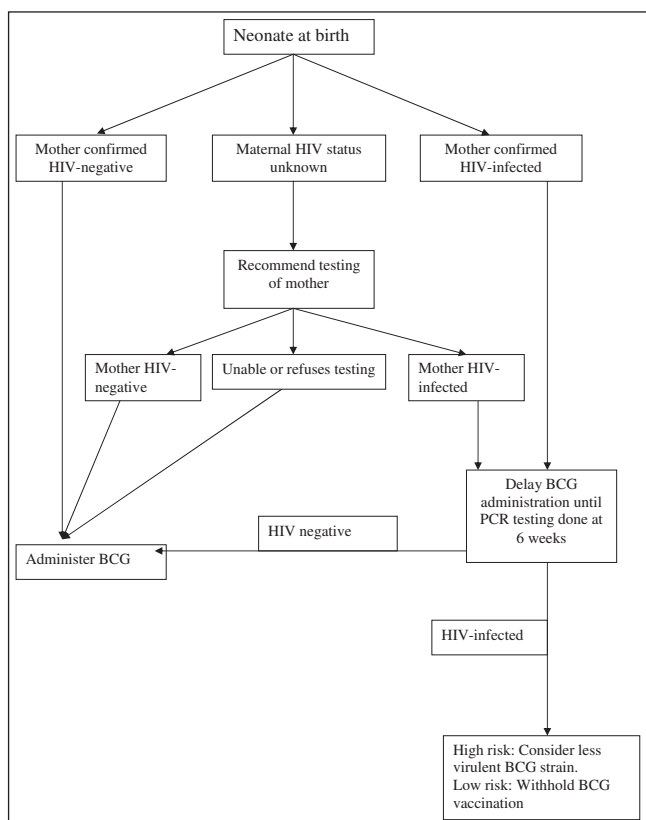


Fig. 3. Suggested algorithm for BCG vaccination in the context of the current HIV epidemic.



on 14 patients. One infant required no surgical intervention. Five were treated with at least 1 aspiration; 7 incisions and drainages were performed; and 6 had at least 1 curettage of the involved nodes. Two axillary lymphadenectomies were performed. One child had 1 aspiration, 1 incision and drainage and 4 curettages. Of the 11 patients who had histological analysis, all had the classic features of a caseating granulomatous lesion. All 14 patients who had had TB cultures performed, grew mycobacteria with subsequent PCR analysis confirming *M. bovis*.

Discussion

South Africa currently uses the intradermal Danish 1331 strain of live attenuated *M. bovis* in the BCG immunisation administered at birth. The efficacy and safety of this vaccine in immune-competent individuals is well demonstrated, with only a few adverse effects.⁵ There are, however, growing concerns over the morbidity and mortality of BCG immunisation in HIV-infected children – a disease process that may be preventable.²⁻¹⁰

BCG disease may take several forms and should be distinguished from the expected reactions induced by the vaccine. An appropriate response would include a shallow, dry, crusted ulcer at the injection site and regional lymphadenopathy that should not exceed 1 cm in diameter. It is considered pathological if deep ulcers or abscesses develop at the injection site, gross lymphadenitis or suppuration develops in the axilla,¹¹ or disseminated disease is detected.¹² The extent of BCG disease is difficult to estimate but the growing epidemic of BCG lymphadenitis may serve as a marker for disseminated infection, and would suggest a marked rise in the incidence of BCG disease. The relative paucity of reports in the literature underestimates the true prevalence, as disseminated and local BCG disease in HIV-infected children is under-reported, especially in settings highly endemic for TB and HIV, where diagnostic facilities are often limited.⁸ Even if acid-fast mycobacteria are detected, the disease is often mislabelled as TB owing to the failure to test adequately for the correct mycobacterium species by means of PCR analysis.¹³ The complex and expensive process required to diagnose *M. bovis*, combined with a culture of under-reporting of adverse drug and vaccine events in South Africa, has added to the problem.⁴ Hesseling *et al.* have developed models to predict the potential scale of the epidemic and estimate the true prevalence to be 110 - 417/100 000 vaccinees (depending on HIV prevalence and rate of vertical transmission), with the risk of disseminated BCG disease being 100 times greater for HIV-infected infants.³

There are several clinical implications of BCG infection in HIV-infected children. The optimum treatment for both disseminated and local BCG disease is poorly defined. Inherent

resistance of BCG to pyrazinamide¹⁴ and the possibility of extended resistance patterns^{15,16} have made medical treatment more complex and is compounded by the poor response to therapy observed in HIV-infected children with BCG disease and the suggested duration of therapy of 9 months.⁴ Treatment with anti-TB drugs will also have an impact on any concomitant antiretroviral therapy that is prescribed, and adverse drug interactions are well described.^{17,18}

The treatment of loco-regional disease is somewhat more controversial. An important subgroup has been identified in those patients who develop significant regional lymphadenopathy or a worsening of existing disease following the implementation of HAART. This, we believe, represents immune reconstitution inflammatory syndrome (IRIS).¹⁹⁻²³ It is uncertain whether these conditions should be managed differently or whether they represent the same risk for potential dissemination in HIV-infected infants. Some authors feel that the risk of BCG spread together with the poor outcome in HIV-infected infants mandate systemic medical and, in some cases, surgical therapy.⁴ The concerns over interference with antiretrovirals have made other authors more reticent.¹⁸ The surgical management of node excision has been well described²⁴ for both therapeutic and cosmetic reasons.²⁵ Potential complications of wound breakdown, sinus development and damage to vital neighbouring structures need to be taken into consideration.¹¹ With the growing number of HIV-infected infants both immunised with BCG and on antiretrovirals, the IRIS BCG lymphadenopathy epidemic is growing exponentially. Frustrated parents and physicians are increasingly likely to look for surgical solutions to an extremely morbid condition.

It is ironic that a vaccine developed to protect children from severe mycobacterial infection is now, in a subset of patients, causing significant mycobacterial disease. Current recommendations¹ of giving the BCG vaccine to all asymptomatic infants, regardless of HIV exposure, is problematic. At present, the selective administration of the BCG vaccine is not possible in the absence of antenatal maternal screening and neonatal symptoms of HIV disease. All the infants in our study, and those in others⁵ who went on to develop BCG disease, were asymptomatic at birth. Apart from the risks of BCG infections, there are also concerns that BCG vaccination may accelerate the progression of HIV disease in HIV-infected infants.⁴ Given the benefits of BCG vaccination in non-HIV-infected infants and the real risks to HIV-infected infants, we would argue that a change in the timing of BCG administration should take place, especially if predictions³ of BCG disease among HIV-infected infants hold true.

Most of the BCG disease that is seen can be prevented by adopting a stratified policy for the timing of BCG administration. Our proposal is that infants of mothers who test positive for HIV during their antenatal care should not



have their BCG vaccination at birth but rather have it delayed to the second vaccination visit, at which time the infants' HIV status can be determined (Fig. 3). If an infant is HIV-infected, BCG vaccination should be with a less virulent strain or withheld. If an infant is HIV-negative, the vaccine can be given. It would therefore be possible to prevent those infants most at risk from BCG disease from becoming exposed to BCG, while not prejudicing those who would benefit from its administration. This problem will hopefully be solved with the advent of an effective vaccine that is not alive and attenuated; this process is well under way.

Conclusion

BCG disease is a growing epidemic. TB in BCG-exposed HIV-infected children needs to be differentiated from *M. tuberculosis* as it mandates different treatment. The risks of BCG in HIV-infected infants are significant. Current recommendations are not satisfactory, and a change in policy is required to prevent the harmful effects of this vaccine in a high-risk group of patients. Current policy focuses on the most reliable point of contact and does not place enough emphasis on the potential dangers of live attenuated vaccines in immunocompromised infants. We believe that there is sufficient need to stratify our patients adequately and vaccinate them according to a protocol that takes impaired immunity into consideration.

References

1. World Health Organization. Global Advisory Committee on Vaccine Safety, 29-30 November 2006. *Wkly Epidemiol Rec* 2007; 82(3): 18-24.
2. Campos JM, Simonetti JP, Pone MV, Carvalho LA, Pereira AC, Garrido JR. Disseminated Bacillus Calmette-Guérin infection in HIV-infected children: case report and review. *Pediatr AIDS HIV Infect* 1996; 7(6): 429-432.
3. Hesseling AC, Marais BJ, Gie RP, et al. The risk of disseminated bacille Calmette-Guérin (BCG) disease in HIV-infected children. *Vaccine* 2007; 25(1): 14-18.
4. Hesseling AC, Rabie H, Marais BJ, et al. Bacille Calmette-Guérin vaccine-induced disease in HIV-infected and HIV-uninfected children. *Clin Infect Dis* 2006; 42(4): 548-558.
5. Hesseling AC, Schaaf HS, Hanekom WA, et al. Danish bacille Calmette-Guérin vaccine-induced disease in human immunodeficiency virus-infected children. *Clin Infect Dis* 2003; 37(9): 1226-1233.
6. Raton JA, Pocheville I, Vicente JM, et al. Disseminated bacillus Calmette-Guérin infection in an HIV-infected child: a case with cutaneous lesions. *Pediatr Dermatol* 1997; 14(5): 365-368.
7. Rosenfeldt V, Paerregaard A, Valerius NH. Disseminated infection with Bacillus Calmette-Guérin in a child with advanced HIV disease. *Scand J Infect Dis* 1997; 29(5): 526-527.
8. Talbot EA, Perkins MD, Silva SF, Frothingham R. Disseminated bacille Calmette-Guérin disease after vaccination: case report and review. *Clin Infect Dis* 1997; 24(6): 1139-1146.
9. Thaitumyanon P, Thisyakorn U, Punnahitananda S, Praisuwanna P, Ruxrungtham K. Safety and immunogenicity of bacillus Calmette-Guérin vaccine in children born to HIV-1 infected women. *Southeast Asian J Trop Med Public Health* 2000; 31(3): 482-486.
10. Waddell RD, Lishimpi K, von Reyn CF, et al. Bacteremia due to *Mycobacterium tuberculosis* or *M. bovis*, Bacille Calmette-Guérin (BCG) among HIV- positive children and adults in Zambia. *AIDS* 2001; 15(1): 55-60.
11. Alexander A, Rode H. Adverse reactions to the bacillus Calmette-Guérin vaccine in HIV-positive infants. *J Pediatr Surg* 2007; 42(3): 549-552.
12. Fine PEM, Carneiro IAM, Milstein JB, Clements CJ. *Issues Relating to the Use of BCG Immunisation Programmes – a Discussion Document No. WHO/V&B/99.23*. Geneva: World Health Organization, 1999.
13. Talbot EA, Williams DL, Frothingham R. PCR identification of *Mycobacterium bovis* BCG. *J Clin Microbiol* 1997; 35(3): 566-569.
14. Diagnostic Standards and Classification of Tuberculosis in Adults and Children. *Am J Respir Crit Care Med* 2000; 161(4 Pt 1): 1376-1395.
15. Hesseling AC, Schaaf HS, Victor T, et al. Resistant *Mycobacterium bovis* Bacillus Calmette-Guérin disease: implications for management of Bacillus Calmette-Guérin disease in human immunodeficiency virus-infected children. *Pediatr Infect Dis J* 2004; 23(5): 476-479.
16. Sicevic S. Generalized BCG tuberculosis with fatal course in two sisters. *Acta paediatrica Scandinavica* 1972; 61(2): 178-184.
17. Cotton MF, Schaaf HS, Hesseling AC, Madhi SA. HIV and childhood tuberculosis: the way forward. *Int J Tuberc Lung Dis* 2004; 8(5): 675-682.
18. Swaminathan S, Luetkemeyer A, Srikanthiah P, Lin R, Charlebois E, Havlir DV. Antiretroviral therapy and TB. *Trop Doct* 2006; 36(2): 73-79.
19. Kroidl A, Huck K, Weinspach S, et al. Immune reconstitution inflammatory syndrome (IRIS) due to Bacille Calmette-Guérin (BCG) in an HIV-positive child. *Scand J Infect Dis* 2006; 38(8): 716-718.
20. Narendran G, Swaminathan S, Sathish S, Rajasekaran S. Immune reconstitution syndrome in a child with TB and HIV. *Indian J Pediatr* 2006; 73(7): 627-629.
21. Puthanakit T, Oberdorfer P, Akarathum N, Wannarit P, Sirisanthana T, Sirisanthana V. Immune reconstitution syndrome after highly active antiretroviral therapy in human immunodeficiency virus-infected Thai children. *Pediatr Infect Dis J* 2006; 25(1): 53-58.
22. Puthanakit T, Oberdorfer P, Punjaisee S, Wannarit P, Sirisanthana T, Sirisanthana V. Immune reconstitution syndrome due to bacillus Calmette-Guérin after initiation of antiretroviral therapy in children with HIV infection. *Clin Infect Dis* 2005; 41(7): 1049-1052.
23. Siberry GK, Tessema S. Immune reconstitution syndrome precipitated by bacille Calmette-Guérin after initiation of antiretroviral therapy. *Pediatr Infect Dis J* 2006; 25(7): 648-649.
24. Hengster P, Solder B, Fille M, Menardi G. Surgical treatment of bacillus Calmette-Guérin lymphadenitis. *World J Surg* 1997; 21(5): 520-523.
25. Grange JM. Complications of bacille Calmette-Guérin (BCG) vaccination and immunotherapy and their management. *Commun Dis Public Health* 1998; 1(2): 84-88.

Accepted 15 December 2007.