



CLINICAL IMAGES

Chondral fracture of the femoral trochlea

R V P de Villiers, P J Erasmus

Osteochondral lesions of the femoral trochlea are rare. They may involve only the cartilage (chondral lesion), the cartilage and subchondral bone (true osteochondral lesion) or the subchondral bone in isolation with an intact overlying cartilage (subchondral lesion).

Clinical presentation

A 17-year-old boy injured the medial aspect of the knee during a soccer game. He described a feeling suggestive of a loose fragment in the joint.

On examination there was a moderate effusion, no instability was present and there was tenderness over the medial joint line. Aspiration of the effusion yielded clear synovial fluid. Standard X-rays were negative.

A diagnosis of a possible medial meniscal tear was made and magnetic resonance imaging (MRI) of the knee was requested. A subtle chondral lesion of approximately 0.4 cm was noted on the MRI axial and coronal STIR sequences (Fig.1). There was no associated subchondral bone marrow oedema. A possible loose chondral body was demonstrated in the posterior joint space. There was no meniscal tear or ligamentous abnormality.

At arthroscopy the medial and lateral compartments of the knee and the patella were normal. A grade A4 lesion of the femoral trochlea was noted; it was debrided and microfractures were made with an ice pick.

The postoperative period was uncomplicated and limited knee extension against resistance was advised.

The prognosis was good, with low-grade anterior knee pain a possible long-term complication.

Richard de Villiers is a specialist radiologist at the Stellenbosch Medi-Clinic. He has a special interest in musculoskeletal and sports injury imaging and is a member of the Stellenbosch Sport and Musculoskeletal Forum and chairman of the SA Musculoskeletal Imaging Group.

Dr Erasmus is in private practice at the Stellenbosch Medi-Clinic. A specialist knee surgeon with a special interest in the patello-femoral joint, he was the recipient of the gold medal award for the best paper presented at the 1991 SASMA Congress and has presented numerous papers at local and international orthopaedic congresses. He is the founder of the Stellenbosch Sport and Musculoskeletal Forum.

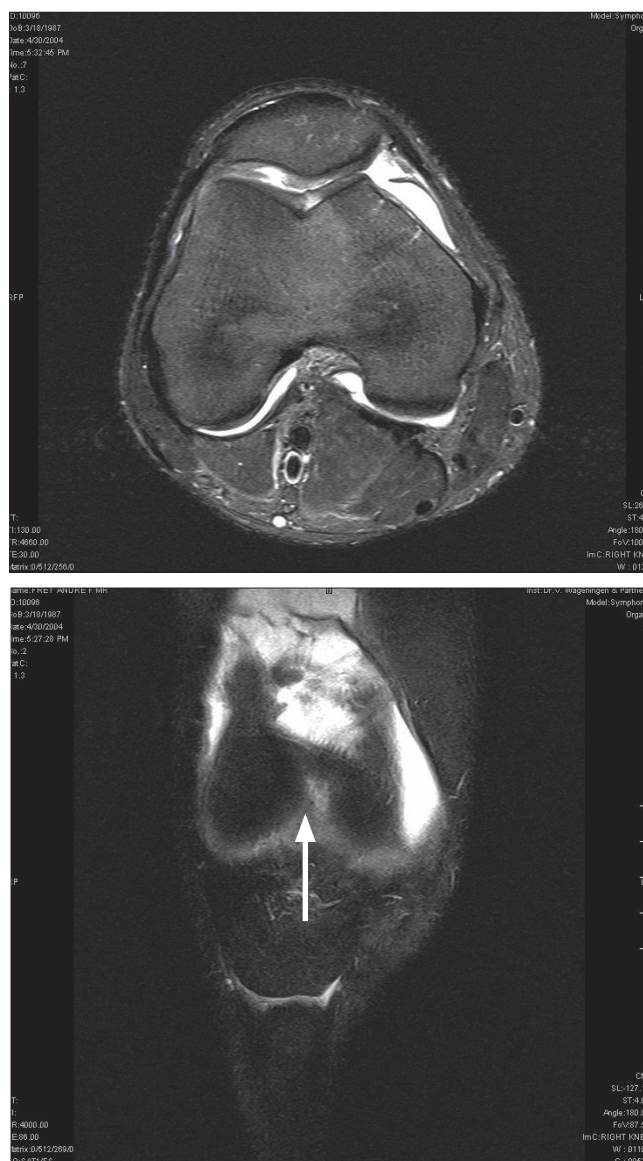


Fig. 1. MRI showing subtle osteochondral injury of the femoral trochlea.

Discussion

Osteochondritis dissecans usually involves the weight-bearing hyaline surfaces of the knee. The medial compartment is four times more commonly involved than the lateral compartment. The size of the lesion may vary from a small chondral defect



(mm) to a larger area of cartilage loss with involvement of the subchondral bone.

Clinically the most common signs are intermittent locking, recurrent effusions, crepitus and persistent pain. The condition usually occurs in younger patients and more commonly in males.

Plain-film findings are usually negative, but a subchondral fracture may be seen and in chronic cases there may be subchondral sclerosis. Computed tomography (CT) may or may not demonstrate the subchondral fracture and sclerosis. CT arthrography may demonstrate the chondral defect filled with contrast. MRI is the non-invasive test of choice, as both chondral and subchondral lesions are seen. The associated subchondral fracture or oedema appears hypointense and the chondral defect with or without the associated subchondral

bone marrow oedema is usually demonstrated. In some cases MR arthrography may demonstrate subtle cartilage lesions.¹

The characteristic features of osteochondritis dissecans of the trochlea of the femur differ from those of the more familiar femoral condylar form.² Features include gradual onset of symptoms, pain on running and jumping, no significant history of injury, inconsistent tenderness of the trochlea, and pain with resisted extension at 20° - 45°. Diagnosis is usually difficult and is often delayed because of subtle radiographic changes. Although reported results (average follow-up more than 5 years) are generally good, the mild symptoms probably represent incongruity of the patellofemoral joint, and probably foretell osteoarthritis.²

1. Anderson IF, Read J, Steinweg J. *Atlas of Imaging in Sports Medicine*. Sydney: McGraw-Hill, 1998: 210-212.

2. Smith JB. Osteochondritis dissecans of the trochlea of the femur. *Arthroscopy* 1990; 6(1): 11-17.

HISTORY OF MEDICINE

Periodic pyrexia and malaria in antiquity

Francois Retief, Louise Cilliers

Although malaria is today still an international scourge affecting 300 - 500 million people in mostly tropical and subtropical regions and causing approximately 2 million deaths per annum,¹ evidence shows that it is an ancient disease.² This study reviews its occurrence during antiquity and classical times, particularly in the Mediterranean areas.

Modern concepts

The name 'malaria' derives from 'mal aria' (bad air) in Italian and was probably first used by Carnaro in a publication of 1440. Theories regarding malaria's miasmatic origins were only dispelled in the late 19th century when Manson (1877) described the malarial cycle with the mosquito as vector, and

Laveran (1880) discovered the causative parasite in human blood.^{2,3}

Of the four species of malarial parasite (*Plasmodium*) causing human malaria, *P. ovale* occurs only in West Africa, while *P. falciparum*, *P. vivax* and *P. malariae* were found in the Mediterranean basin until quite recently. DNA-sequencing studies show that *P. falciparum* originated 165 million years ago, probably in the Central Lakes area of Africa. Because of its intolerance of temperatures below 20°C, it probably migrated to the Mediterranean area only after termination of the last Ice Age, approximately 15 000 - 20 000 years ago. *P. vivax* and *P. malariae* probably originated in South-East Asia, and being tolerant of colder temperatures, possibly moved west at an earlier stage.²

Humans are infected only through the bite of the female *Anopheles* mosquito, which breeds in well-aerated standing water. They can fly only a few kilometres in non-windy conditions, and characteristically enter dwellings to bite after dark. *Anopheles* mosquitoes are found in fossils of at least 26 - 38 million years old, and species like *A. sacharowi* and *A. labranchiae*, which caused Mediterranean malaria in modern times, probably existed there in Classical times and earlier.^{1,2}

Clinical picture¹⁻³

Because of the mosquito's breeding requirements, malaria typically shows a seasonal incidence, highest in the warm and wet months. After entering the body and replicating in the liver

Francois Retief was founding Dean of Medicine at the University of the Orange Free State, first full-time Vice-Chancellor of the Medical University of Southern Africa, and Director-General of National Health, before ending his academic career as Vice-Chancellor of the Free State University. Since retirement he has been researching diseases of antiquity.

Louise Cilliers studied at Pretoria University and then at the Rijksuniversiteit, Leiden, Netherlands where she obtained a Drs Litt et Phil in Latin, Greek and History of Antiquity. She subsequently taught at the University of South Africa, the University of Natal and Rand Afrikaans University before being appointed Professor of Latin at the Free State University, where she is currently Senior Professor and Head of Classical Languages.