



and illness durations of 8 and 17 months respectively. An Austrian patient without PSD survived 5 months from onset.⁵ Kimura *et al.*⁶ reported a patient with imaging unchanged throughout his illness, who developed PSD just 2 days before death, 13 months after onset of symptoms. The case described by Takashima *et al.*,⁷ without PSD and with normal serial computed tomography (CT) scans, survived 17 months from onset. An American patient grafted with a Tutoplast patch survived 4 months from onset; imaging failed to assist diagnosis, while the EEG revealed only moderate to diffuse slowing.⁸ Interestingly, plaque formation was noteworthy in a number of these reports.^{5,6,8}

Our case and the literature reports suggest that disease duration may be shorter in patients who do not show PSDs or in whom PSDs develop late. Subsets of graft-associated CJD may exist; this, together with host characteristics, might explain the differing clinical courses and disease phenotypes seen in graft-associated CJD.

Conclusion

Our report adds to the approximately 169 cases of dural graft-associated CJD cases.⁹ It supports the view that graft-associated CJD patients are younger than sporadic CJD cases,

and are more likely to present with cerebellar abnormalities. Brain imaging without diffusion weighting may not always contribute to the diagnosis. We note an interesting association between delayed or absent PSDs and short illness duration.

Dr Andre Leonard, consultant neurologist in George, and Dr Steve van Niekerk, consultant neurologist in Bloemfontein South Africa, are thanked for their invaluable assistance. The reviewer is thanked for his comments.

1. Brown P, Preece M, Brandel JP, *et al.* Iatrogenic Creutzfeldt-Jakob disease at the millennium. *Neurology* 2000; **55**: 1075-1081.
2. Hoshi K, Yoshino H, Urata J, Nakamura Y, Yanagawa H, Sato T. Creutzfeldt-Jakob disease associated with cadaveric dura mater grafts in Japan. *Neurology* 2000; **55**: 718-721.
3. Centers for Disease Control. Update: Creutzfeldt-Jakob disease associated with cadaveric dura mater grafts – Japan, 1979 - 2003. *MMWR Morb Mortal Wkly Rep* 2003; **52**: 1179-1181.
4. Shimizu S, Hoshi K, Muramoto T, *et al.* Creutzfeldt-Jakob disease with florid-type plaques after cadaveric dura mater grafting. *Arch Neurol* 1999; **56**: 357-362.
5. Radbauer C, Hainfellner JA, Gaudernak T, Deecke L, Budka H. Creutzfeldt-Jakob disease in a dura transplant recipient: first observation in Austria. *Wien Klin Wochenschr* 1998; **110**: 496-500.
6. Kimura K, Nonaka A, Tashiro H, *et al.* Atypical form of dural graft associated Creutzfeldt-Jakob disease: report of a postmortem case with review of the literature. *J Neurol Neurosurg Psychiatry* 2001; **70**: 696-699.
7. Takashima S, Tateishi J, Taguchi Y, *et al.* Creutzfeldt-Jakob disease with a widespread presence of kuru-type plaques after cadaveric dural graft replacement. An autopsy case. *Rinsho Shinkeigaku* 1997; **37**: 824-828.
8. Hannah EL, Belay ED, Gambetti P, *et al.* Creutzfeldt-Jakob disease after receipt of a previously unimplicated brand of dura mater graft. *Neurology* 2001; **56**: 1080-1083.
9. Martinez-Lage JF, Rabano A, Bermejo J, *et al.* Creutzfeldt-Jakob disease acquired via a dural graft: failure of therapy with quinacrine and chlorpromazine. *Surg Neurol* 2005; **64**: 542-545.

FORENSIC FILES

Lodox Statscan proves to be invaluable in forensic medicine

G J Knobel, G Flash, G F Bowie

The Statscan (Lodox Systems Pty (Ltd), Sandton, South Africa) is a low-dose, digital full-body X-ray machine designed specifically for use in hospital trauma units. The technology was developed by De Beers to be used in X-ray machines that could rapidly determine the location of stolen diamonds on workers using a low radiation dose. The machine makes use

Deon Knobel is Emeritus Professor, Department of Forensic Medicine, Faculty of Health Sciences, University of Cape Town. Greg Flash is Research Manager, Lodox Systems, Cape Town. G F Bowie is Head Radiographer at Groote Schuur Hospital and Assistant Director, Radiographic Services, Department of Health, Provincial Government of the Western Cape.

Corresponding author: G J Knobel (knobel@icon.co.za)

of a thin fan-beam X-ray that is scanned down the length of the patient in 13 seconds. A proprietary digital detector consisting of CCD cameras and fiberoptic tapers produces a full-body actual-size image of the patient, which is viewed on a dedicated 21-inch digital viewing station.

The Statscan is approved by the Food and Drug Administration in the USA and has received European Union certification for sale in Europe.

The benefits of the Statscan to trauma radiology are its low dosage to patients and operators, ease of use and ability to provide a full-body image, and the speed of image acquisition.

The Statscan was clinically evaluated at Groote Schuur Hospital's Trauma Unit and is being evaluated for paediatric radiography at Red Cross Children's Hospital. Findings from both sites have been very positive, resulting in the sale and installation of 8 machines in the USA and 2 machines in Sudan.



Forensic laboratory applications

During evaluation of the Statscan at the Groote Schuur Trauma Unit, bodies suspected to contain bullets and other foreign bodies were referred from the Salt River Medicolegal Laboratory to the X-ray department at Groote Schuur Hospital by the Division of Forensic Medicine. The Statscan was found to be particularly useful in determining the presence of foreign objects such as bullets. The images produced greatly assisted the forensic pathologists in autopsy examinations, particularly by reducing the time taken to examine a body.

Large medico-legal laboratories admit up to 3 500 to 4 000 bodies per year for autopsy. In Cape Town half of these are due to murders (1 500 per annum) of which half again are caused by firearms.

After a death due to gunshot injury, it is important to retrieve and mark all bullets found in the body. Each bullet must be carefully marked at its base, so as not to damage the rifling pattern along the side of the bullet, which is important for ballistic investigations. In cases of multiple bullets, where more than one firearm may have been used, it is also important to mark the site each bullet was retrieved from. Without a reliable X-ray facility the process of retrieving bullets may be lengthy and cumbersome, especially in cases where the bullet may have deflected against bone and changed direction. Correct location of bullets may be almost impossible to establish when they are lodged in bone. Standard X-rays require multiple fields to do a full-body survey. The use of a C-arm X-ray machine solves some of the problems, but requires the arm of the machine to be moved many times, with the danger of missing a bullet in the area between the settings. Both require films that have to be developed, and there is potential for high radiation exposure among staff.

The Statscan/Lodox system has clearly demonstrated the following advantages in a medico-legal unit.

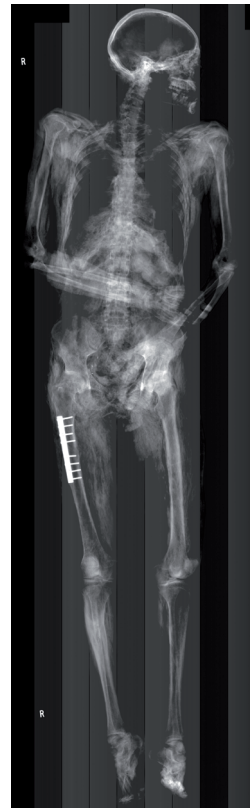

Fig. 1 (left). Decomposed body on which some identification had been found. Cause of death undetermined. A Lodox scan revealed no bullets, but plate and screws in the right upper femur confirmed identification.

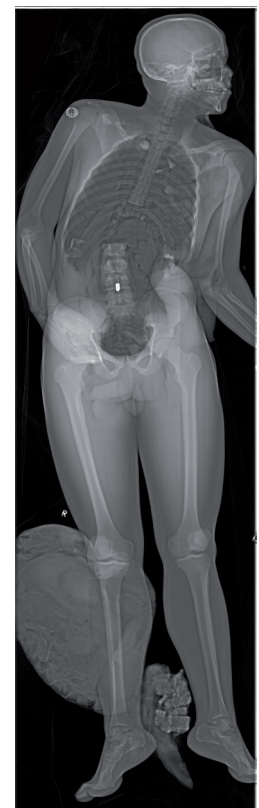

Fig. 3 (right). Firearm fatality with single bullet wound in the chest. The lower thoracic vertebrae were removed at autopsy in a failed search for the bullet. A Lodox scan revealed that the bullet had lodged in the lumbar vertebrae.

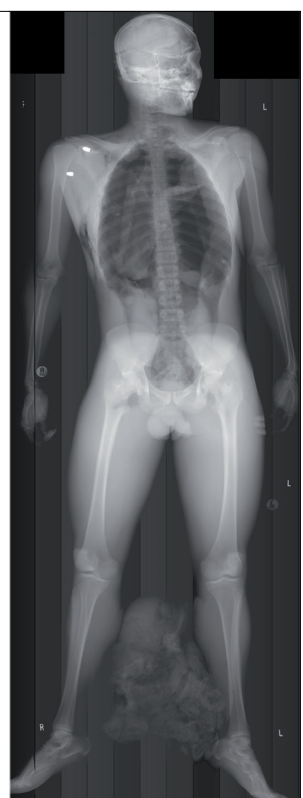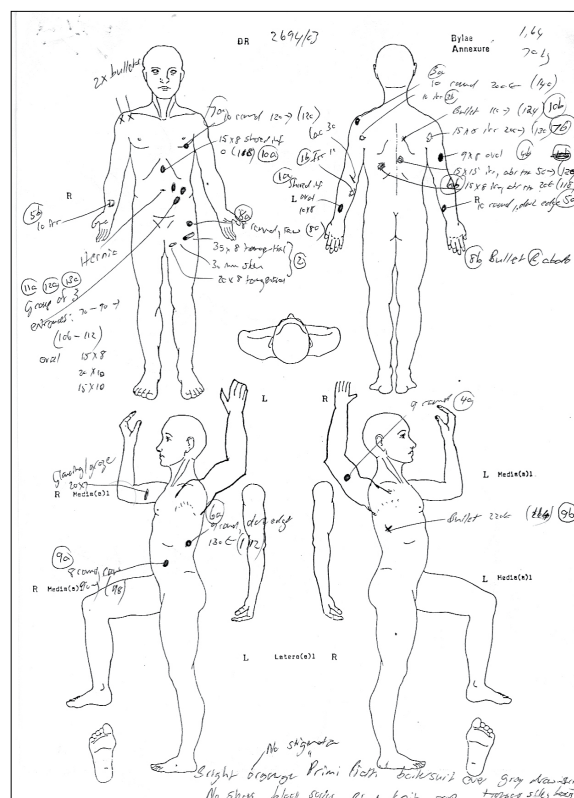


Fig. 2. Firearm fatality, multiple bullet wounds with difficulty in establishing entrance and exit wounds and defects (see sketch). Corresponding wound tracks were therefore difficult to establish. Retained bullets were suspected, but a Lodox scan revealed only two, in the right shoulder.