



Liver cysts in Congolese patients with autosomal dominant polycystic kidney disease follow a family pattern

A G H Assounga, Y Yacoubou, E Makosso, J R Ibara, T Gombet

Background. It is now well established that at least two genes are associated with autosomal dominant polycystic kidney disease (ADPKD).

Objective. To analyse the clinical expression of ADPKD in Congolese patients and to compare ADPKD expression between families.

Methods. Following informed consent, ADPKD patients admitted to Brazzaville University Hospital (Congo) were reviewed and their relatives aged 20 years and older were screened by means of a clinical examination, abdominal ultrasound, urinalysis and determination of serum creatinine.

Results. We found 7 patients with ADPKD, belonging to 7

distinct families, and identified 100 relatives of whom 50, aged from 20 to 68 years, were diagnosed as having ADPKD. Polycystic kidney disease was associated with polycystic liver in 4 families. In the remaining 3 families no liver cysts were found. No family had a mixture of members with kidney cysts only and members with kidney and liver cysts. This finding was age-independent.

Conclusion. Liver cysts follow a family pattern in our ADPKD patients. We suggest that our patients may carry at least two different genes for ADPKD, one of which may be associated with renal cysts alone and other with both renal and liver cysts.

S Afr Med J 2003; 93: 542-544.

Autosomal dominant polycystic kidney disease (ADPKD), a common hereditary disease worldwide, is not well documented in Africa, with only a few reports available.^{1,3} ADPKD is one of the most frequently inherited disorders, with a prevalence ranging from 1/400 to 1/1 000 in Europe and America.⁴ Much progress has been made in characterising the genes involved and their products. ADPKD is characterised by an adult clinical onset, the presence of at least three kidney cysts bilaterally, and an autosomal dominant transmission.⁴ ADPKD is reported to be associated with at least two genes. The PKD1 gene is located on chromosome 16p3.3, and the PKD2 gene on chromosome 4q21-23.^{5,7} Their products are membrane-bound proteins that are expressed in most epithelial tissue and the brain.⁷ They interact and function as hetero-

dimers. Patients with ADPKD have higher expression of both alleles, raising the question whether PKD1 is the triggering factor for cyst formation or whether it is a secondary factor. It has been associated with the maturation and repair of the renal tubule. The PKD1 gene is associated with early and severe symptoms, while PKD2 and other genes are associated with late and less severe symptoms.⁸ In light of the diversity of genes involved we examined the expression of ADPKD in Congolese patients. The objective of this study was to analyse the clinical features of ADPKD in patients admitted to the Department of Nephrology and Haemodialysis at Brazzaville University Hospital from December 1989 to February 1995, as well as the clinical features of their respective family members.

Materials and methods

All patients admitted to the Department of Nephrology and Haemodialysis from December 1989 to March 1994 who had at least three cysts in each kidney on abdominal ultrasonography, were at least 20 years old, and had a family history suggestive of hereditary disease were included. Patients were excluded if there was no family history of polycystic kidney disease or if renal cysts were absent in relatives. Patients who developed renal cysts after a long period of dialysis were also excluded. Seven patients were identified.

After giving informed consent, relatives of patients underwent a clinical examination, a serum creatinine test, urinalysis, an abdominal ultrasound scan, and monthly follow-up for 6 months if found to have polycystic kidney disease.

Department of Nephrology and Haemodialysis, Centre Hospitalier Universitaire and Marien Ngouabi University, Brazzaville, Congo

A G H Assounga, MD, MSc, CES, PhD

Y Yacoubou, MD

Department of Radiology, Centre Hospitalier Universitaire and Marien Ngouabi University, Brazzaville, Congo

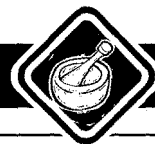E Makosso, MD, DIS

Department of Gastroenterology, Centre Hospitalier Universitaire and Marien Ngouabi University, Brazzaville, Congo

J R Ibara, MD, DIS

Department of Cardiology, Centre Hospitalier Universitaire and Marien Ngouabi University, Brazzaville, Congo

T Gombet, MD, CES



The chi-square test or Fisher's exact test was used to compare different groups, using the Instat 2 software program (GraphPad Instat, San Diego, Calif., USA).

Results

We found that the patients who fulfilled the criteria for ADPKD belonged to 7 distinct families. Of 100 relatives of patients screened, 50 were found to have ADPKD. The total number of patients with ADPKD was therefore 57 (7 symptomatic and 50 asymptomatic). Ages ranged from 25 to 68 years. There were 34 men and 23 women.

Clinical features are summarised in Table I (Figs 1 and 2). Clinical symptoms and signs seemed more severe in the 4 families with associated liver cysts, but the difference was not statistically significant ($p > 0.05$), except for the presence of anal fistula ($p = 0.0012$). A high prevalence of anal fistula was found in one of the families with polycystic liver and kidney disease; no colonoscopy was done to search for diverticulitis. No pancreatic cysts or other organ cysts were found. No search for cerebral aneurysm was carried out. The pattern of organ involvement was similar in patients within the same family. Polycystic kidney disease was associated with polycystic liver in 4 families. In the remaining 3 families, no liver cysts were found. No family included a mixture of patients with kidney cysts only and patients with kidney and liver cysts. This finding was age-independent. In families with ADPKD where 1 member had hepatic cysts all the relatives with kidney cysts also had hepatic cysts (Fig. 3). The presence or absence of hepatic cyst follows a family pattern (Figs 3 and 4). All families ran true to form, showing either renal cysts alone or both renal and liver cysts, but never a combination of both patterns within a single family.

Discussion

ADPKD is prevalent in the Congo and its clinical expression mirrors that described elsewhere. The pattern of clinical manifestation suggests that more than one gene is involved. In 4 of 7 families, kidney cysts were associated with liver cysts. The association of liver cysts with kidney cysts is thought to be a poor prognostic factor.⁹ In our study, patients with only kidney cysts seemed to have less severe manifestations than those with both kidney and liver cysts; however the difference was not statistically significant. Clinical manifestations in our ADPKD patients were similar to those described elsewhere.¹⁴ However, the incidence of ADPKD is lower than in Europe or the USA. A lower incidence of ADPKD has been reported in black Americans compared with whites.⁴ Clinical expression is characterised by low back pain, abdominal mass and haematuria as main complaints leading to the diagnosis of ADPKD. Hypertension was found in 7% of our patients.

Table I. Clinical manifestations of ADPKD according to presence or absence of liver cysts

Clinical manifestations	ADPKD patients with liver cysts		ADPKD patients without liver cysts		Total	
	cysts		liver cysts			
	N	%	N	%	N	%
Number of families	4	57	3	43	7	100
Number of patients	37	65	20	35	57	100
Hypertension	5	13.5	2	10	7	12.3 ($p > 0.05$)
Renal failure	6	16.2	2	10	8	14 ($p > 0.05$)
Abdominal pain	4	11	3	15	7	12
Macroscopic haematuria	7	19	4	19	11	19.3
Urinary tract infection	4	10.8	3	15	7	12.3
Stroke	1	2.7	0	0	1	1.8
Anal fistula	20	25	0	0	20	35 ($p = 0.0012$)

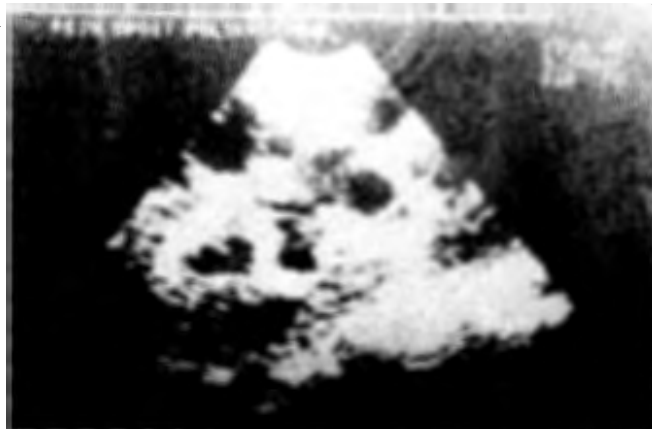

Fig. 1. Ultrasound scan of a kidney showing multiple cysts.

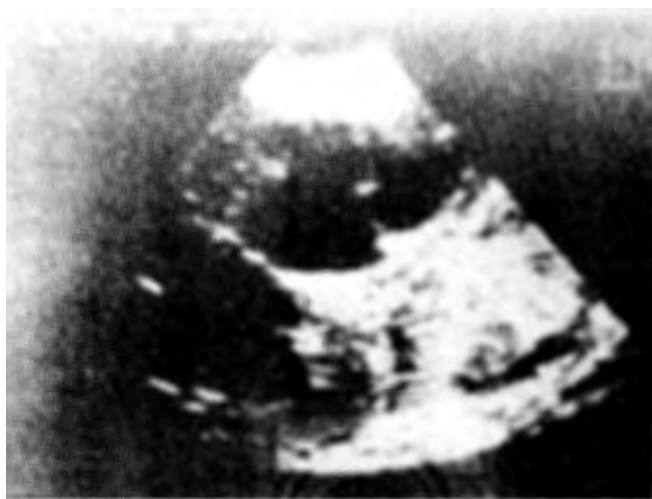

Fig. 2. Ultrasound scan of a liver showing multiple cysts.

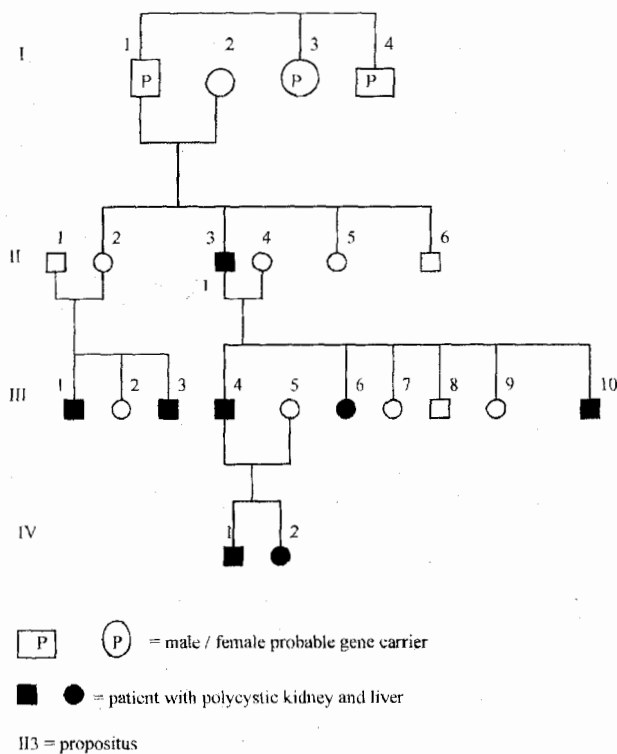
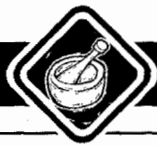

Fig. 3. Pedigree of a family with patients with both multiple renal and liver cysts.

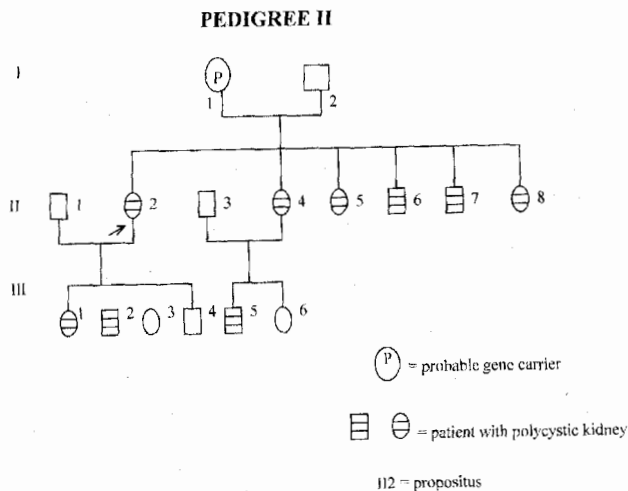


Fig. 4. Pedigree of a family with patients with multiple cysts only in the kidney.

ADPKD genes are widely expressed. Polycystin 1 and polycystin 2 have been found in all major organs, including the liver and kidney. The highest expression of polycystin has been found in the brain. The kidney has an intermediate level expression of polycystin. In normal individuals, polycystin is found in the cytoplasm and is markedly present in the lateral junction of epithelial cells of the distal tubule in the normal kidney, and of the proximal tubule in the injured kidney. In patients with ADPKD there is an over-expression of polycystin 1 and polycystin 2 compared with normal controls. Polycystin is expressed with variable intensity in the epithelial lining of both renal and liver cysts and is more intense in the cytoplasm than in the lateral membrane.^{5,7}

The progression of ADPKD is dependent of four groups of factors: the germline mutation (PKD1 or PKD2 gene), the modifying genes, the somatic mutations, and environment factors.¹⁰ Several mutations of the PKD1 and PKD2 genes have been reported in patients with ADPKD. A mutation in either the PKD1 and PKD2 gene that affects the interaction of polycystin 1 and polycystin 2 is believed to be responsible for the cyst formation.¹⁰ A defect in both copies of PKD1 genes is required for a defunct polycystin. The resulting defect in fluid movement and epithelial distribution will alter the normal architecture leading to cyst formation. Environmental factors the progression of cysts include endotoxins and acidifying agents, which accelerate cyst progression in mice, whereas alkalisating agents and a low-protein diet slow progression.¹⁰

To our knowledge, although the association of liver cysts with ADPKD is well established in individual patients, this is the first report indicating that the presence of liver cysts in ADPKD follows a family pattern. We suggest that our patients may carry at least two different genes for ADPKD, one of which may be associated with renal cysts alone, and the other with both renal and liver cysts. A genetic analysis is warranted in order to determine whether PKD1, PKD2 or other genes are involved in our patients.

1. Kheder A, Ben Hamida F, el Younsi F, et al. Dominant polycystic renal disease. Study of 105 cases. *Rev Med Interne* 1992; 28: 241-242.
2. Diouf B, Dia D, Ka MM, Ka EF, Diop TM. Autosomal dominant polycystosis in the hospital milieu in Dakar (Senegal). *Dakar Med* 1998; 43: 205-208.
3. Sulieman SM, Elsadig M, Fesseha S, et al. Autosomal dominant polycystic kidney disease in Sudan. *Saudi J Kidney Dis Transplant* 1996; 7: S12-S14.
4. Gabouw PA. Autosomal dominant polycystic kidney disease. *N Engl J Med* 1993; 329: 333-342.
5. Ward CJ, Turlay H, Ong ACM, et al. Polycystin, the polycystic kidney disease 1 protein, is expressed by epithelial cells in fetal, adult, and polycystic kidney. *Proc Natl Acad Sci USA* 1996; 93: 1524-1528.
6. Mochizuki T, Wu G, Hayashi T, et al. PKD2, a gene for polycystic kidney disease that encodes an integral membrane protein. *Science* 1996; 272: 1339-1342.
7. Ibraghimov-Beskrovnaya O, Dackowski WR, Foggensteiner L, et al. Polycystin: *in vitro* synthesis, *in vivo* tissue expression, and subcellular localization identify a large membrane-associated protein. *Proc Natl Acad Sci USA* 1997; 94: 6397-6402.
8. Hateboer N, van Dijk MA, Bogdanova N, et al. Comparison of phenotypes of polycystic kidney disease types 1 and 2. European PKD1-PKD2 study group. *Lancet* 1999; 353: 103-107.
9. Gabow PA, Johnson AM, Keahny WD, Manco-Johnson ML, Duley JT, Everson GT. Risk factors for the development of hepatic cysts in autosomal dominant polycystic kidney disease. *Hepatology* 1990; 11: 1033-1037.
10. Peters DJM, Breuning MH. Autosomal dominant kidney disease: modification of disease progression. *Lancet* 2001; 358: 1439-1444.

During the same period the prevalence of hypertension among inpatients was 9.46%. Chronic renal failure (CRF) was present in 7% of our patients. ADPKD represents 2% of patients with CRF. Development of liver cysts in ADPKD has been associated with female gender, pregnancy, age, and severity of renal disease.⁹