

# GIANT T WAVE INVERSION ASSOCIATED WITH STOKES-ADAMS SYNCOPE

D. JACOBSON,\* M.B., CH.B., D.C.H. (ENG.), M.R.C.P.E. AND V. SCHRIRE, M.Sc., PH.D., M.D., F.R.C.P.E., F.R.C.P., F.A.C.C.; *From the Cardiac Clinic, Department of Medicine, Groote Schuur Hospital, and the CSIR Cardiovascular-Pulmonary Research Group, Department of Medicine, University of Cape Town*

Ippolito *et al.*<sup>1</sup> first drew attention to massive T wave inversion with complete heart block, and this observation has subsequently been confirmed by others.<sup>2-9</sup>

We wish to describe a further 6 patients with giant T wave inversion and complete heart block and to relate the deep obtuse asymmetrical broad waves with the loss of consciousness, occurring during Stokes-Adams attacks. We believe that this is a specific electrocardiographic syndrome, unassociated with coronary artery disease, and that several factors are involved in its causation.

## *Incidence*

Approximately 60,000 electrocardiograms, taken during the 10-year period 1952-1961 inclusive, were available for study in the Cardiac Clinic. There were 140 patients with complete heart block and only 1 tracing, taken after a syncopal attack, showed giant T wave inversion. During the following 3 years we have encountered 5 other patients with Stokes-Adams attacks and giant T wave inversion. Ippolito *et al.*<sup>1</sup> reported 3 cases, no example being seen in the first 30,000 tracings examined, and Pfefferman *et al.*<sup>2</sup> noted 2 in 20,000 consecutive records. The increased in-

\*Since deceased.

cidence that we have noted recently, is probably more apparent than real. Now that artificial pacing has become available, interest in complete heart block has revived, so that patients with this rhythm disturbance are now more carefully studied.

## MATERIAL

Five of the 6 patients with complete heart block and Stokes-Adams attacks were females. The higher incidence in females is in keeping with the literature (Table I). The measurements (Table I) indicate the grotesque proportions of the negative T waves which are typically deep, obtuse, broad and often asymmetrical. The QT interval is uniformly markedly prolonged. The distorted complexes may well represent composite TU waves<sup>3,6</sup> and are most striking in the right precordial leads, particularly V2 and V3.

## *Case Reports*

*Case 1.* S.F., a Cape Coloured female aged 39 years, was admitted shortly after 2 Stokes-Adams attacks in which loss of sphincter control and unconsciousness of some duration occurred. On regaining consciousness she complained of severe, retrosternal, persistent heavy pain, for which she was admitted.



Fig. 1A shows the ECG record taken shortly after admission and illustrates the massive, broad inverted T waves in V2 and V3 with partial right bundle-branch block (or aberrant conduction).

TABLE I. ANALYSIS OF T WAVES IN 18 PATIENTS WITH COMPLETE HEART BLOCK, STOKES-ADAMS SYNCOPE AND GIANT T WAVE INVERSION

Present series	Sex	Age	Vent. rate	QT	QTc	T width (secs.)	T depth (secs.)
Case 1	F	39	38	0.76	0.59	0.52	15
Case 2	F	61	34	0.8	0.6	0.4	18
Case 3	F	71	18-24	0.76	0.475	0.4	30
Case 4	F	73	45	0.76	0.68	0.46	18
Case 5	F	60	44	0.76	0.68	0.4	8
Case 6	M	57	54	0.88	0.68	0.5	18
<i>Previous reports</i>							
Ippolito <sup>1</sup>	M	68	35	0.8		0.56	30
Ippolito <sup>1</sup>	F	56	38	0.64		0.36	10
Ippolito <sup>1</sup>	F	56	58	0.8		0.48	14
Pfefferman <sup>2</sup>	F	56	30	0.6		0.4	20
Pfefferman <sup>2</sup>	F	58	41	0.8		0.44	15
Szilagy <sup>3</sup>	F	70	36	0.84		0.52	17
Jedlicha <sup>4</sup>	F	68	34	0.62		0.3	7
Jedlicha <sup>4</sup>	F	39	29	0.72		0.4	20
Birke <sup>5</sup>	F	77	35	0.57		0.2	20
Holzman <sup>6</sup>	M	46	30	0.74		0.5	6
Zoob <sup>7</sup>	F	66	?	0.62		0.32	12
Soscia <sup>8</sup>	M	70	34	0.8		0.4	18

Nine years before the current illness, she had been admitted to a maternity hospital for 1 month before term, with systemic hypertension and a positive Wassermann reaction. For this she had received bed rest and penicillin. She was discharged after delivery with a normal blood pressure. Seven years later she attended the medical outpatient department, complaining of headaches and 'dizzy turns' and was found to have systemic hypertension (blood pressure 230/120 mm.Hg). The ECG showed sinus rhythm and early changes of left ventricular hypertrophy. Thereafter, she attended regularly with moderate hypertension, for which she received barbiturates only. A year later, an ECG showed complete heart block with a ventricular rate of 45, but on several subsequent examinations normal sinus rhythm was observed.

Fig. 1B is a tracing taken 3 days after the syncopal attack, showing disappearance of the massive T wave inversion and

changes, which evolved in serial tracings compatible with anterior infarction. Ischaemic heart disease in a hypertensive patient was thought to be the most likely cause of the illness. However, ischaemia consequent on a prolonged period of arrested circulation could not be excluded.

Case 2. J.K., a White female aged 71 years, was admitted to the gynaecological wards for investigation of ascites. Cardiovascular examination was negative and a blood pressure of 170/100 mm.Hg was recorded. During thiopentone induction of anaesthesia for peritoneoscopy, the blood pressure fell to 100/70 with marked slowing of the pulse. An ECG (Fig. 2A) showed complete heart block with a ventricular rate of 18/minute, a right bundle-branch block pattern and massive T wave inversion in V1-V4. Intravenous epinephrine infusion was started, with a rise of ventricular rate to 28/minute (Fig. 2B), followed by sudden restoration to sinus rhythm. Left bundle-branch block (Fig. 2C) was now present. Peritoneoscopy 3 days later confirmed the diagnosis of carcinomatous peritonitis. Subsequent ECGs showed an unchanging left bundle-branch block pattern.

Case 3. H.L., a Cape Coloured female aged 61 years, presented with effort dyspnoea. She was found to have complete heart block (Fig. 3A) and systemic hypertension. Seven months later she was admitted with repeated Stokes-Adams attacks and an ECG recorded during one of these (Fig. 3B) showed ventricular fibrillation. Two hours later the ECG showed complete heart block with a ventricular rate of 33/minute (Fig. 3C) and massive T wave inversion. This had diminished significantly by the next day (Fig. 3D). There was no evidence of ischaemic heart disease. There was a progressive decrease in the degree of the T wave inversion in subsequent tracings.

Case 4. N.v.R., a White female aged 65 years, presented with mild effort dyspnoea following an influenzal-like illness. She was found to have a blood pressure of 250/100 mm.Hg. The ECG showed partial heart block and left ventricular hypertrophy. Two and a half years later she suddenly had a Stokes-Adams attack, following which she was found to have complete heart block. Thereafter she managed reasonably well on hypotensive therapy until 2 days before admission when a series of Stokes-Adams attacks recurred. The ECG (Fig. 4A) taken within 24 hours of the onset of syncope showed massive T wave inversion, especially well shown in V2-V4. Subsequent attacks required external cardiac massage and finally settled on intravenous epinephrine drip. Five days later the

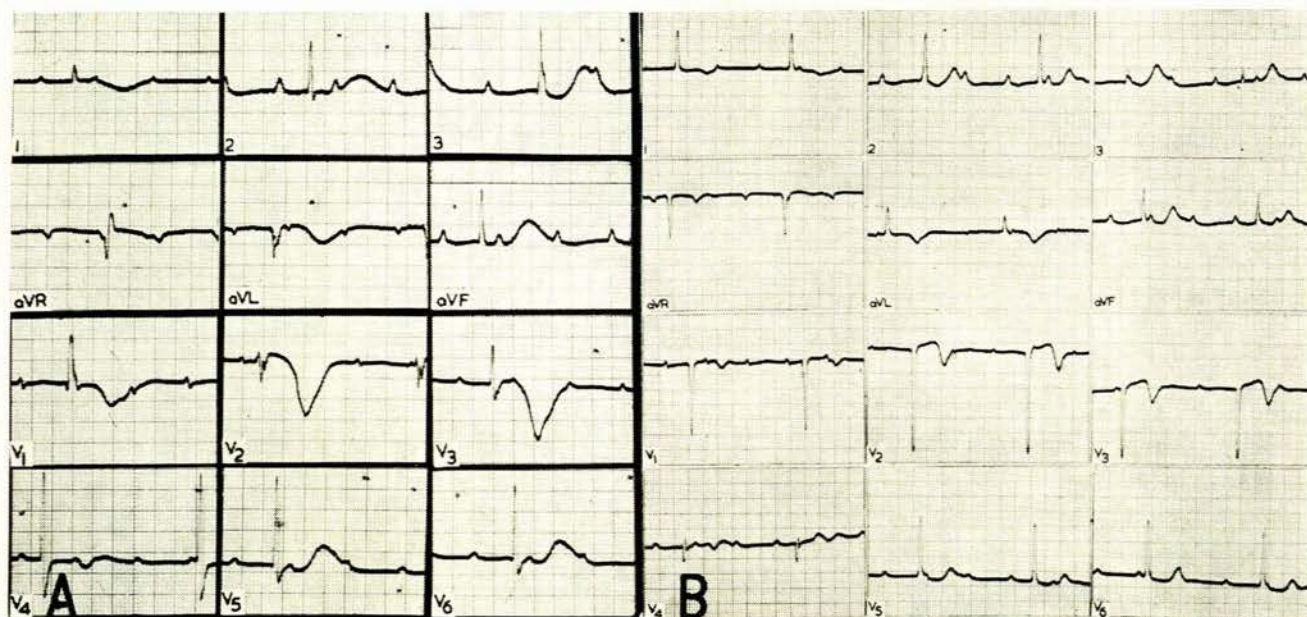


Fig. 1A. Tracing taken shortly after recovery of consciousness following a Stokes-Adams attack. Note the massive T wave inversion, complete heart block and a partial right bundle-branch block pattern. 1B. Taken 3 days later. Note the complete disappearance of the massive T wave inversion and the intraventricular conduction disturbance.



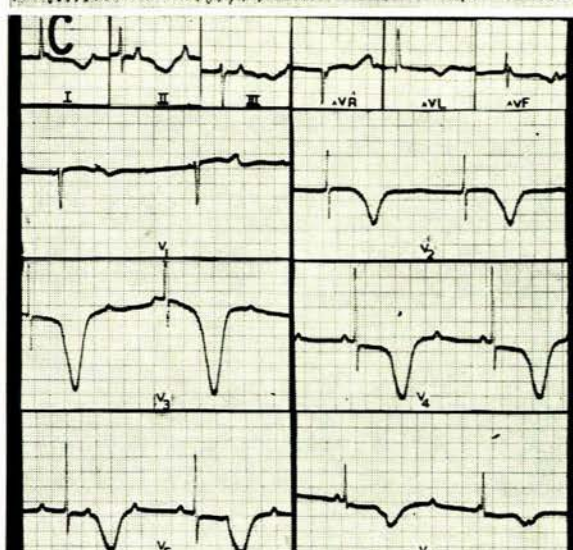
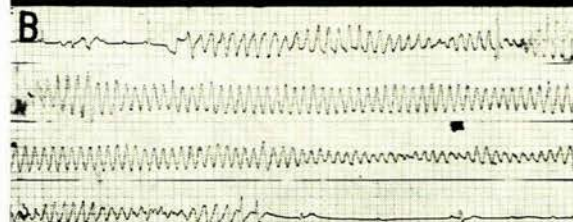
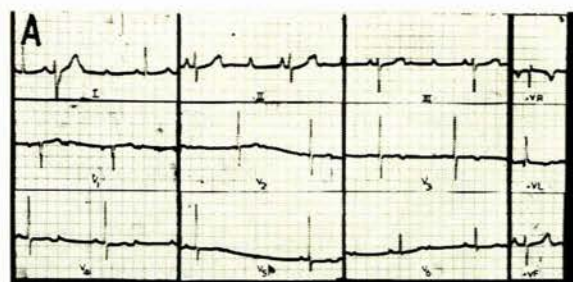
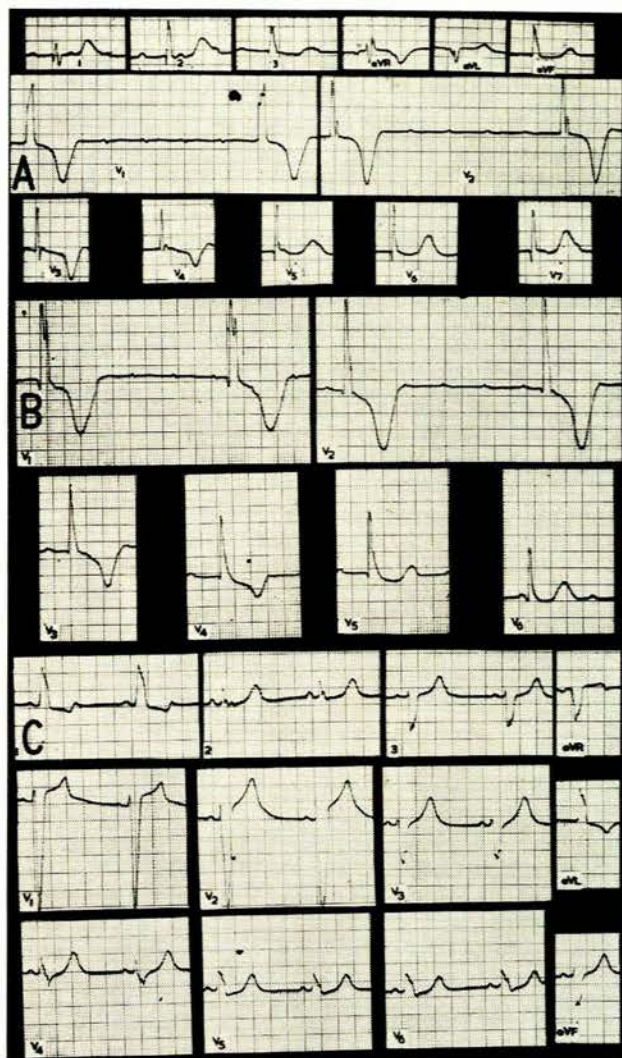


Fig. 2A. During thiopentone induction complete heart block with a ventricular rate of 18/min. developed. Note the massive T wave inversion in V1-V4 with a right bundle-branch block pattern. 2B. After intravenous adrenaline, the ventricular rate rises to 33 and soon afterwards sinus rhythm is restored with left bundle-branch block. 2C. The massive T wave inversion has disappeared.

ECG (Fig. 4B) showed paroxysms of ventricular fibrillation without loss of consciousness and disappearance of the abnormal T waves. Nine months later the syncopal attacks recurred. Temporary catheter pacing was commenced, followed by implantation of several pacemakers with complete relief of symptoms. At no time was there anything to suggest ischaemic heart disease.

**Case 5.** A White female aged 60 years was known to have had complete heart block for 7 years. For 3 years the arrhythmia had been intermittent, but with the establishment of permanent block she had several Stokes-Adams attacks of short duration. An ECG at that time confirmed the presence of complete heart block, with a ventricular rate of 40/minute. The Stokes-Adams attacks increased in severity and frequency. She was finally admitted in coma following a particu-

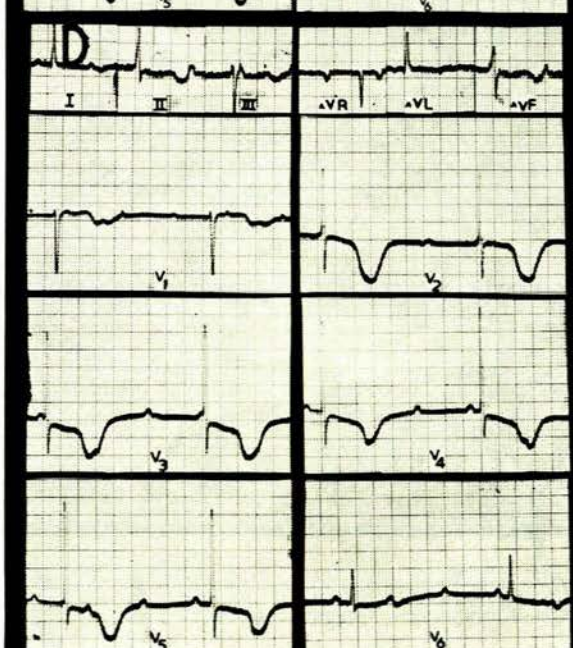


Fig. 3A. Complete heart block with normal intraventricular conduction. 3B. Stokes-Adams attack-onset and offset—due to ventricular flutter-fibrillation. 3C. Shortly after the attack, complete heart block is still present with normal intraventricular conduction and massive T wave inversion. 3D. Some improvement in T wave abnormality by the next day.



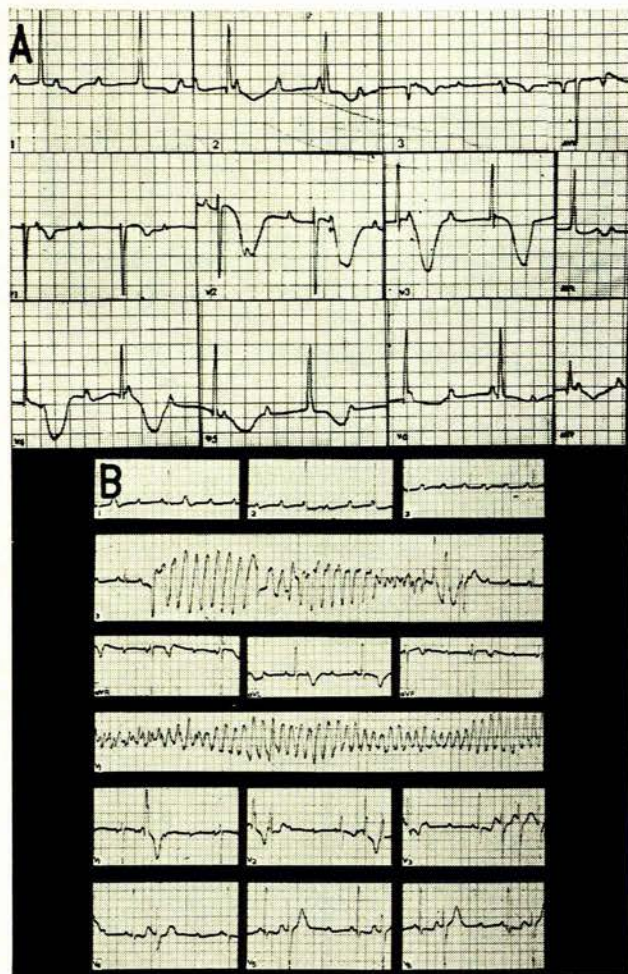


Fig. 4A. Massive T wave inversion has appeared shortly after a Stokes-Adams attack. Complete heart block with normal intraventricular conduction is present. 4B. Tracing taken 5 days later shows asymptomatic transient attacks of ventricular fibrillation. The massive T wave inversion has disappeared.

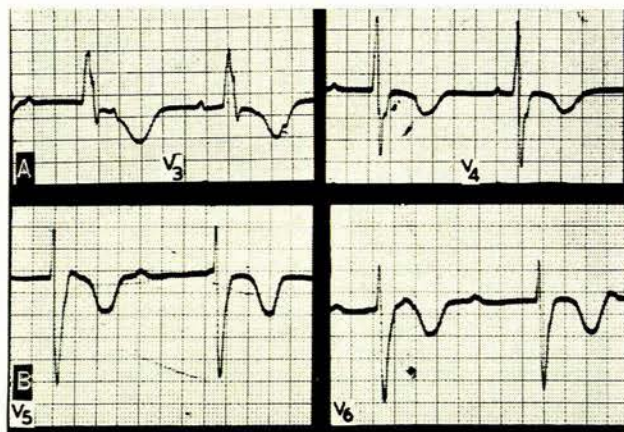


Fig. 5A. Tracing taken shortly after a Stokes-Adams attack showing complete heart block, a right bundle-branch block pattern and massive T wave inversion in V3 and V4. 5B. Tracing showing complete heart block with marked T wave inversion in V5 and V6.

larly severe attack. The ECG (Fig. 5A) showed marked T wave disturbance and complete heart block. There was no history of angina pectoris. Apart from complete heart block and a blood pressure of 240/100 mm.Hg there were no abnormalities. The patient responded well to epinephrine and ephedrine. She was finally discharged much improved.

**Case 6.** A White male aged 57 years was discovered to be mildly hypertensive at the age of 49. At 55, he had a sudden syncopal attack while driving his car and was found to have complete heart block. Thereafter he had periodic Stokes-Adams attacks, lasting for several minutes at a time and just before admission these became more severe and more frequent, requiring intracardiac epinephrine on one occasion. Examination revealed complete heart block and a blood pressure of 200/90 mm.Hg. The ECG showed complete heart block and the pattern of right bundle-branch block with massive T wave inversion (Fig. 5B). Other tracings at different times showed varying bundle-branch block and on one occasion there were small paroxysms of ventricular tachycardia. The patient's symptoms were controlled by insertion of an artificial pacemaker. At no time was there anything to suggest ischaemic heart disease.

#### Possible Additional Case

**Case 7.** R.W., a White female aged 78 years, gave a history of mild angina pectoris of 5 years' duration. She had been known to be hypertensive for many years. While walking she suddenly felt faint, dropped to the ground and lost consciousness. An ECG taken shortly thereafter showed massive T wave inversion with bradycardia. These rapidly regressed. Many tracings before and after this episode showed changes compatible with ischaemia only.

#### DISCUSSION

Massive T wave inversion following Stokes-Adams attacks, due to complete heart block, probably occurs more frequently than reports from the literature suggest. The T waves are characteristically massive, distorted and strikingly asymmetrical. They are best seen in the chest leads V2 to V4 and are unstable, though the changes often persist for several days before disappearing. In the scanty literature on this syndrome that we have been able to find, only Holzman<sup>6</sup> seems to have been aware of this unique ECG pattern as a definite entity which he labelled 'das postsynkopale bradycardie-Stoffwechsel syndrom'. Lenégré and Moreau<sup>9</sup> suggested that this T wave pattern, after a Stokes-Adams attack, indicated specifically that ventricular fibrillation and not standstill was responsible for the attack. Two well-documented cases were recorded by Birke and Ström<sup>5</sup> and Soscia *et al.*<sup>8</sup> The mechanism of syncope in 2 of our patients was observed to be ventricular fibrillation, but this must be interpreted with caution because so often both standstill and fibrillation coexist in the same patient.

There are several causes of giant T wave inversion other than complete heart block. Massive T wave inversion occurs, for example, in ischaemic heart disease,<sup>10</sup> bradycardia,<sup>11</sup> with right ventricular hypertrophy and right bundle-branch block,<sup>12</sup> with metabolic disturbances, during coronary angiography<sup>13</sup> and in cerebral disturbances.<sup>14,15</sup>

We believe that ischaemic heart disease is not the cause of massive T wave inversion seen in complete heart block. In ischaemic heart disease<sup>10</sup> the feature of the disturbance is that the T waves are narrow, sharp, symmetrical and of the so-called 'coronary' type.

None of our patients gave a history suggestive of ischaemic heart disease before the syncopal attack, and ECG changes suggestive of infarction developed in only 1



patient. This subject (case 1) had central chest pain after a prolonged attack of unconsciousness. Myocardial hypoxia may well have been the result of circulatory arrest, rather than the cause. Pain of similar nature after a syncopal attack has also been noted by Zoob and Smith,<sup>7</sup> in 4 of their female patients.

Furthermore major occlusion of the coronary arteries rarely leads to permanent heart block.<sup>23</sup> Coronary atherosclerosis is extremely common in the elderly, the age-group in whom complete heart block usually occurs. The finding at postmortem examination of 'atherosclerosis'<sup>24-26</sup> does not mean that the complete heart block was produced by coronary vascular disease. Contemporary views support the thesis that complete heart block is not due to ischaemic heart disease.<sup>27-29</sup> The condition has been attributed to a degenerative condition resulting in sclerosis of the 'fibromuscular skeleton of the heart'.<sup>30</sup>

Of special interest in this regard is the case reported by Soscia *et al.*,<sup>5</sup> of an elderly Negro male with complete heart block and Stokes-Adams attacks, due to ventricular fibrillation. At necropsy, the conduction system was destroyed by a gumma, and the coronary ostia and coronary arteries were normal. Examination of the published ECG shows the characteristic massive post-syncopal T wave changes.

Bradycardia alone is an unlikely cause of giant T wave inversion. Very marked slowing of the ventricles was present in only 1 patient (Fig. 2A). With the few exceptions described in this paper, giant T wave inversion was not observed in ECG tracings from more than 140 patients with complete heart block despite extremely slow rates in many of these subjects.

Scherf<sup>11</sup> in 1944 showed that in patients with myocardial disease, T wave inversion became more obvious after a long R-R interval. He suggested that the larger diastolic load may affect repolarization. Szilagyi and Solomon<sup>3</sup> confirmed the alteration in the T waves, from beat to beat, dependent on the diastolic filling period. It is of interest to note that their case had complete heart block and Stokes-Adams attacks with massive T wave inversion, the largest T waves being associated with the longest R-R intervals. When partial heart block was restored some days after the syncopal attack, symmetrical T wave inversion was present, with the largest wave occurring after a blocked sinus beat. It would appear that 2 factors were at work here, both the syncopal attack with complete heart block and the effect of cycle-length variation. Bradycardia may certainly play a part in the production of giant T wave inversion in complete heart block, but only under certain special circumstances. It is only rarely present, and intermittently at that, in any one patient, even though the ventricular rate remains at a uniformly and persistently slow rate.

The fact that the leads facing the right ventricle (V1-V3) usually show the maximal changes and right bundle-branch block is often present, suggests that right ventricular strain, or abnormalities in right ventricular depolarization, may be involved in the production of the giant negative T wave changes. We have noted giant T waves in severe right ventricular hypertrophy. Severe right ventricular strain cannot be the factor responsible for the giant T wave inversion after Stokes-Adams syncope, since

right bundle-branch block was not regularly present and there was certainly no evidence of pulmonary hypertension or right ventricular strain in any case.

T and U wave fusion in hypokalaemia may create the impression of QT prolongation. However, giant deformity of the T waves does not occur. In none of our cases of Stokes-Adams attacks with giant T wave changes was overt evidence of ionic disturbance present, though metabolic changes at a cellular level are almost certainly responsible for the abnormalities of repolarization. Aber and Jones<sup>31</sup> have recently drawn attention to the effects of steroids in inducing giant T wave changes in complete heart block.

We have observed deepening and expansion of the T waves soon after contrast material has been injected into a coronary artery. This is transient, occurs fairly frequently and is most unlike the changes associated naturally with coronary artery disease. According to Sones,<sup>13</sup> saline injections cause no change. Whatever the mechanism responsible for the temporary metabolic derangement of depolarization, there is quite a similarity between the changes produced during coronary angiography and those occurring after a Stokes-Adams attack. Fox *et al.*<sup>32</sup> have described a patient with W-P-W syndrome, where intravenous procaine amide produced a transient bradycardia, 2:1 block and massive negative T waves. Quinidine and procaine amide regularly deform the QT segment but rarely to this degree.

Burch *et al.*<sup>14</sup> originally drew attention to the occurrence of profound T wave changes developing during cerebral disorders. Since then a voluminous literature has developed based on clinical observations and experimental work.<sup>15-22</sup> The abnormal T waves very closely resemble those occurring after a Stokes-Adams attack. They have been encountered in patients suffering from subarachnoid haemorrhage, cerebral tumours, cerebral infarction and following neurological procedures. They can be reproduced by hypothalamic stimulation in animals and abolished or prevented by nerve or cord section.<sup>33-35</sup>

It is fair to conclude that massive T wave inversion can be produced by several causes. Symmetrical deep and narrow inversion of the T waves are usually due to ischaemic heart disease and ventricular hypertrophy, particularly that of the right ventricle. A particular type of giant T wave has been noted following Stokes-Adams attack associated with complete heart block. This usually occurs in females. The T waves are deep, blunt, broad, often bizarre with a prolonged QTc and are usually maximal in leads V2 and V3. It appears to be particularly associated with syncope due to ventricular fibrillation. A slow heart with prolongation of ventricular diastolic filling time and ventricular distension appears to be an important component. Loss of consciousness appears to play an integral part in the production of these abnormal waves. This suggests that the myocardial change is cerebral in origin. It is probably triggered off by anoxia, acting locally on the heart muscle cell, and produces a metabolic derangement which interferes with repolarization.

#### SUMMARY

1. Giant T wave inversion has been noted in 6 patients following Stokes-Adams attacks with complete heart block. The T wave inversion is massive, bizarre, broad, asymmetrical, and particularly well shown in leads V2 and V3. Females are particularly affected.