

THE SPRUE SYNDROME

DENNIS M. KRIKLER, M.B. (CAPE TOWN), M.R.C.P.

Department of Medicine, Grootte Schuur Hospital, Cape Town, and University of Cape Town

Malabsorption from the gastro-intestinal tract is usually described by its most prominent feature, steatorrhoea. The presence of excessive amounts of fat in the stools leads to the passage of bulky, offensive motions. This is not always obvious, and the patient may present with secondary effects due to the deficient absorption of vitamins, minerals and calories, etc. In some cases the steatorrhoea is due to lack of digestive secretions, as in chronic obstructive jaundice and pancreatic disease; inefficient mixing of food with enzymes is thought to account for a proportion of cases of post-gastrectomy steatorrhoea.²⁴ It is not proposed to discuss these further, but to concentrate on the enterogenous steatorrhoeas, where the fault lies in the lumen or wall of the small bowel.

The enterogenous steatorrhoeas have many features in common (see below). There are 3 sub-groups: those cases with gross irreversible changes in the bowel wall, those where abnormal anatomical factors produce stagnation, and the sprue syndrome. Among the group with irreversible pathological changes are regional enteritis, lymphoma, Whipple's disease, amyloid, and scleroderma. Active tuberculous enteritis is probably a less important cause than it was thought to be, and Franz J. Ingelfinger¹¹ stresses that steatorrhoea is rarely due to lymphatic blockage by tuberculous mesenteric adenitis.

In the group of anatomical disorders stagnation of intestinal contents facilitates the growth of an abnormal bacterial flora with an avidity for essential nutritional factors.^{24, 27} The ability of certain strains of *Str. faecalis*, when provided with bicarbonate and folic acid, to synthesize significant amounts of fats *in vitro* is of great significance in this regard.⁴⁸ The sufferer from the stagnation syndrome is thus deprived of important dietary constituents and, in addition, the remainder of the small bowel is irritated by overflowing exudates. The causes are multiple intestinal strictures,⁹ blind loops of small intestine^{14, 33} and jejunal diverticulosis.² In some, but not all, cases, strictures are due to healing of tuberculous girdle ulcers. Examples of blind loops are entero-anastomosis, gastro-jejuno-colic fistula, inadvertent gastro-ileostomy and internal fistula. Multiple jejunal diverticula are of congenital origin. Massive intestinal resection is not an important factor in producing a sprue-like picture if the remaining bowel is healthy.³³

The remaining cases of enterogenous steatorrhoea may be considered as belonging to the 'sprue syndrome'. Admittedly such a definition, which depends on exclusion rather than on positive features, is hardly satisfactory, but prevailing knowledge of the syndrome has not permitted a more precise statement. However, newer discoveries (see below) indicate

the pathological basis of the condition; future definitions will presumably be along these lines.

Methods of differentiating the steatorrhoes and of assessing the severity of the absorptive defect have previously been discussed.³⁷ The first step towards the diagnosis of the sprue syndrome lies in the identification of the steatorrhea as being of the enterogenous type. Pancreatogenous and hepatogenous steatorrhoes have specific features of their own, but the distinction is not always easy. Some of the important characteristics of the enterogenous steatorrhoes, useful in differential diagnosis, are flattened oral-glucose and vitamin-A tolerance curves, decreased absorption of xylose⁴ and, in certain types, clumping of flocculable barium with dilatation of the small bowel²² (an abnormal mucosal pattern is seen when a non-flocculating suspension is used¹). Marshak *et al.*⁴¹ found that this radiological feature is confined to cases of the sprue syndrome, Whipple's disease, and steatorrhea due to intestinal lymphoma. It is not seen in blind-loop malabsorption;²⁴ we have encountered it in a patient in whom steatorrhea resulted from a combination of massive intestinal resection and jejunal strictures due to regional enteritis.³⁸ Where it does occur, there is thought to be an excess of irritating short-chain fatty acids provoking increased intestinal secretion of mucus. Frazer *et al.*²² were able, *in vivo*, to induce radiological clumping of the usual type of barium by instilling fatty acids or mucus into the small intestine of normal people; *in vitro* they produced flocculation of the barium by adding mucus-containing secretions to it.

Within the term sprue syndrome one includes coeliac disease, tropical sprue and idiopathic steatorrhea. (In the American literature the term 'non-tropical sprue' is used to describe the latter.) For many years it was believed that these conditions were unaccompanied by specific pathological changes in the gut. Thaysen⁵² considered that the lesions which had been described in tropical sprue—desquamation and degeneration of the epithelium and atrophy of the intestinal wall—were post-mortem changes. Likewise, in its counterpart in temperate climates, idiopathic steatorrhea, it was until recently thought that no anatomical lesion was present¹⁴ and that the 'clinical picture is dependent upon a disturbance of gastro-intestinal function'.³ The recent invention of per-oral small-intestinal biopsy tubes^{17, 49, 51} provides a simple and reliable method for the study of specimens of jejunal mucosa; one can now make a definitive instead of a presumptive diagnosis of the sprue syndrome. In the following case the biopsy specimens were obtained at laparotomy.

CASE REPORT

M.S., a 30-year-old European female, entered the Groote Schuur Hospital on 5 July 1957 with a 5-year history of diarrhoea. While she passed stools almost hourly during the first year, she has subsequently averaged 5 bowel actions a day. Her stools are loose, bulky, pale and offensive; they float and often contain recognizable food residue. For this same period she has been badly troubled by abdominal distension and cramps. Occasional rectal bleeding has been related to haemorrhoids.

She first noticed brown 'freckles' on her arms, trunk and legs 15 years ago; these have steadily increased in number. In addition, during the past 3 years her face has become diffusely darker. Tetany has also been present for 3 years; she gets attacks of respiratory difficulty ('tightening of the throat') associated with carpal spasm. While she has occasionally noted small ulcers on the tip of the tongue since childhood, glossitis, with a sore red

tongue, first occurred 2½ years ago; it responded to vitamin-B therapy. During the past 2 years she has suffered from non-deforming arthritis—painful swelling of the wrists, elbows, fingers, ankles and knees. One or more joints may be affected at a time for periods of up to 2 weeks; there is no heat, redness or residual stiffness. There has been no bleeding tendency.

She tires easily but does not get short of breath. There has been considerable weight loss; at her worst she had dropped a total of 42 lb., but had regained 20 lb. by the time she was admitted to this hospital. Her appetite has been consistently good.

Past History. There was no history of diarrhoea or abdominal distension during childhood. Both ovaries had been removed for dermoid cysts, the left 6 years ago and the right 2 years later. Appendectomy was performed at the second operation.

Studies and treatment before admission

The diarrhoea was first diagnosed as being due to amoebic dysentery, but there was no response to treatment with emetine and yatrien. Later, at another hospital, it was considered to be caused by ulcerative colitis, but her condition deteriorated sharply on treatment for this. At yet another hospital she was thought to be suffering from psychogenic diarrhoea and was submitted to insulin shock therapy, with unsatisfactory results.

Earlier this year she was investigated at the Frere Hospital, East London, where the findings on physical examination and the blood counts were much the same as in this hospital (see below). Stools contained much fat in all stages of saponification; there were no ova, cysts or parasites. The Sulkowitch test on the urine was negative; a water diuresis test was abnormal (intake 1500 ml., 5-hour output 870 ml.). **Serum analyses:** Calcium 5.6 mg.%; electrolytes (mEq. per l.)—sodium 138, potassium 3.9, chloride 102; protein 5.5 g.% with normal electrophoretic pattern. **Radiography:** Barium meal—dilated small bowel, with segmentation and loss of normal mucosal pattern; chest, hands, lumbar spine, pelvis and barium enema were normal. **Treatment** with a fat-free, gluten-free diet, pancreatin, oral and parenteral calcium, vitamin D and AT10 controlled the tetany (the serum calcium rose to 6.8 mg.%) but had little other effect. There were no dramatic results from folic acid, but there was great improvement when steroids were given (ACTH, 80 units daily for 4 days, then 40 units daily for 10 days, followed by prednisone, 10 mg. b.d. for 8 days). Her stools became almost normal in amount and appearance and she felt much better. This therapy was stopped because of fluid retention, but the improvement was partially maintained up to the time of her admission to this hospital 3 weeks later.

Examination

The patient was thin but not wasted (weight 97 lb.). The mucosae were normally coloured; there was no buccal pigmentation. The fingers were not clubbed and there was no peripheral lymphadenopathy. There was moderate diffuse darkening of the face, and the trunk, arms and legs were studded with brown 'freckles' 1-3 cm. in diameter. The skin near these macules urticated easily when rubbed. Her face was not rounded and the zygomatic arches were not prominent (Fig. 1). Chvostek's and Trousseau's signs were negative. Her attitude showed moderate anxiety, introspection and emotionalism. **Cardiovascular system:** No venous distension or oedema; blood pressure 110/80 mm. Hg; heart size and sounds normal. **Alimentary system:** the mouth and fauces were normal. Gaseous distension of the abdomen

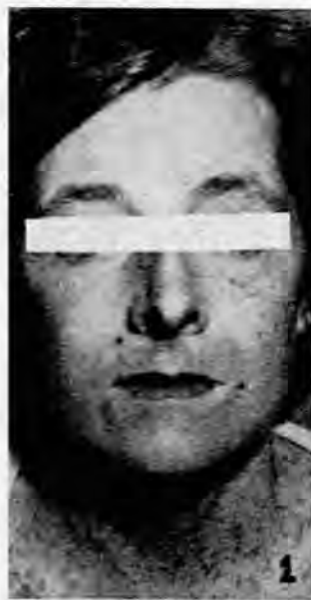

Fig. 1.

was marked. The liver was firm and smooth and its lower edge was felt 3 finger-breadths beneath the right costal margin. The spleen was soft; its tip was easily palpable. Rectal examination was negative save for the presence of small haemorrhoids. The respiratory and nervous systems were intact. The joints were unremarkable. The urine was normal. Blood: Hb 13 g.%, VCP 40%, ESR 7 mm. in the first hour (Westergren), WBC 5000 per c.mm. with 58% neutrophils and 42% lymphocytes. A peripheral blood smear was normochromic and normocytic, and platelets were abundant.

Studies at this Hospital

Blood urea 32 mg.%. Serum cholesterol 166 mg.%, albumin 4.6 and globulin 1.2 g.%; thymol turbidity 1, zinc turbidity 7; van den Bergh reaction negative and bilirubin 0.5 mg.%; calcium 9.8 and inorganic phosphorus 2.9 mg.%. Serum electrolytes (mEq. per l.): Sodium 142, potassium 2.7, chloride 105. Prothrombin index 86. Blood group O, Rh+. Gastric analysis: No free acid with caffeine stimulus; augmented histamine test—low level of secretion (0.46 mEq. free HCl an hour = 8 mEq. per l.). Urinary calcium excretion 87 mg./24 hours; 17-ketosteroid output 4.1 mg.%; urinary 5-HIAA normal (5 g. per ml. = 9.9 mg. per g. creatinine).

Benzidine tests on the stool were negative for occult blood. Sigmoidoscopy was normal. A 3-day fat balance (intake 70 g. per day) showed 85.5% absorption (normal 95-100%). An oral glucose tolerance test revealed a flat curve (fasting 92 mg.%; ½-hour 98; 1 hour 103; 1½ hours 103; 2 hours 92). Xylose absorption: 3.7 g. passed in the urine during the 5 hours after the oral administration of 25 g. of d-xylose (see below).

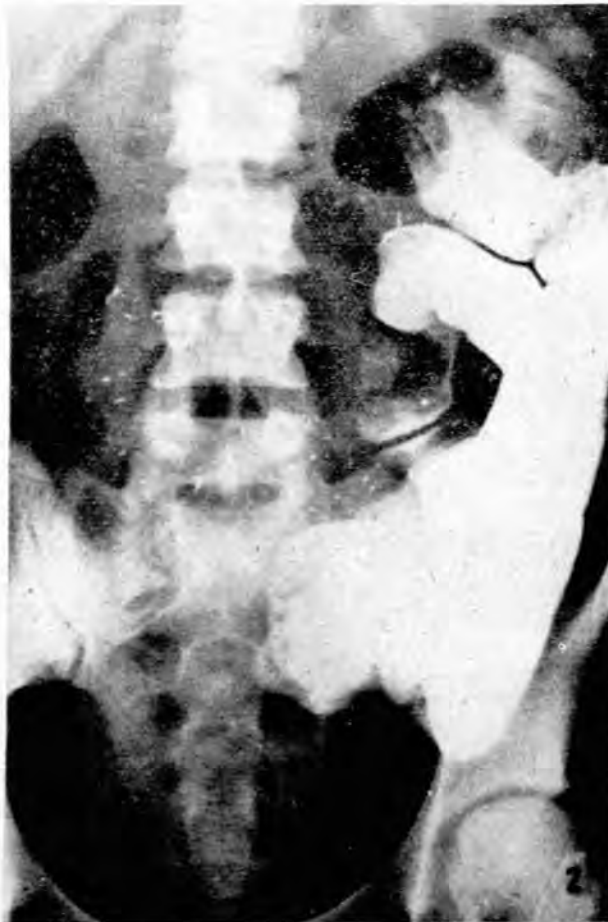

Fig. 2. Barium-meal X-ray.

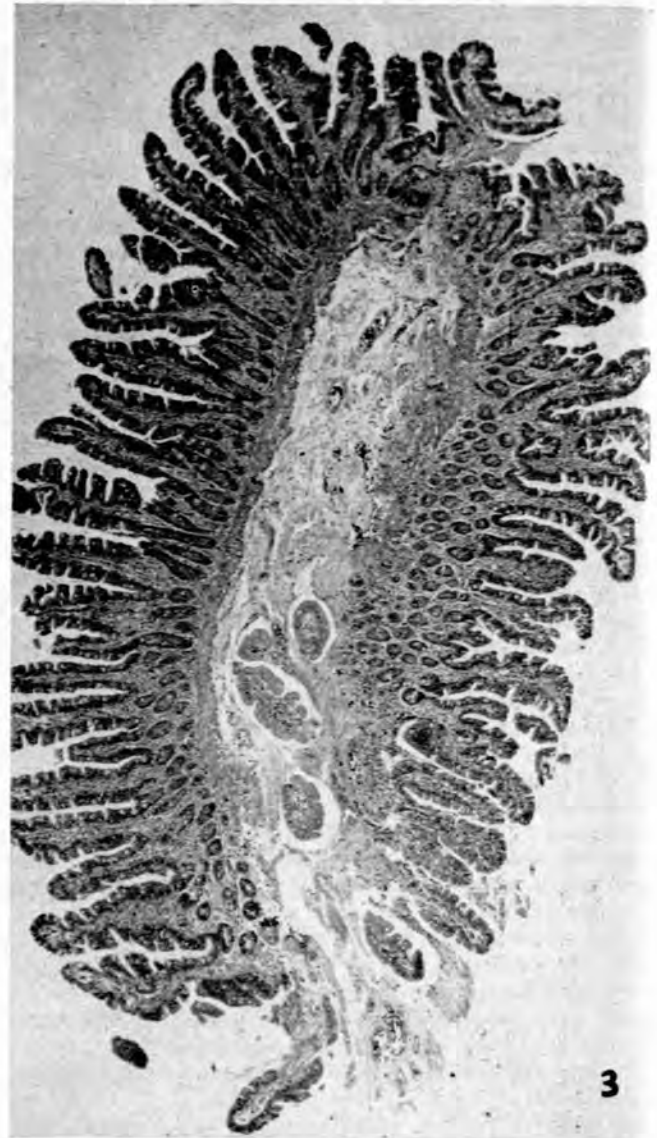


Fig. 3. Complete jejunal biopsy specimen taken from a normal patient with the Shiner tube (H. and E., $\times 45$). Note the thin frond-like villi and the long narrow glands of Lieberkuhn; goblet cells are scanty. By courtesy of Dr. M. Shiner.

Barium-meal examination with a non-flocculating suspension: A normal small-bowel mucosal pattern could not be seen; there was dilatation of the jejunum and ileum and marked delay in transit (Fig. 2). Two electrocardiographs were normal. Skin biopsy: There was much melanin in the basal layer of the epidermis and numbers of mast cells were seen in the corium (Dr. G. Selzer). A needle biopsy of the liver was normal; the Kupffer cells did not take up the periodic-acid-Schiff stain (Dr. G. Selzer).

Course

A high-protein, low-fat, moderate-carbohydrate diet was given, with vitamin, calcium and potassium supplements. After a week the serum potassium had risen to 4.6 mEq. per l.

It was felt that the only way to establish the diagnosis was to perform a laparotomy; this took place on 1 August 1957 (Dr. D. J. du Plessis). The small bowel was very flabby and atonic. There were large lymph nodes along the whole length of the mesentery. Lacteals were not visible in the bowel or mesentery.

and there were no adhesions, obstructions or fistulae. The pancreas was normal. The spleen was slightly enlarged. Appendectomy and bilateral ovariectomy had previously been performed, but the pelvis was quite free of adhesions. Biopsy specimens were taken from upper jejunum and lower ileum and of lymph nodes near either site. These were considered (Dr. C. J. Uys) as being compatible with the appearances described by Shiner in non-tropical sprue.⁵⁰ The features were 'clubbing' of the villi and a diffuse mucosal infiltrate of eosinophils, histiocytes and lymphocytes. The periodic-acid-Schiff stain was negative. Fig. 3 shows a complete jejunal biopsy specimen taken from a normal patient (Shiner). Fig. 4 is from the jejunal biopsy taken from our patient M.S. One

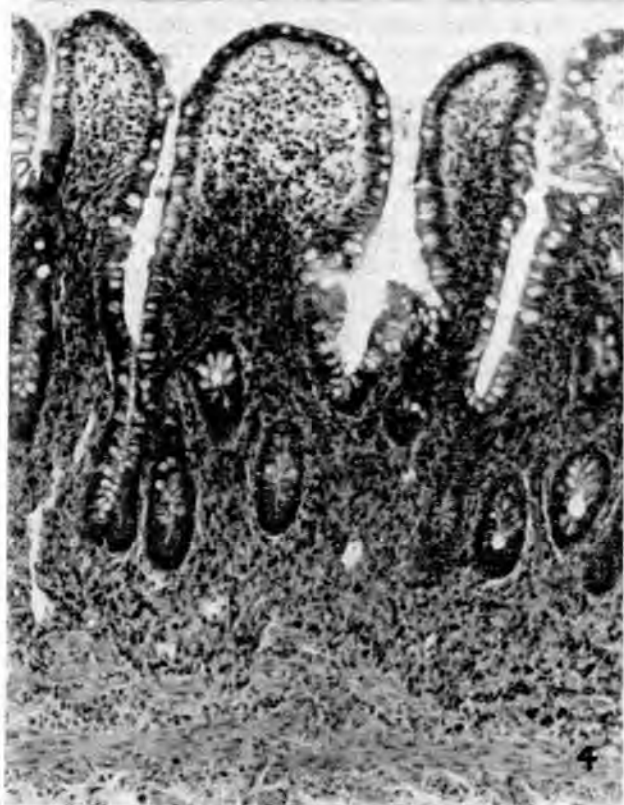


Fig. 4. Jejunal biopsy from M.S. (H. and E., $\times 180$). See text.

types of pigmentation—'freckling' for 15 years and diffuse facial darkening for 5 years. Dr. Jean Walker felt that the former had the clinical and histological features of urticaria pigmentosa (disseminate pigmented mastocytosis). The possible link between the mastocytoses and metastatic carcinoid syndrome have recently been emphasized by Marshall *et al.*,⁴² who reported 2 cases of cutaneous flushing associated with mastocytoma; both argentaffin and mast cells secrete 5-hydroxy-tryptamine. Because Warthin¹² and Waldmann *et al.*⁵⁵ noted a sprue-like picture in argentaffinomatosis, the urinary 5-hydroxy-indole-acetic acid was measured in this patient, but was normal. There were no other findings to suggest the metastatic carcinoid syndrome, and liver biopsy was negative; several cases of this condition have been studied at the Groote Schuur Hospital.³⁹

The major clinical features in this patient seemed to indicate a triad of enterogenous steatorrhoea, diffuse facial pigmentation, and arthritis, and a tentative diagnosis of Whipple's disease was made. Approximately 60 cases of this interesting disorder have been described.^{7, 8, 47} It has a characteristic histology³⁵—the tunica propria of the small bowel and the mesenteric lymph nodes are filled with macrophages which contain a material that takes up the periodic-acid-Schiff stain but not Sudan-black. R. B. Cohen¹² stresses that there is not enough histochemical evidence to group Whipple's disease with the collagenoses. He considers that, while the material in the macrophages is probably in part a carbohydrate, the presence of a lipoid or lipoprotein component cannot be excluded. Of considerable practical interest is the discovery by Korsch (quoted by Calahane¹⁰) that the lesions can occur in extra-abdominal lymph nodes and the demonstration, in 3 cases, of Schiff-positive macrophages in these sites.⁴⁶ While this is of great diagnostic value, in the case discussed by T. A. Warthin¹² a peripheral-node biopsy was negative (the diagnosis was confirmed by jejunal tube biopsy). The present patient did not have palpable lymph nodes. In the hope that the Kupffer cells, being macrophages, might contain Schiff-positive material, liver biopsy was performed, but was negative.

Many workers stress the importance of histological proof of the diagnosis of Whipple's disease—by laparotomy if necessary^{6, 12, 35}—in view of the favourable effect of steroids on the clinical manifestations of the illness. Interestingly enough, the lesions persist in spite of clinical improvement.³⁵

Another reason for performing laparotomy was the need to exclude a surgically correctable cause;²³ she had previously had abdominal operations and the remote possibility of intestinal strictures or a blind loop had to be considered. At laparotomy the small intestine was found to be flabby and there were many large lymph nodes in the mesentery. This seemed to confirm the suggestion of Whipple's disease, yet histologically the nodes showed only reactive changes. Himes and Adlersberg,²⁹ in their report on 11 autopsy cases of sprue, found mesenteric-node enlargement in 5 cases, with chronic lymphadenitis in 3 of these. Clinically, too, peripheral-node enlargement is not uncommon in the sprue syndrome; Bossak *et al.*⁶ found this in 11.7% of their 94 cases. The same percentage of patients showed skin pigmentation; Himes and Adlersberg²⁹ found an excess of melanin in 3 out of 5 cases examined at autopsy.

DISCUSSION

The type of steatorrhoea was obviously enterogenous; all the features of that group were present. More precise diagnosis rested on the interpretation of other associated clinical, biochemical and pathological findings. The most obvious of these were the skin changes; the case showed two different

PATHOLOGY

The histological appearances recently described in cases of the sprue syndrome⁵⁰ appear to indicate an atrophic process; further studies are required to determine their specificity. The changes consist of: Reduction in the size of the villi (ranging from 'clubbing' to almost complete flattening); epithelial cellular degeneration; oedema, congestion and inflammatory cell infiltration of the villous stroma; variable increase in goblet cells; and a tendency towards gaping of the crypts and distension of the glands of Lieberkuhn. These appearances were well seen in the present case (Fig. 4) and make a striking contrast to the normal structure of the jejunum (Fig. 3). Doniach and Shiner²⁰ very tentatively suggest that the malabsorption might be due to the tremendous loss of villous surface epithelium.

It does seem significant that there is good correlation between these signs and the presence of an abnormal radiological pattern in the small intestine. Shiner⁵⁰ performed biopsies on 17 patients with steatorrhoea. In 4 of these (pancreatic disease 1, post-gastrectomy 2, chylous obstruction 1) histology was normal and there was no barium clumping on X-ray. One patient (suffering either from idiopathic or post-gastrectomy steatorrhoea) had an equivocal biopsy and showed clumping on barium meal. In the remaining 12 cases there were varying degrees of atrophy and clumping: 10 suffered from idiopathic steatorrhoea, 1 from tropical sprue and 1 from either idiopathic steatorrhoea or intestinal tuberculosis.

Paulley⁴⁴ found this atrophic jejunitis in 3 cases of idiopathic steatorrhoea from whom biopsies were taken at laparotomy. Himes and Adlersberg²⁹ reported similar intestinal changes in autopsy cases. In steatorrhoea following subtotal gastrectomy biopsy studies have failed to reveal consistent changes in the jejunal mucosa.^{49, 50}

Of the 11 autopsy cases of sprue recorded by Himes and Adlersberg 4 had pancreatic fibrosis.²⁹ Volwiler⁵⁴ considers that this is due to protein lack; it is probably secondary to malnutrition and analogous to the biochemical and pathological findings in a case of massive intestinal resection^{54, 40} (and perhaps in a patient with intestinal lymphoma at first thought to be suffering from idiopathic steatorrhoea^{31, 32}).

In view of recent reports of the association of steatorrhoea with hyperparathyroidism¹⁵, and hypoparathyroidism³⁰, it is of interest that Himes and Adlersberg found the parathyroids to be histologically normal in 4 cases and to show connective tissue proliferation in 1; the glands were not examined in the remaining 6 cases.²⁹ Only in their single case that had received prolonged steroid therapy was there thinning of the adrenal cortex.

CLINICAL FEATURES

While there are no obvious pathological differences in the intestinal lesions of tropical and non-tropical sprue, there are important clinical distinctions. Whether these imply a different pathogenesis is uncertain. Bossak *et al.*⁶ separated their 27 Puerto Rican patients from 67 cases from the continental United States; like Perez-Santiago and Butterworth⁴⁵ they found a higher incidence of megaloblastic anaemia and glossitis in tropical sprue. In non-tropical cases clubbing of the fingers, hypocalcaemic manifestations and a bleeding tendency are commoner. The latter is due to hypoprothrombinaemia resulting from under-absorption of vitamin

K.³⁸ The present patient did not have a bleeding tendency; her prothrombin index was 86 (after steroid therapy).

While splenomegaly is more likely to be found in tropical sprue⁶ it does occur in non-tropical cases, and was present in the patient under discussion. The reason for its occurrence is not known; presumably the excess in the tropical group is partly due to locally endemic disease e.g. schistosomiasis in Puerto Rico. Glossitis was not noted at the time of admission but does, of course, occur in both types; in fact, the name of the syndrome is derived from *spruw*, the Dutch word for aphthous stomatitis.

Intermittent abdominal cramps and considerable bloating were troublesome in the present case. The possibility of partial intestinal obstruction was excluded at operation. Several cases of sprue have been recorded in which gaseous distension of the gut was so severe as to necessitate emergency diagnostic laparotomy;³⁵ in some of these volvulus of the colon had actually developed and led to intestinal obstruction.^{15, 25}

The psychological status of sprue patients has been discussed by Cooke *et al.*¹⁵ unlike previous workers they found a low incidence of symptoms of anxiety and depression. They stress the relative psychological normality of their cases as compared with sufferers from ulcerative colitis. The symptoms of psychological disturbance present in the patient under consideration were, in the opinion of the consultant psychiatrist, explicable on other grounds.

Her arthritis is not explained by the diagnosis of non-tropical sprue, and its occurrence is presumably coincidental. Her face (Fig. 1) has not the rounded configuration with prominent zygomatic arches reported in females with idiopathic steatorrhoea—it actually looks more triangular, as it is said to be in males with this condition.³

Benson *et al.*⁴ consider that the d-xylose absorption test is one of the most valuable investigations in the differentiation of the steatorrhoeas; they found it much more reliable than the glucose tolerance test. Decreased absorption is found only in the enterogenous steatorrhoeas. The subject drinks 25 g. d-xylose, a pentose that has little, if any, metabolic activity, and all urine passed during the following 5 hours is collected and analysed. Normally 6.5 ± 1.2 g. of xylose is excreted; their untreated sprue patients passed 1.3 ± 0.7 g., and cases in remission 3.0 ± 1.2 g. The excretion of 3.7 g. in the present case is in keeping with the state of partial clinical remission.

Recently a sprue-like syndrome has been described in association with agammaglobulinaemia;^{5, 16} although her serum globulin was low (1.2 g.%) the electrophoretic pattern was normal.

AETIOLOGICAL ASPECTS

W. F. Dicke (quoted by Frazer²¹) showed that coeliac disease is due to sensitivity to the gluten fraction of wheat and rye. C. M. Anderson *et al.* (quoted by Frazer²¹) have described adult cases of gluten-induced enteropathy, and Di Sant'Agnes¹⁹ indicated that cases of coeliac disease may subsequently present with absorptive defects in adult life. However, not all non-tropical sprue is due to gluten-induced enteropathy, even though the latter is an important cause of enterogenous steatorrhoea.²¹

Although bacterial or other infection has been advanced as the cause of tropical sprue, final proof is lacking; the

implications of the discovery of a fat-forming enterococcus⁴⁵ remain to be assessed. The demonstration that absorption in the stagnation syndrome (jejunal diverticulosis,² blind loops²⁶) is improved by bowel sterilization with chlortetracycline (but, strangely enough, not with neomycin) may well be significant in this regard.

Hawkins²⁸ has reported a case of tubular jejunal stenosis, resembling Crohn's disease, following on mesenteric arterial occlusion, and Klass³⁶ has had several cases of malabsorption after mesenteric embolectomy. Three such cases have recently been studied at the Massachusetts General Hospital.⁵³ These developments may necessitate review of the possible aetiology in some cases at present labelled 'idiopathic steatorrhoea'; Klass³⁶ suggests that elderly people with abdominal colic and malabsorption may be suffering from 'mesenteric strokes'.

The importance of fibrocystic disease of the pancreas as a cause of steatorrhoea in childhood is now well recognized.

TREATMENT

Colcher and Adlersberg¹³ stress the importance of diet (high-protein, low-fat, low-starch), vitamins and haematinics, and, in severe or non-responsive cases, steroids. Judging by her clinical and biochemical improvement the present patient had undergone a partial steroid-induced remission at the time of her entry to Groote Schuur Hospital. That this is symptomatic control rather than cure is indicated by Shiner's finding that 4 cases of the sprue syndrome maintained in good health on steroids still had gross pathological changes on biopsy.⁵⁰ Volwiler⁵⁴ considers that oral maintenance therapy with small doses of steroids (e.g. 5-10 mg. of prednisolone daily) is useful and adequate. In his experience relapse commonly occurred 2-3 weeks after stopping treatment. It is not known how steroids produce clinical remission in Whipple's disease and the sprue syndrome; the fact that histological changes persist suggests that there is a non-specific potentiation of fat absorption.

Our patient had not responded to gluten exclusion, but this may not have received an adequate trial; Frazer²¹ feels that adult cases of gluten-induced enteropathy may not improve until after 6 months on the restricted diet. However, there is usually a history suggestive of coeliac disease during childhood; as this was lacking here, and steroids had helped her, it was decided not to try the gluten-free diet again. Children with coeliac disease respond rapidly and well to permanent avoidance of gluten.

Adult cases of tropical sprue tend to respond to folic acid; should this fail, broad-spectrum antibiotics may be tried. Antibacterial therapy is not recommended in non-tropical sprue.²¹

Symptomatic treatment demands the oral and parenteral replacement of vitamins and minerals. The absorption of oral supplements of calcium can be aided by concomitant parenteral administration of large doses of vitamin D.²⁷ Folic acid is the most important haematinic supplement.

SUMMARY

A biopsy-proven case of idiopathic steatorrhoea (non-tropical sprue) is presented. Advances in the aetiology, pathology, diagnosis and management of the sprue syndrome are outlined. It is certain that better understanding of this complicated group of illnesses will follow the recent demonstration

of histological changes in the small intestine. While the causes are not all known, the mechanisms of the malabsorption are becoming better understood, and symptomatic control can be expected in a high proportion of cases. Laparotomy may be needed to establish the diagnosis, particularly where the possibility exists that the steatorrhoea may be due to the anatomical 'stagnation syndrome' and thus be amenable to surgical cure.

I wish to thank Dr. Louis Mirvish and Dr. Velva Schrire for permission to report this case and for advice about its presentation. The patient was referred by Dr. L. Sunn. Mr. B. Todt prepared Figs. 1 and 2, and the Department of Pathology, University of Cape Town, provided Fig. 4. I am most grateful to Dr. Margot Shiner, of the Gastro-enterology Department, Central Middlesex Hospital, London, for allowing me to use Fig. 3. Prof. G. C. Linder is thanked for the many investigations performed in his department, especially for the 5-HIAA and d-xylose estimations.

REFERENCES

1. Ardran, G. M., French, J. M. and Mucklow, M. B. (1950): *Brit. J. Radiol.*, **23**, 697.
2. Badenoch, J., Bedford, P. D. and Evans, J. R. (1955): *Quart. J. Med.*, **24**, 321.
3. Bennett, T. I., Hunter, D. and Vaughan, J. M. (1932): *Ibid.*, **1**, 603.
4. Benson, J. A., Jr., Culver, P. J., Ragland, S., Jones, C. M., Drummey, G. D. and Bougas, E. (1957): *New Eng. J. Med.*, **256**, 335.
5. Beres, P., Wenger, J. and Kirsner, J. B. (1957): *Gastroenterology*, **32**, 1.
6. Bossak, E. T., Wang, C. I. and Adlersberg, D. (1957): *J. Mt. Sinai Hosp.*, **24**, 286.
7. Editorial (1955): *Brit. Med. J.*, **2**, 191.
8. Editorial (1957): *Ibid.*, **1**, 998.
9. Brock, J. F. (1939): *Lancet*, **1**, 72.
10. Calahane, S. F. (1957): *Brit. Med. J.*, **1**, 1421.
11. Case Records of the Massachusetts General Hospital (1957): *New Eng. J. Med.*, **256**, 359.
12. *Idem* (1957): *New Eng. J. Med.*, **256**, 612.
13. Colcher, H. and Adlersberg, D. (1957): *J. Mt. Sinai Hosp.*, **24**, 380.
14. Cooke, W. T., in F. Avery Jones (1951): *Modern Trends in Gastroenterology*. London: Butterworth.
15. Cooke, W. T., Peeney, A. L. P. and Hawkins, C. F. (1953): *Quart. J. Med.*, **22**, 59.
16. Cooke, W. T., Weiner, W. and Shinton, N. K. (1957): *Brit. Med. J.*, **1**, 1151.
17. Crosby, W. H. and Kugler, H. W. (1957): *Amer. J. Digest. Dis.*, **2**, 236.
18. Davies, D. R., Dent, C. E. and Willcox, A. (1956): *Brit. Med. J.*, **2**, 1133.
19. Di Sant'Agnes, P. A. (1953): *Pediatrics*, **11**, 224.
20. Doniach, I. and Shiner, M. (1957): *Gastroenterology*, **33**, 71.
21. Frazer, A. C. (1955): *Brit. Med. J.*, **2**, 805.
22. Frazer, A. C., French, J. M. and Thompson, M. D. (1949): *Brit. J. Radiol.*, **22**, 123.
23. Friedlander, P. H. and Gorvy, V. (1955): *Brit. Med. J.*, **2**, 809.
24. Gardner, F. H. (1957): *Amer. J. Digest. Dis.*, **2**, 175.
25. Glazer, I. and Adlersberg, D. (1957): *J. Mt. Sinai Hosp.*, **24**, 159.
26. Halstead, J. A., Lewis, P. M. and Gaster, M. (1956): *Amer. J. Med.*, **20**, 42.
27. Hartley, J. (1957): *J. Mt. Sinai Hosp.*, **24**, 346.
28. Hawkins, C. F. (1957): *Lancet*, **2**, 121.
29. Himes, H. W. and Adlersberg, D. (1957): *J. Mt. Sinai Hosp.*, **24**, 251.
30. Jackson, W. P. U. (1957): *Lancet*, **1**, 1086.
31. *Idem* (1957): Personal communication.
32. Jackson, W. P. U., Hoffenberg, R., Linder, G. C. and Irwin, L. (1956): *J. Clin. Endocr.*, **16**, 1043.
33. Jackson, W. P. U. and Linder, G. C. (1951): *S. Afr. J. Clin. Sci.*, **2**, 205.
34. Jackson, W. P. U., Linder, G. C. and Berman, S. (1951): *S. Afr. J. Clin. Sci.*, **2**, 70.

35. Jones, C. M., Benson, J. A., Jr. and Roque, A. L. (1953): *New Engl. J. Med.*, **248**, 665.
36. Klass, A. A. (1957): *Brit. Med. J.*, **2**, 215.
37. Krikler, D. M. (1957): *Cent. Afr. J. Med.*, in the press.
38. *Idem* (1958): *S. Afr. Med. J.* in the press.
39. Krikler, D. M., Lackner, H., Sealy, R. and Timme, A. H. (1957): to be published.
40. Linder, A. M., Jackson, W. P. U. and Linder, G. C. (1953): *S. Afr. J. Clin. Sci.*, **4**, 1.
41. Marshak, R. H., Wolff, B. S. and Eliasoph, J. (1957): *J. Mt. Sinai Hosp.*, **24**, 362.
42. Marshall, J., Walker, J., Lurie, H. I., Hansen, J. D. L. and Mackenzie, D. (1957): *S. Afr. Med. J.*, **31**, 867.
43. McLean Baird, I. and Dodge, O. G. (1957): *Quart. J. Med.*, **26**, 393.
44. Paulley, J. W. (1954): *Brit. Med. J.*, **2**, 1318.
45. Perez-Santiago, E. and Butterworth, C. E., Jr. (1957): *Amer. J. Digest. Dis.*, **2**, 225.
46. Puite, R. H. and Tesluk, H. (1955): *Amer. J. Med.*, **19**, 383.
47. Radding, J. and Fiese, M. J. (1954): *Ann. Intern. Med.*, **41**, 1066.
48. Sammons, H. G., Vaughn, D. J. and Frazer, A. C. (1956): *Nature*, **177**, 237.
49. Shiner, M. (1956): *Lancet*, **1**, 85.
50. *Idem* (1957): *J. Mt. Sinai Hosp.*, **24**, 273.
51. *Idem* (1957): *Gastroenterology*, **33**, 64.
52. Thaysen, T. E. H. (1931): *Trans. Roy. Soc. Trop. Med. Hyg.*, **24**, 539.
53. Thurlbeck, W. M. (1957): Personal communication.
54. Volwiler, W. (1957): *Amer. J. Med.*, **23**, 250.
55. Waldmann, E. B., Martin, W. J. and Ferris, D. O. (1955): *Proc. Mayo Clin.*, **30**, 127.
56. Wang, C. I. and Bossak, E. T. (1957): *J. Mt. Sinai Hosp.*, **24**, 317.
57. Witts, L. J. (1956): *Anaemia and the Alimentary Tract*. Edinburgh: Royal College of Physicians.