

# Percutaneous endoscopic gastrostomy

## Indications, technique and complications at Groote Schuur Hospital

J. ZAK, D. A. JOHNSTON, K. A. NEWTON, J. P. WRIGHT, I. N. MARKS

### Summary

**Percutaneous endoscopic gastrostomy (PEG) is a relatively new technique in South Africa. It is useful in the management of patients with neurological and oropharyngeal disorders in whom long-term feeding is necessary. The PEGs inserted in patients at Groote Schuur Hospital between June 1986 and March 1990 as part of an on-going study to evaluate this procedure are reported.**

*S Afr Med J* 1991; 79: 725-726.

Percutaneous endoscopic gastrostomy (PEG) was first described by Gauderer *et al.*<sup>1</sup> in 1980. Since then it has become the procedure of choice in providing nutrition for patients with functional gastro-intestinal tracts who would otherwise require nasogastric intubation. PEG may also be used for gastro-intestinal decompression and internalisation of biliary drainage.

The procedure is relatively new in South Africa, the first PEG being performed at Groote Schuur Hospital in 1986. Initial experience, and the resulting changes introduced, are reported.

### Patients and methods

Twenty-two of 25 patients referred for possible placement of a PEG were considered suitable candidates for the procedure. All 22 met the following criteria: (i) a functional gastro-intestinal tract with no anatomical impediment to gastrostomy or PEG insertion; and (ii) a supportive family or nursing home/hospital milieu.

PEGs were inserted using the method of Gauderer *et al.*<sup>1</sup> with a few minor modifications. All PEGs were inserted in patients in the Gastro-Intestinal Unit or in the Intensive Care Unit (ICU). The Caluso PEG was used (Superior Biosystems Inc., Cumberland, R.I., USA). It should be noted that the procedure may be performed using a 12F De Pezzer catheter and a 14 gauge Medican cannula together with a length of surgical black silk at a much lower cost; however, it must be noted that the De Pezzer catheter will not last as long as the standard PEG.

PEG insertion was performed by 2 doctors and 2 trained nurses. An upper gastro-intestinal endoscopy was performed under sedation by the first doctor to exclude any disease, and to facilitate the procedure. The abdomen was prepared and a sterile technique was employed for PEG insertion. The stomach

was insufflated with air to allow the anterior wall of the stomach to oppose the abdominal wall, and the anterior wall illuminated. An external site was chosen by the second doctor, and the area trans-illuminated by the endoscopist. A slight adjustment in the site was sometimes necessary. Inability to trans-illuminate through to the anterior abdominal wall was an absolute contraindication to the procedure. Local anaesthetic was infiltrated and a 6 mm incision made. A Seldinger catheter was inserted through this incision into the stomach and visualized by the endoscopist. A guidewire was passed via the catheter into the stomach, grasped with biopsy forceps and pulled out through the mouth. The guidewire was attached to the loop at the end of the PEG. The latter was lubricated and pulled through the mouth to the stomach (Fig. 1) and out via the catheter tract until the internal bolster was flush against the anterior wall of the stomach. The external bolster was then slipped over the PEG and placed flush with the skin. A silk suture was tied around the bolster to prevent slippage of the PEG. The procedural part of the PEG was then cut off. No sutures were required to secure the bolster to the skin. Patients were usually started on feeds after 12 - 24 hours.

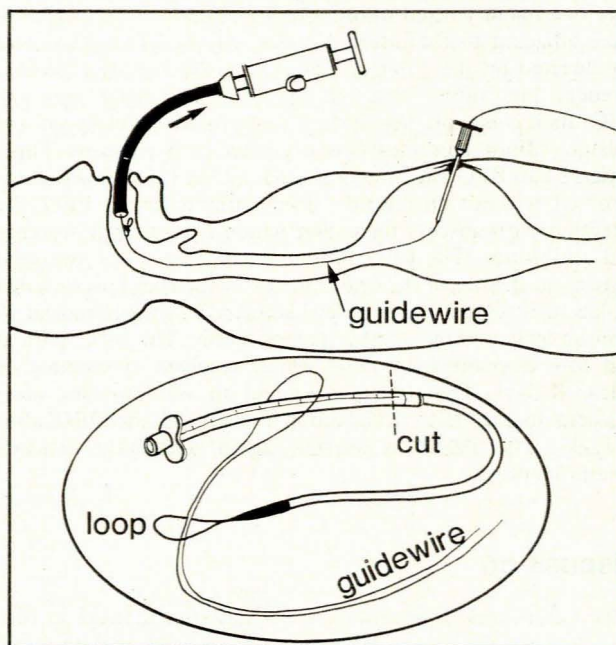


Fig. 1. Diagram of the PEG procedure in progress.

Gastro-intestinal Clinic, Department of Medicine, University of Cape Town and Groote Schuur Hospital, Cape Town

J. ZAK III, M.D. (ROSS)

D. A. JOHNSTON, M.R.C.P.

K. A. NEWTON, F.C.P. (S.A.)

J. P. WRIGHT, F.R.C.P.

I. N. MARKS, F.R.C.P., F.A.C.G.

Accepted 22 Nov 1990.

### Results

PEG insertion was successful in 21 of the 22 patients (15 men; age range 21 - 88 years, median 60 years) considered suitable for the procedure. The 1 failure resulted from inability to pass the catheter into the stomach due to gross obesity. The majority of insertions were carried out during the past 2 years. The majority of patients (19; 86,3%) had neurological indica-



tions, including 2 with malignant disease (Table I). Five of the 7 patients under 40 years old were involved in trauma/neurosurgery. Of the remaining 3 patients, 2 had non-neurological malignancies and 1 had swallowing problems as a result of severe mental retardation. Twenty-one patients (95,4%) had a PEG inserted for feeding purposes. One PEG was placed for gastric decompression in a patient with ovarian carcinoma.

TABLE I. INDICATIONS

<b>Neurological</b>
Motor vehicle accident
Motor neuron disease
Cerebral vascular accident
Lateral medullary syndrome
Huntington's chorea
Post-pneumococcal meningitis
Meningioma
Recurrent posterior fossa ependymoma
Bulbar palsey
Trauma to head
Left cerebellar infarct
<b>Oropharyngeal malignancy</b>
Cancer of larynx
Severe mental retardation and hiatus hernia

The follow-up period was 1 month to 3 years. There was only one major complication, a haematemesis secondary to an ulcer adjacent to the internal bolster of the PEG. The ulcer was located on the anterior wall within the bolster's circumference. The suture securing the external bolster onto the PEG had come off resulting in increased mobility of the bolster. Minor complications occurred in 6 patients. Three patients had PEG site infections unassociated with fever which resolved without antibiotics. Two patients had a PEG site infection with abscess formation which necessitated drainage and antibiotics. The PEG fell out secondary to the resultant increase in the size of the orifice in one of them and necessitated replacement with a larger Foley catheter. This was removed 19 months later without further complication. The other patient had also developed an ileus which resolved spontaneously within 3 days. The sixth patient had an asymptomatic ulcer adjacent to the PEG noted upon removal of the PEG after 8 weeks. The ulcer was situated, again, within the bolster's circumference.

## Discussion

PEGs offers several advantages over nasogastric tubes in that they decrease the rate of aspiration, are easier to maintain and are more socially acceptable. Liquidised, or even mashed foods, are suitable with a PEG and patients do not necessarily require commercial feeds. This is a most important cost/convenience consideration.

Our major complication rate of 4,5% (1/22 patients) is in the 3 - 7% range quoted in the larger series.<sup>2-4</sup> The minor complication rate was 27% but the 30-day clinically significant

complication rate was 9% (2/22 patients); this compares favourably with the 15 - 20% incidence in other series. As of March 1990, we have had only one long-term complication in the group of patients followed up which continued until removal of the PEG or death of the patient. This was the haematemesis, resulting from the ulcer described before, which required an admission. The patient followed-up for 3 years had the same PEG in place until he died. One ICU patient, whose PEG was satisfactorily placed at 24 hours, died 3 days later of unrelated causes. One patient who survived for 18 months had the original PEG replaced because of cracking after 11 months. Complications as reported in other series are listed in Table II. As more people learn of the PEG, referrals will increase and our knowledge of the possible complications will expand. The procedure is now the method of choice in most parts of the developed world for providing nutrition in patients with an intact gastro-intestinal tract who cannot eat. We conclude that PEG is a safe and practical procedure in the appropriate patient when performed by experienced personnel.

TABLE II. COMPLICATIONS

<b>Major</b>
Death (aspiration, laryngospasm) <sup>2</sup>
Gastric perforation <sup>2</sup>
Gastric haemorrhage <sup>2</sup>
Haematoma <sup>2</sup>
Upper gastro-intestinal haemorrhage <sup>5</sup>
Fatal necrotising fasciitis <sup>6</sup>
<b>Minor</b>
Wound infection
Tube pulled out
Ileus/Ogilvie's
Fever
Aspiration
Stromal leak
Anorexia
Tube migration
Haematoma
Pneumoperitoneum <sup>7</sup>
Benign subcutaneous emphysema <sup>8</sup>

## REFERENCES

- Gauderer MWL, Ponsky JL, Izant RJ jun. Gastrostomy without laparotomy: a percutaneous endoscopic technique. *J Pediatr Surg* 1980; 15: 872-877.
- Larson DE, Burton DD, Schroeder KW, DiMagno EP. Percutaneous endoscopic gastrostomy: indications, success, complications, and mortality in 314 consecutive patients. *Gastroenterology* 1987; 93: 48-52.
- Ponsky JL, Gauderer MWL, Stellato TA. Percutaneous endoscopic gastrostomy: review of 150 cases. *Arch Surg* 1983; 118: 913-914.
- Foutch PG, Haynes WC, Bellapralu S, Sanowski RA. Percutaneous endoscopic gastrostomy (PEG): a new procedure comes of age. *J Clin Gastroenterol* 1986; 8: 10-15.
- Patel PH, Hunter W, Willis M, Thomas E. Upper gastrointestinal hemorrhage secondary to gastric ulcer complicating percutaneous endoscopic gastrostomy. *Gastrointest Endosc* 1988; 34: 88-89.
- Grief JM, Ragland JJ, Ochsner MG, Riding R. Fatal necrotizing fasciitis complicating percutaneous endoscopic gastrostomy. *Gastrointest Endosc* 1986; 32: 292-294.
- Plumser AB, Gottfried EB, Clair MR. Pneumoperitoneum after percutaneous endoscopic gastrostomy. *Am J Gastroenterol* 1984; 79: 440-441.
- Orchard JL, Barlow J. Benign subcutaneous emphysema after percutaneous endoscopic gastrostomy (Correspondence). *Gastrointest Endosc* 1987; 33: 51.