



FOCAL SEGMENTAL GLOMERULOSCLEROSIS IN MALIGNANT HYPERTENSION

S Kadiri, J O Thomas

Objective. Focal segmental glomerulosclerosis (FSG) may occur in primary malignant hypertension (MHT) either as a result of glomerular hyperfiltration or fibrinoid necrosis (FN), and may contribute to renal dysfunction. To determine the frequency of occurrence and distribution of FSG in primary MHT we studied renal biopsy specimens from 38 black Africans — 30 postmortem and 8 needle-biopsy specimens.

Subjects. There were 31 male subjects and 7 female, with a mean age of 46 (\pm 7) years.

Results. Mean blood pressure (BP) was 206 \pm 15/137 \pm 9 mmHg, median 24-hour proteinuria (interquartile (IQ) range) was 5.1 g (3.3 - 6.5 g), median serum albumin 3.4 g (3.2 - 3.8 g) and median serum creatinine 540 μ mol/l (425 - 752 μ mol/l). Mucoïd intimal proliferation was present in all the sections but FN was seen in 29 (76%). Glomerulosclerosis was present in all the sections, and was axially distributed in 7 (18%), segmentally in 22 (58%), and globally in 9 (24%). Median 24-hour proteinuria was 2.8 g (0.8 - 3.5 g IQ range), 5.6 g (1.7 - 8.1 g) and 3.4 g (2.6 - 4.0 g) respectively, and corresponding values of serum creatinine were 770 μ mol/l (106 - 1 274 μ mol/l IQ range), 522 μ mol/l (248 - 991 μ mol/l) and 1 230 μ mol/l (920 - 1 558 μ mol/l) respectively.

Conclusion. The distribution of glomerulosclerosis did not appear to relate to proteinuria or serum creatinine, although cases with segmentally distributed glomerulosclerosis appeared to have the highest proteinuria, and those with global glomerulosclerosis appeared to have the highest serum creatinine levels. FSG therefore occurs prominently in primary MHT and may contribute to renal dysfunction.

S Afr Med J 2002; 92: 303-305.

Malignant hypertension (MHT) is an important cause of renal failure.^{1,3} The major renal vascular lesions are mucoïd intimal proliferation (MIP) in the interlobular artery and afferent arteriole, and fibrinoid necrosis (FN) of the arterioles and glomerular tufts.^{4,7} Although severe renal failure would be

expected, it is not always the case, as some patients present with normal renal function.^{8,9} One probable mitigating factor is glomerular hyperfiltration which occurs in response to a variety of kidney injuries.^{10,11} Hyperfiltration is, however, ultimately deleterious, and leads to glomerulosclerosis.^{10,11} There have been reports of studies of glomerular diseases¹² and hypertension¹³ in which focal segmental glomerulosclerosis (FSG) has been found to be present in association with marked proteinuria^{12,13} and MHT.¹² FSG has also been noted in atheromatous renovascular disease, another condition associated with intrarenal ischaemia.¹⁴ There is the likelihood that apart from the MIP and FN, the FSG may contribute to the renal failure in MHT. However, it does not appear that primary MHT has been specifically studied to determine the occurrence of FSG, which is the aim of this study.

PATIENTS AND METHODS

MHT was defined as severe hypertension with bilateral retinal haemorrhages and exudates, with or without papilloedema.¹⁵ Primary hypertension was distinguished from secondary hypertension on the basis of history, physical examination, urine examination, renal ultrasound, serum electrolytes, intravenous urography and renal arteriography as necessary, and according to previous reports.^{1,16} Urinary albumin excretion and serum albumin were noted, as the absence of hypoalbuminaemia helps to differentiate secondary FSG from primary FSG.¹⁷ Decisions were further strengthened by histological examination of kidney specimens. Kidney sections were obtained from 38 cases of primary MHT — 30 postmortem and 8 needle biopsies. All cases were black Africans. Specimens were embedded in paraffin and sections cut at 4 micron thickness, and stained with haematoxylin and eosin (H & E), periodic acid-schiff reagent (PAS) and Jones' silver for light microscopy. Only sections showing 10 or more glomeruli were acceptable. Electron and immunofluorescence microscopy were not available.

The MIP, also known as the onion-skin lesion, and FN were the vascular lesions on which the histological diagnosis of MHT was based, and have been well described.^{4,6,18} Some workers consider the MIP to be the more specific lesion,⁵ especially in black patients.¹⁹ Glomerulosclerosis results from an increase in mesangial matrix and stains with H & E, PAS, and, unlike hyalinosis, also with silver stains.²⁰ It may be limited to the axial region in the early stages, and subsequently involves increasing portions of a minority of glomeruli in a focal and segmental distribution, before finally involving the majority in a global manner.

RESULTS

Renal biopsy material was obtained from 38 cases of MHT, 21 with retinal exudates and haemorrhages and 17 also with

Department of Medicine, University College Hospital, Ibadan, Nigeria
S Kadiri, MB BS, FWACP

Department of Pathology, University College Hospital, Ibadan, Nigeria
J O Thomas, MB BS, FRCPath



papilloedema. There were 31 male and 7 female patients, and the mean age was $46 (\pm 7)$ years. Mean blood pressure (BP) was $206 \pm 15 / 137 \pm 9$ mmHg. Twenty-four-hour proteinuria ranged from 800 mg to 8.1 g, with a median (interquartile (IQ) range) of 5.1 g (3.3 - 6.5 g). Serum albumin ranged from 2.9 g to 4.3 g, with a median of 3.4 g (3.2 - 3.8 g). Serum creatinine ranged from $106 \mu\text{mol/l}$ to $1\ 562 \mu\text{mol/l}$, with a median of $540 \mu\text{mol/l}$ ($425 - 752 \mu\text{mol/l}$). MIP was present in all the sections and was seen in the interlobular artery and afferent arteriole (Fig. 1). On the other hand, FN was present in 29 cases (76%) and occurred in the interlobular artery, afferent arteriole and glomerulus. PAS and silver stains showed glomerulosclerosis in all the sections. The sclerosis was confined to the axial region in 7 cases (Fig. 2), distributed in a focal and segmental manner in 22 (Fig. 3), and global in 9, and postmortem cases accounted for 5, 17 and 8 of these respectively. Tuft adhesions to Bowman's capsule occurred in all glomeruli showing FSG. The relationship of the distribution of glomerulosclerosis to proteinuria and serum creatinine is shown in Table I. The amount of proteinuria did not appear to correlate with the distribution of glomerulosclerosis, with wide overlaps

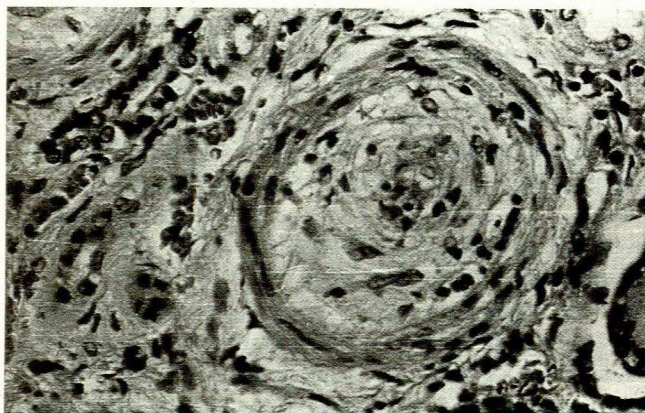


Fig. 1. Mucoïd intimal proliferation in an interlobular artery. H & E, $\times 400$.

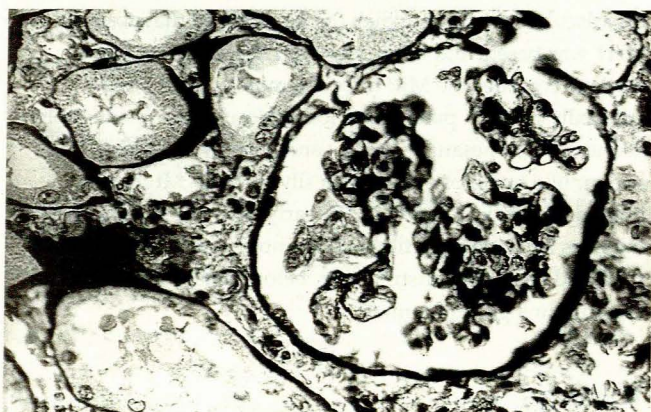

Fig. 2. Glomerulosclerosis affecting mainly the axial regions. Jones' silver, $\times 400$.

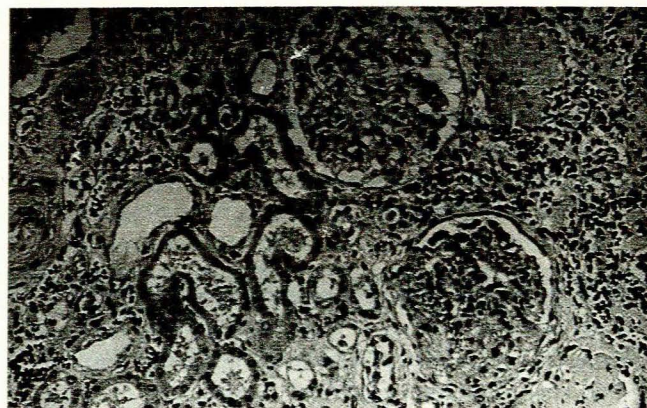


Fig. 3. Glomerulus at bottom shows focal and segmental sclerosis. H & E, $\times 250$.

Table I. Amount of glomerulosclerosis in relation to proteinuria and serum creatinine

	Axial	Focal segmental	Global
N	7	22	9
24-hour proteinuria (g)*	2.8 (0.8 - 3.5)	5.6 (1.7 - 8.1)	3.4 (2.6 - 4.0)
Serum creatinine ($\mu\text{mol/l}$)*	770 (106 - 1 274)	522 (248 - 991)	1 230 (920 - 1 562)

*Values are median (range).

occurring across the three groups, but cases with focal and segmental lesions appeared to have the greatest proteinuria. Similarly, the serum creatinine showed wide overlaps across the three groups but appeared to be highest in those with global glomerulosclerosis.

DISCUSSION

MHT is a condition accompanied by intrarenal ischaemia with consequent hyperreninaemia⁴ and the increased responsiveness of the efferent arteriole to angiotensin II leads to glomerular hypertension and hyperfiltration.^{10,11} This may mitigate the loss of function in the early stages and may account for some of the cases of MHT with normal or relatively normal renal function, despite the marked vascular insults. Later on the ensuing glomerulosclerosis adds to the renal injury and diminishing renal function. The foregoing may account for the prominence of glomerulosclerosis observed in this study. Glomerulosclerosis may also result from areas of the glomerulus that had suffered FN,¹⁸ and in this regard it would not be expected to occur in cases of benign, non-malignant hypertension. However, the presence of glomerulosclerosis, even in sections from which FN was absent, suggests that glomerulosclerosis can form independently of FN in some



cases. It might have been expected that as a temporal trend in the evolution of glomerulosclerosis those cases with the greatest spread or amount would have the poorest renal function, but that was not seen. A likely explanation for this is that on their own the MIP and FN were capable of causing severe renal dysfunction, sometimes reversible, and that the glomerulosclerosis occurred much later, as expected. Therefore in patients with more acute injury, as in cases presenting with acute oliguric renal failure, the vascular lesions may be dominant.

The amount of glomerulosclerosis did not appear to correlate with proteinuria, a well-recognised finding in most glomerulopathies whereby proteinuria diminishes with advancing renal failure, although the relationship in the earlier stages may be variable. The absence of FN from some sections supports the contention that it is not the most characteristic lesion in black patients, but rather that MIP is,^{5,7,19} although some other reports suggest otherwise.^{4,6} On the other hand, the absence of FN from these sections may be due to its replacement by glomerulosclerosis.

Even though attempts have been made to exclude cases with probable secondary hypertension, this could not always be guaranteed, especially in those with advanced renal failure. However, since the clinical data of the cases were examined in addition to the kidney histology, the differentiation between primary and secondary hypertension was made more easily. By studying mostly wedge sections of kidney tissue, we have largely avoided the sampling error inherent in the analysis of small biopsy specimens. Therefore, the absence of FN was unlikely to have been fortuitous, and was more likely to have been representative of the true situation in these cases with MHT.

FSG may be primary or secondary. The primary form accounts for up to 30% of the nephrotic syndrome²¹ and its cause is unknown, but the presence of a circulating factor that leads to increased glomerular permeability has been noted in some cases.²² The cases in our study had secondary FSG, of which there are several causes.^{17,21} It has been suggested that secondary FSG should be distinguished from the primary type in the setting of nephrotic-range proteinuria and the absence of oedema, hypoalbuminaemia and hypercholesterolaemia,²¹ but as with some of our cases proteinuria may not always be present in nephrotic proportions. By and large serum albumin levels were normal in our patients, and this was consistent with secondary FSG. Reports of the kidney histology in MHT have generally not emphasised the prominence of FSG although some workers had commented on the hyalinosis²³ that often accompanies FSG, and the probable formation of FSG from necrotic areas,¹⁸ even though hypertension is a recognised cause of FSG.²¹ However, as earlier stated, FSG has been reported in various glomerular diseases with or without coexistent MHT,¹² and some reports on non-malignant

hypertension have described the occurrence of FSG, usually in association with nephrotic-range proteinuria.^{13,24} In our study FSG occurred in MHT with or without nephrotic-range proteinuria and was associated with different levels of renal function. This prominence of FSG is in keeping with the reported increased frequency in black subjects,²⁵ who constituted all our cases.

It would therefore seem that FSG is a rather prominent finding in our patients with primary MHT. This may reflect the late consequence of attempts at mitigating the loss of renal function through hyperfiltration or glomerular hypertension, or may be a sequela of the FN, at least in those cases with FN. The presence of FSG portends a less favourable outcome since it is most often associated with progression of renal disease.²¹ Nevertheless, this whole train of events lends itself to some manipulation, as extremely tight BP control may slow the rate of disease progression.²⁶

References

- Kadiri S, Olutade BO. The clinical presentation of malignant hypertension in Nigerians. *J Hum Hypertens* 1991; 5: 339-343.
- Gold CH, Isaacson C, Levin J. The pathological basis of end stage renal disease in Blacks. *S Afr Med J* 1982; 61: 263-265.
- Lip GY, Beevers M, Beevers DG. Complications and survival of 315 patients with malignant phase hypertension. *J Hypertens* 1995; 13: 915-924.
- Kadiri S, Thomas JO. Kidney histology and clinical correlates in malignant hypertension. *Med Clin North Am* 1987; 71: 843-858.
- Kincaid-Smith P. Malignant hypertension. *J Hypertens* 1991; 9: 893-899.
- Isaacson C, Milne FJ, van Niekerk I, Kenyon MR, Mzamane DV. The renal histopathology of essential malignant hypertension in black South Africans. *S Afr Med J* 1991; 80: 173-176.
- Kadiri S, Thomas JO. Kidney histology and clinical correlates in malignant hypertension. *East Afr Med J* 1993; 70: 112-116.
- Lip GY, Beevers M, Beevers DG. The failure of malignant hypertension to decline: a survey of 24 years' experience in a multiracial population in England. *J Hypertens* 1994; 12: 1297-1305.
- Sharma BK, Singh G, Sagar S. Malignant hypertension in north West India. A hospital based study. *Jpn Heart J* 1994; 35: 601-609.
- Hostetter TH. The hyperfiltering glomerulus. *Med Clin North Am* 1984; 68: 387-398.
- Remuzzi G, Bertani T. Pathophysiology of progressive nephropathies. *N Engl J Med* 1998; 339: 1448-1456.
- Bohle A, Biber E, Christensen JA. Hyperperfusion injury of the human kidney in different glomerular diseases. *Am J Nephrol* 1988; 8: 179-186.
- Harvey JM, Howlew AJ, Lee SJ, et al. Renal biopsy findings in hypertensive patients with proteinuria. *Lancet* 1992; 340: 1435-1436.
- Thadhani R, Pascual M, Nickleleit V, Tolkooff-Rubin N, Colvin R. Preliminary description of focal and segmental glomerulosclerosis in patients with renovascular disease. *Lancet* 1996; 347: 231-233.
- Ahmed MEK, Walker JM, Beevers DG, Beevers M. Lack of difference between malignant and accelerated hypertension. *BMJ* 1986; 292: 235-237.
- Rodicio JL, Ruilope LM. Assessing renal effects and renal protection. *J Hypertens* 1995; 13: Suppl 4; S19-S25.
- Praga M, Borstein B, Andres A, et al. Nephrotic proteinuria without hypoalbuminaemia: clinical characteristics and response to angiotensin converting enzyme inhibition. *Am J Kidney Dis* 1991; 17: 330-338.
- Jones DB. Arterial and glomerular lesions associated with severe hypertension: light and electron microscopy studies. *Lab Invest* 1974; 31: 303-313.
- Pitcock JA, Johnson JG, Hatch FE, Acchiardo S, Muirhead FE, Brown PS. Malignant hypertension in blacks: Malignant intra-renal disease as observed by light and electron microscopy. *Hum Pathol* 1976; 7: 333-346.
- World Health Organisation. *Renal Disease: Classification and Atlas of Glomerular Diseases*. Tokyo: Igaku-Shoin, 1982.
- D'Agati V. The many masks of focal segmental glomerulosclerosis. *Kidney Int* 1994; 46: 1223-1241.
- Savin VJ, Sharma R, Sharma M, et al. Circulating factor associated with increased glomerular permeability to albumin in recurrent focal segmental glomerulosclerosis. *N Engl J Med* 1996; 334: 878-883.
- Mittal BV, Almeida AF. Malignant hypertension — a clinico-pathologic study of 43 cases. *J Postgrad Med* 1987; 33: 49-54.
- Mujais SK, Emmanouel DS, Kasinath BS, Spargo B. Marked proteinuria in hypertensive nephrosclerosis. *Am J Nephrol* 1985; 5: 190-195.
- Korbet SM, Genchi RM, Borok RZ, Schwartz MM. The racial prevalence of glomerular lesions in nephrotic adults. *Am J Kidney Dis* 1996; 27: 647-651.
- Klahr S, Levey AS, Beck GJ, et al. The effect of dietary protein restriction and blood pressure control in the progression of chronic renal disease. *N Engl J Med* 1994; 330: 877-884.

Accepted 24 May 2001.