



Four decades of conjoined twins at Red Cross Children's Hospital – lessons learned

H Rode, A G Fieggen, R A Brown, S Cywes, M R Q Davies, J P Hewitson, E B Hoffman, L D Jee, J Lawrenson, M D Mann, L S Matthews, A J W Millar, A Numanoglu, J C Peter, J Thomas, H Wainwright

Conjoined twins represent a rare but fascinating congenital condition, the aetiology of which remains obscure. Over the past four decades, the paediatric surgeons at Red Cross Children's Hospital have been involved in the management of 46 pairs of conjoined twins, of which 33 have been symmetrical and 12 asymmetrical. Seventeen symmetrical twins have undergone separation with 22 children (65%) surviving; all of the live asymmetrical twins survived separation. We describe the important features of this unique cohort, outline our approach to management and present the results of

this approach. We consider some of the ethical and moral dilemmas we have confronted, and discuss the prenatal diagnosis, obstetric implications and postnatal care of these children, including the relevant investigations and anaesthetic and surgical management. Specific aspects related to the cardiovascular system, hepatobiliary and gastrointestinal tracts, urogenital tract, central nervous system and musculoskeletal system are highlighted.

S Afr Med J 2006; **96**: 931-940.

'A soul with two thoughts. Two hearts that beat as one.'
McCoy sisters

Historically, from the beginning of time the birth of conjoined twins has fascinated mankind with the public's view of malformed children greatly influenced by the prevailing culture and religious beliefs. In prehistoric times, conjoined twins were depicted in cave drawings, on pottery or as

figurines. In folklore they were often regarded as an omen of impending disaster, eliciting strong emotions ranging from wonder and admiration to rejection and hostility. Although malformed children were treated compassionately at times, historical records show that infanticide was frequently practised and the mother often held responsible for causing the malformation.^{1,2}

Although the worldwide incidence of monozygotic twinning is the same in all ethnic groups, the incidence of conjoined twins appears to be higher in sub-Saharan Africa,^{3,4} ranging from 1:50 000 to 1:100 000 live births, or 1 in 400 monozygotic twin births. Thirty-one sets were born in southern Africa between 1974 and 1982, of which 15 were stillborn, 7 were considered inoperable and only 4 were successfully separated.⁵ There was no information on 5 others. The natural history that follows a prenatal diagnosis of conjoined twins confirms that a large number of infants die either *in utero* (28%) or immediately after birth (54%); in fact, only 18% survive.⁶

Conjoined twins are monozygotic, mono-amniotic and monochorionic and are always of the same gender with a 3:1 female preponderance. Embryologically, their formation results either from failure of separation of the embryonic plate between 15 and 17 days' gestation, or from secondary union of two separate embryonic discs at the dorsal neural tube or ventral yolk sac areas at 3 - 4 weeks' gestation. Spencer's extensive embryological studies⁷⁻⁹ appear to favour the latter theory, but this remains controversial. Although genetically identical, one infant is almost always weaker or smaller than the other and may have additional congenital defects. They also develop dissimilar personalities from an early age.

Conjoined twins are always joined at homologous sites and the clinical classification is based on the most prominent site of union, combined with the suffix 'pagus'.¹⁰ The

Division of Paediatric Surgery, Red Cross War Memorial Children's Hospital, Rondebosch, Cape Town

H Rode, MB ChB, MMed (Surg), FRCS (Edin), FCS (Surg) (SA)
A G Fieggen, BSc (Med), MB ChB, MSc (Lond), FCS (Neurosurg) (SA)
R A Brown, MB ChB, MPhil (Ancient Cultures), DCH (SA), FRCS (Edin), FCS (Surg) (SA)
S Cywes, MB ChB, OMSG, MMed (Surg) (SA), FACS (Ped), FRCS (Eng and Edin), FRCPS (Glas), FAAP (Hon), FCS (Hon) (SA), DSc (Hon)
M R Q Davies, MB ChB, MMed (Surg), FCS (Surg) (SA), FRCS (Eng and Edin)
J P Hewitson, MB ChB, FCS (Cardiothorac) (SA)
E B Hoffman, MB ChB, FCS (Orth) (SA)
L D Jee, MB ChB, FCS (Urol) (SA), MMed
A J W Millar, MB ChB, FRCS (Eng), FRACS, FCS (SA), DCH
A Numanoglu, FCS (Surg) (SA)
J C Peter, MB ChB, FRCS (Edin)

Division of Cardiology, Red Cross War Memorial Children's Hospital
J Lawrenson, FCP (SA), MMed

Division of Paediatrics, Red Cross War Memorial Children's Hospital
M D Mann, MB ChB, MMed (Paed), MMed (Nuc Med), PhD

Fetal Medicine Unit, Groote Schuur Hospital and University of Cape Town
L S Matthews, MB ChB, MD (O&G)

Division of Anaesthesiology, Red Cross War Memorial Children's Hospital
J Thomas, MB ChB, BSc (Ed), FAA (SA)

Division of Pathology, Red Cross War Memorial Children's Hospital
H Wainwright, MB ChB, FFPATH (SA) Anat

Corresponding author: H Rode (rode@ich.uct.ac.za)



twins are individual and deformed but symmetrical and proportional. There are eight recognised configurations, i.e. thoracopagus (chest), omphalopagus (umbilicus), ischiopagus (hip), pygopagus (rump), rachipagus (spine), craniopagus (cranium), cephalopagus (head), and parapagus (side). They can be further described as symmetrical or asymmetrical; asymmetrical or incomplete conjoined twins result from the demise of one twin with remnant structures attached to the complete twin but the junction remains at or near one of the common sites of union. Fetus in fetu refers to asymmetrical monozygotic diamniotic intraparasitic twins.¹¹ Conjoined triplets 'and beyond' are exceptionally rare; their pathogenesis remains even more obscure.¹²

The surgical separation of conjoined twins presents a great challenge and undoubtedly requires a multidisciplinary team. An unequal external union, variations in internal anatomy and discordant anomalies, especially in the right-sided twin, mandate thorough elucidation of the anatomy of conjunction before planning the surgical procedure required to separate and individualise the twins. The first successful surgical separation took place in 1689 and more than 1 200 cases had been reported in the literature by 2000.¹³ This report is a description of the lessons learned at one hospital over a period of 42 years, encompassing prenatal diagnosis, obstetric intervention, early postnatal management, special investigations, surgical strategies, anaesthetic considerations, ethical aspects and outcome.

Material and methods

Red Cross War Memorial Children's Hospital serves as a regional referral centre for the management of conjoined twins. Unborn twins have been referred for advice either to plan the mode of delivery because of obstetric implications, or for consideration of termination of pregnancy and the attendant ethical and moral considerations. Ideally the immediate perinatal management of the babies is also planned. Once born, they were referred for appropriate investigation and surgical management and the therapeutic options considered ranged from conservative, non-surgical management to emergency or planned surgery.

Investigations were directed towards identifying the anatomy of conjunction, and consequently the viability of separation (Table I). The areas of fusion largely determined the imaging modalities chosen. Skeletal surveys, echocardiography, ultrasonography, computed tomography (CT) and magnetic resonance imaging (MRI) provided excellent anatomical detail, demonstrating organ position, shared viscera and vascular anatomy. Contrast imaging evaluated the gastrointestinal and urinary systems and endoscopy was of further help in the urogenital assessment. Radioisotopes assessed regional perfusion fields. Twins with no reasonable chance of survival, largely due to cardiac anomalies

Table I. Multidisciplinary investigations

System	Evaluation
Cardiorespiratory	Electrocardiogram Echocardiography/Doppler ultrasound MRI/CT with contrast Angiogram
Alimentary tract	Contrast meal and enema Ultrasound Radio-isotope scans (liver); technetium Tc99m-(Sn) colloid and excretion Tc99m mebrofenin Radio-isotope scintigraphy
Genito-urinary	Ultrasound Isotope renography Micturating cystourethrography Genitogram
Skeletal system	Radiography MRI (spinal cord) Ultrasound
Vascular	Doppler ultrasound Angiography
Cross-circulation	Radio-isotope scan Tc99m-DMSA

incompatible with life, and those with irreversible postnatal diseases such as necrotising enterocolitis, received only palliative treatment and were not considered for separation.

Emergency surgery was performed when there was damage to the connecting bridge or when correctable anomalies threatened the survival of one or both twins. Elective surgery was performed only when the infants were thriving and all investigations had been completed, providing a comprehensive and functional description of normal and fused anatomy.

Clinical results

Over a period of 42 years (1964 - 2006), Red Cross Children's Hospital has managed 46 sets of symmetrical and asymmetrical conjoined twins. The diagnosis of conjoined twins has important obstetric implications and our results are combined with those of Viljoen *et al.*⁵ to formulate a comprehensive database to guide obstetric management. The relevant



information is shown in Table II. There was a tendency towards premature labour and caesarean section (CS) for obstructed labour. There were few postnatal maternal complications.

The surgical management of conjoined twins is divided into three categories (Tables III and IV).

1. Non-operative management. Ten sets were stillborn, 8 of which were thoracopagus, 1 ischiopagus and 1 triplet. Intrauterine death was either due to elective abortion (13 - 32 weeks), obstetric error or complex cardiac anomalies incompatible with life, confirmed by postmortem examination. These fetuses were lost during the 26 - 30th week of gestation. Five sets of thoracopagus twins were born alive but subsequently died from complex cardiac anomalies with cardiac failure at 9 days - 2 months after birth. One symmetrical ischiopagus twin died as a result of a perforated colon and peritonitis.

2. Emergency separation. Emergency operations were performed on 3 symmetrical sets during the neonatal period. A thoracopagus twin deteriorated on day 15 necessitating emergency separation. Great difficulty was encountered closing the thoraco-abdominal defects primarily, which resulted in irreversible respiratory failure. An omphalopagus twin was born with a ruptured exomphalos with evisceration of liver and loops of bowel and death of the other. One parapagus twin was moribund at birth necessitating surgical separation within 17 hours once preliminary investigations had been performed. Only 2 of 6 children survived separation with 1 dying at 6 weeks from bronchopneumonia.

3. Elective separation. Elective separations were performed on 14 sets at ages ranging from 4 days to 11 months, when tissues were still pliable and the infants in the optimal physiological state. Reasons for the wide variation included allowing time for the infants to grow and to bond with their families and also for completion of the multitude of investigations required. On occasion it was also necessary to resolve complex moral and ethical issues when there was a threat to the survival of one or both infants. Additional delay was due to the use of tissue expanders in 2 sets of ischiopagus twins to facilitate wound closure, repeated operative rehearsals, and reordering of selected investigations where uncertainty existed. Twenty-two of a potential 28 children survived. In one set of thoracopagus twins with a combined complex heart the decision was made to sacrifice one of the children, with the parents' permission, to save the life of his brother. This child is the only long-term survivor following a procedure of this kind.

An assessment of the cardiac anomalies encountered in 16 thoracopagus infants during pre-surgical investigations, during surgery and at autopsy revealed the following: a shared pericardial sac with separate hearts in 5, conjoined hearts in 8 who manifested varying types of atrial or ventricular fusion, and a single heart in 3. Other abnormalities identified included anomalous pulmonary veins, atrioventricular septal defects,

Table II. Obstetric implications – 54 sets*

Maternal history	
Maternal age in years	23 (16 - 45 range)
Parity – nulliparous	38% (17 of 45 sets)
Family history of twinning	14.3% (8 of 54 sets)
Stillbirths	39.6% (21 of 54 sets)
Antenatal diagnosis	41% (32 sets)
Birth	
Presentation	
Breech	52% (13 of 25 sets)
Vertex	48% (12 of 25 sets)
Vaginal delivery	41% (19 of 46 sets)
Mean gestational age (wks)	35.3 (20 sets)
Combined weight (kg)	3.9 (2.7 - 4.9 in 13 sets)
Elective CS	59% (27 of 46 sets)
Maternal complications	Minimal, only 1 death

*Obstetric information extrapolated from available data.⁵
CS = caesarean section.

Table III. Conjoined twins 1964 - 2006

	Sets	Operations	Survivors
Symmetrical			
Thoracopagus	22	9	10
Omphalopagus	1	1	1
Ischiopagus	5	3	6
Pygopagus	2	2	4
Parapagus	1	1	1
Craniopagus	1	1	0
Cephalopagus	1	0	0
Total	33	17	22
Incomplete/ asymmetrical			
Ischiopagus	4	3	3
Parasitic	5	5	5
Fetus in fetu	3	3	3
Total	12	11	11
Conjoined triplets	1	0	0

hypoplastic pulmonary vessels, abnormal vena caval drainage and abnormal origin of major arterial vessels from the aortic arch.⁹

Surgical outcome

The surgical outcome of our series is depicted in Table III and compared with two international series in Table IV. The overall survival for symmetrical twins was 33.3% but 64.7% for

**Table IV. Outcome in three major studies on conjoined (symmetrical) twins**

Source	No. of sets	Not operated sets	Operated			
			Emergency Surgery		Elective surgery	
			No. of sets	No. of survivors (%)	No. of sets	No. of survivors (%)
Spitz and Kiely ¹⁴	22	6	7	4 (29)	9	15 (83)
O'Neill ¹⁹ 1998	18	5	5	1 (10)	8	13 (81)
Present series	33	16	3	2 (33)	14	20 (72)

those that were operated on. Emergency surgery had a dismal outcome with only 2 infants surviving (33%). Asymmetrical separation had a 92% survival rate.

Discussion

Improved survival rates for conjoined twins are due to advances in perinatal and postnatal diagnostic techniques, meticulous interpretation of the special investigations and correct anaesthetic and surgical management carried out by an experienced multidisciplinary team.¹⁴⁻²¹ Because of our extensive clinical experience, we have learned that the anatomical configurations encountered are very complex, with unexpected anatomical variation frequently identified during surgery.

Ethical and moral considerations

Ethical considerations, which need to reconcile the best options for the twins and their parents, are playing an increasing role in present-day decision-making.^{22,23} Sacrifice of one twin because of inability to sustain life alone is the controversy that evokes the most anguish. The decision on whether to operate or not is rendered more complex by those surviving living conjoined twins who consciously elected not to be separated and report that they have lived socially acceptable lives.¹⁷

Being conjoined does not necessarily negate individual development. Religious views may only support minimal surgical interference, especially when one twin will be sacrificed at surgery. 'We cannot accept one baby must die so that the other one may live. It is not God's will', which differs from the legal opinion 'Why I must order twin baby to die', or 'As we came together, we will also go together' (Eliza Chulkhurst²).

From a practical point of view we have adopted the Great Ormond Street Ethical Guidelines for Conjoined Twin Separation. Where separation is feasible with a reasonable chance of success it should be carried out; when surgery is not

possible, custodial care should be offered and nature allowed to take its course; where one twin is dead or has a lethal abnormality and cannot survive independently from its normal twin and if not operated on both twins could die, separation to save the healthy twin should be attempted.²³

Prenatal diagnosis

In 1950, Gray *et al.*²⁴ proposed radiological criteria for diagnosing ventrally fused twins but with the advent of 'real-time' ultrasound, CT and MRI scans, plane radiographs lost their importance as a diagnostic tool. Prenatal ultrasound investigations have resulted in an increased detection of conjoined twins. The diagnosis has been made as early as 12 weeks' gestation but is more accurate from 20 weeks.²⁵ Same-sex twins, a single placenta, shared organs and persistent alignment will suggest conjoined twinning. The diagnosis is seldom missed by those experienced in obstetric ultrasound. Serial scans in the second trimester may be necessary to define anatomy further. Prenatal assessment of the extent of organ involvement is often difficult for technical reasons, i.e. the position of the fetuses *in utero*, and the presence of oligo- or polyhydramnios. Recent advances in ultrasound technology, the use of colour Doppler flow studies, and prenatal MRI have improved prenatal diagnosis.

The main objective of prenatal diagnosis is to define the extent of the abnormalities and to counsel the parents accordingly. A team approach is used, combining the experience of the ultrasonologists with the obstetricians, neonatologists, geneticists, pathologists and paediatric surgeons. Termination of pregnancy is offered when fetal echocardiography shows a shared heart, if the anticipated deformities following separation are extensive, and in the presence of cerebral conjunction (Fig. 1). Management of parents who opt to continue with the pregnancy is aimed at maximising the potential for survival of the twins and minimising maternal morbidity.

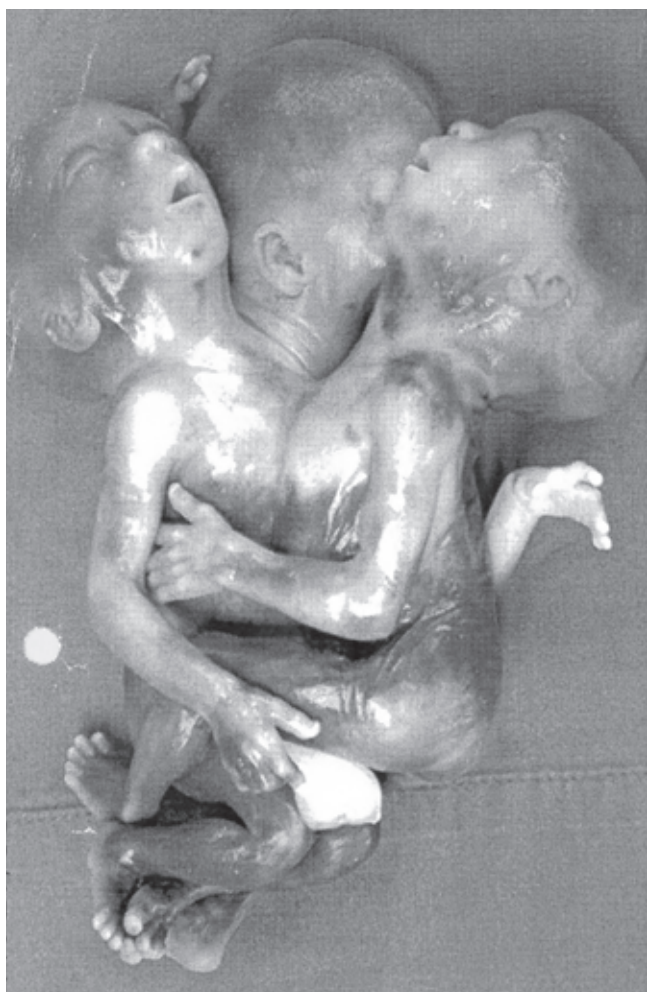

Fig. 1. Conjoined triplets – one set of thoracopagus twins with a parapagus twin attached to the one thoracopagus twin.

Obstetric implications

The birth of conjoined twins is often unexpected, resulting in obstructed labour with difficult transvaginal delivery or emergency CS.^{5,26} These complications can be avoided by planned CS at 36 - 38 weeks, once the lungs have reached maturity, because of the high rate of stillbirths and dystocia. In our experience CS was necessary in all but one set of twins with a combined weight of more than 3.9 kg. Children weighing less, including thoracopagus and ischiopagus, were born vaginally. None of the children born normally sustained any damage to the connecting sites (bridges), except for a 5.3 kg omphalopagus twin with ruptured exomphalos, evisceration of liver and bowel and with one twin stillborn. Tragically, one mother died during labour.

Postnatal management

Immediate postnatal management consists of resuscitation and stabilisation of the twins. This is followed by a thorough physical examination with special investigations to define the

relevant anatomy. If emergency surgery is anticipated, all twins should undergo echocardiography and plain roentgenography, which provides limited but essential information. The site of conjunction will determine the type and order of special investigations. The information obtained will determine the surgical approach, the timing of separation, the allocation of organs and structures and the eventual prognosis regarding survival and functional outcome. Important structures to evaluate are cardiac, hepatobiliary, intestinal, urogenital and spinal systems.^{27,28} The use of diagrams, 3D organ models and surgical rehearsal of the procedure will ensure the best possible outcome. Despite all these investigations and careful analysis of findings, preoperative interpretation may still be difficult with incorrect conclusions drawn.

Emergency separation resulted in an up to 70% mortality rate compared with 20% for elective procedures, emphasising the need to stabilise the infants initially and to postpone surgery until the basic investigations have been completed.⁶ In our experience, emergency surgery was necessary to alleviate intestinal obstruction, to manage a ruptured exomphalos, and for deteriorating cardiac-respiratory status threatening survival of one or both twins. Delaying separation into early childhood may result in increased postnatal deformities and psychological problems. If it is possible to separate the twins, it is proposed that surgery should be performed within the first 6 - 9 months before an awareness of their condition develops. Motor skills, sensory integration and personality need to develop in a separated state.²⁹

Anaesthetic considerations

Anaesthesia for separation of conjoined twins is a complex, demanding procedure that is facilitated by having two colour-coded anaesthetic teams, one representing each child.^{30,31} Our experiences have highlighted the following. The infants are often premature with pre-existing cardiac and pulmonary dysfunction, and induction of anaesthesia is often compromised by the abnormal positions and proximity of the twins. During surgery difficulties with vascular access, haemodynamic stability and temperature control can be considerable.

To maintain haemodynamic stability, blood volumes transfused ranged from 10% to 450% of the estimated blood volume. Blood loss was especially extensive in thoracopagus and ischiopagus separations, and relative changes in position of the two infants during surgery leads to significant shifts in blood volumes. Owing to cross-circulation, pharmacokinetics and pharmacodynamics are inconsistent, especially in thoracopagus twins, and altered drug responses must be expected. Anticipated problems after separation include respiratory insufficiency, haemodynamic instability, fluid imbalance, temperature control, sepsis, wound closure and residual organ dysfunction.



Surgical separation and reconstruction

Many descriptions of surgical procedures to separate the various types of conjoined twins have been published.^{13,15-20} Technical details are determined by the anatomy of conjunction, the allocation of sharing of organs and structures and the planned reconstruction. Standard approaches are normally utilised but variations may demand a novel surgical approach or alternative techniques. Major factors that will govern successful separation include the order of separation, the distribution of organs between the twins, meticulous aseptic surgical techniques, the reconstruction of divided organs and structures and wound closure. It is also necessary to distinguish between structures that are shared by both twins and those belonging only to one of them.⁷ Allocation of shared organs usually involves the anus, rectum, genitourinary tract, lower spine and spinal cord. Unexpected anatomical variations are often encountered, including previously unrecognised cardiac, gastrointestinal, hepatobiliary, spinal and genitourinary anomalies. Operation time is prolonged with the separation of the more complex thoracopagus and ischiopagus twins, where it is in the order of 7 - 13 hours and 13 - 19 hours, respectively.

Skin closure

Whenever there is extensive sharing of body surface areas, e.g. thoracopagus and ischiopagus, closure of the disconnected surfaces may pose major problems, especially when separation is undertaken as an emergency.³²⁻³⁴ Subcutaneous tissue expansion is used to provide tissue for reconstruction or closure where insufficient natural tissue exists (Fig. 2). This allows for primary tension-free closure, thereby minimising respiratory and wound complications. Unfortunately tissue expansion was unsuccessful in 60% of our cases because of factors such as placement over bony areas with little subcutaneous tissue, wound sepsis and skin necrosis. Skin expanders must be correctly sited and placements are

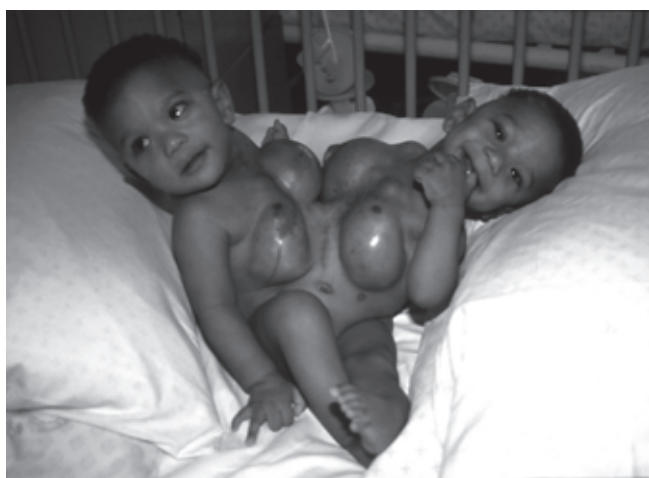

Fig. 2. Ischiopagus twins with four skin expanders. Note the position and size of expansion.

best tolerated in older infants. It takes 6 - 8 weeks to gain maximum advantage.¹⁹

Cardiovascular system

Experience with 22 thoracopagus twins has taught us that evaluation requires the use of every tool available – from clinical evaluation to angiography. The ECG is generally unreliable as two separate ECGs do not rule out significant sharing of cardiac structures. The mainstay of the evaluation is echocardiography, generally best accomplished by a pair of investigators who meticulously double-check each other's findings.³⁵ The investigators may be left with apical and suprasternal views only. Trans-oesophageal echo has not been possible given the size of the infants. The newer multi-slice CT scanning and modern MRI machines will clearly have a role to play in future evaluations despite the radiation exposure and the need for a general anaesthetic.

In our limited experience an MRI investigation resulted in 'overcalling' of ventricular sharing. Angiography under general anaesthetic may still be needed, but it remains a high-risk procedure with an unpredictable response to anaesthesia. In a set of twins with venous-pole sharing induction of anaesthesia resulted in asystole in the twin with a myopathic ventricle – leading to brain death and an emergency separation. Before separation the surgeon may still not know the exact nature of venous connections, coronary arterial anatomy, the branching anatomy of the head and neck vessels and the true size of the right ventricle.

No twins with ventricular conjunction have ever been successfully separated with both surviving; only one of our twins with shared ventricles survived. At surgery it became apparent in this case that successful separation was impossible without sacrificing one infant. All the main inflow and outflow vessels from one child were then disconnected from the heart and the whole cardiac complex was assigned to the infant selected to survive. One other child from a sacrifice procedure survived for 30 days and died from aspiration.

Hepatobiliary system

The liver is shared in almost all ventral forms of conjoined twins. Ultrasound, CT and radio nucleotide scanning provide the best overall picture of hepatic conjunction, the biliary drainage system including the gallbladder, and the configuration of the pancreas (Fig. 3). For successful hepatic division, each liver has to have an inferior vena cava to its own heart. Hepatic conjunction is along an oblique plane and venous connections may consist of a labyrinth of small venous channels that may bleed excessively during surgery. In our experience, hepatic division has always been possible. Cardiac disconnection must be accomplished before hepatic division, as a large volume of blood can circulate through the liver, creating a false impression that both hearts are functioning haemodynamically satisfactorily to sustain independent life.

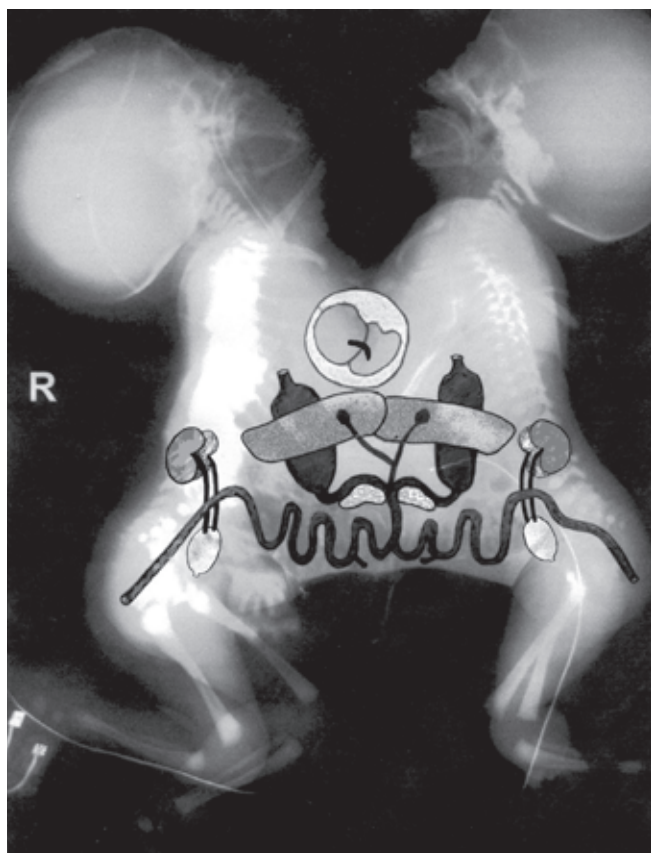

Fig. 3. Thoracopagus twins with anatomical normal hearts with overlapping ventricles and an intra-atrial tubular connection. The livers were fused in an oblique plane with two gallbladders and a single extrahepatic drainage system connecting with a fused upper duodenum. A single pancreas was present and the single jejunum was separated into two ilea at Meckel's point with two normal colons. Four kidneys were present.

The anatomy of the extrahepatic biliary system (EHBS) needs to be confirmed, and this may require intraoperative cholangiography.^{20,36} Two gallbladders do not always equate with two EHBSs, especially if there is fusion of the proximal duodenum which may be demonstrated by upper contrast radiography. However two gallbladders and two duodenum usually indicate two separate extrahepatic bile ducts. Bile drainage is imperative, and in the presence of a single EHBS, one twin should be allocated the EHBS, while every attempt should be made to establish bile drainage through a Roux-Y hepaticojejunostomy in the other twin.⁴ Anatomically the pancreas belongs to the duodenum, and is best left with the EHBS.

Gastrointestinal system

The intra-abdominal gastrointestinal tract (GIT) is frequently shared in ventral and caudal types of junction and usually follows one of two patterns. Duodenal junction is often encountered in thoracopagus twins. The junction can extend

distal to the duodenum and involve the upper small bowel up to the level of Meckel's point, where it divides again into two separate distal ilea. The second type of GIT sharing, viz. ileocolic or rarely only colonic, is commonly encountered in ischiopagus twins. The single ileocolon, resembling a conjoined organ, opens into a single anus. A double blood supply may facilitate longitudinal division of the colon, thus preserving an anatomically normal or foreshortened colon for each child. Alternatively, one child can be allocated the ileocecal valve and the other the anus, with both sharing the divided colon. Pygopagus twins always have a common anal canal. It is our practice to reconstruct the anorectal region at the time of primary division. A previously placed colostomy, however, demands a different type of allocation and reconstruction.

Urogenital tract

Complex and variable urogenital abnormalities accompany pelvic fusion and are restricted to symmetrical and asymmetrical ischiopagus and pygopagus twins (Fig. 4). The incidence of shared pelvic organs is in the order of 15% for pygopagus to 51% for ischiopagus twins. An unobstructed continent urinary system with a physically acceptable and functional genital system is the primary goal. Essential in the workup of urogenital abnormalities are genitourinary ultrasound, isotope renography, micturating cysto-urethrogram and endoscopy.^{18,37-39}

The kidneys may vary in number, size and ectopia, in degree of fusion and in the course of the ureters. Most ischiopagus twins have four kidneys and two bladders, with one ureter crossing to the ipsilateral and one to the contralateral bladder. One or two bladders may be present, lying side by side, or fused in the midline, with one draining into the other. In most cases, despite these variations, a functional bladder can be reconstructed. The presence of spinal fusion in its various forms complicates the situation by introducing a neuropathic element into the behaviour of the bladder, which has a significant influence on future management. Crucial decisions regarding assignment are therefore required when shared organs, which cannot be divided, are present.

The genital pattern varies widely and every effort should be made to achieve functional reconstruction, which may require an individual approach. In females, urogenital sinuses or even cloacal abnormalities are often present, requiring careful consideration during division, allocation of organs and reconstruction (Fig. 5). In males, the status of the external genitalia, urethra and testes are important. Twins with two sets of external genitalia can undergo successful separation, and secondary reconstructive genitoplasty may be required if only one set of external genitalia is present. Staged procedures may be required to achieve optimal outcome.

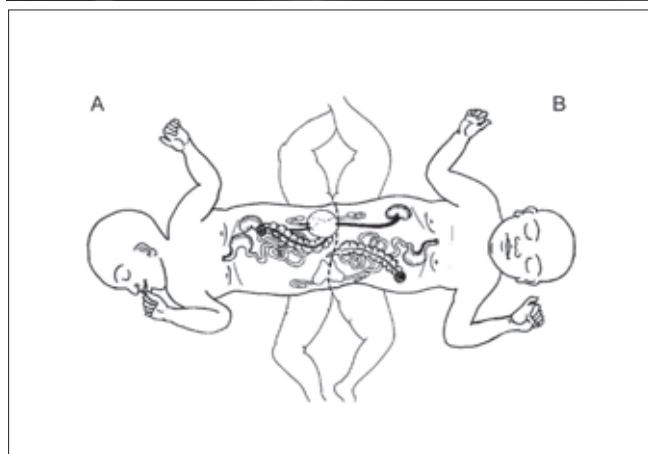
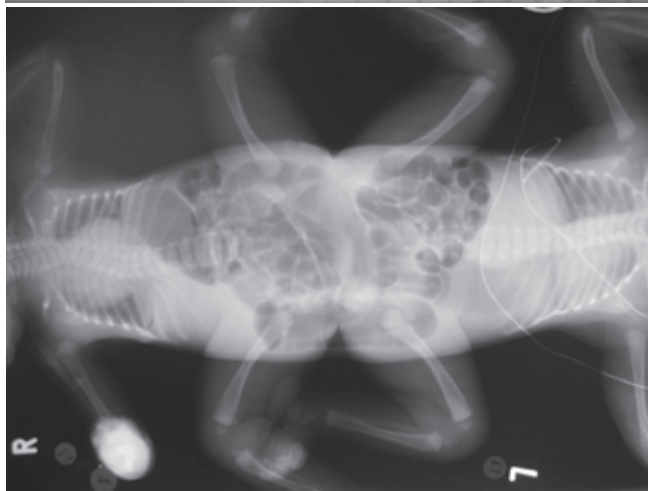

Fig. 4. Clinical appearance of ischiopagus tetrapus twins. The radiograph depicts the extensive pelvic fusion and the drawing indicates gastrointestinal, upper urinary tract and internal genital abnormalities encountered at surgery.

938 Central nervous system

Neurosurgical interest in conjoined twins has tended to focus on craniopagus twins who comprise only 2 - 6 % of all conjoined twins but present some of the greatest challenges in separation. The only craniopagus in this series was operated in

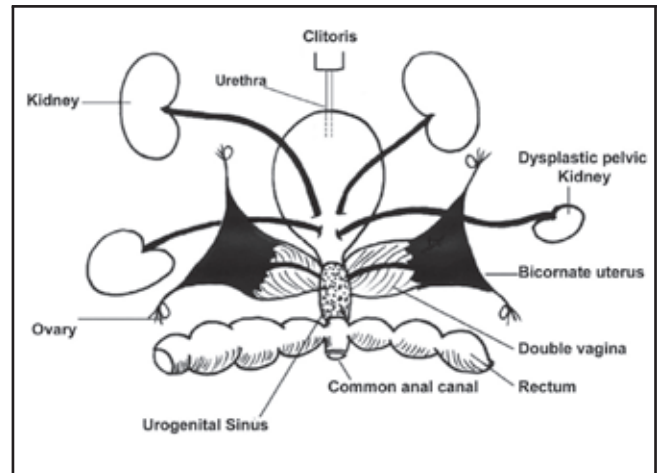


Fig. 5. Complex cloacal abnormalities in female ischiopagus twins. Midline division allowed for equal allocation of organs.

1964; at that time, survival was virtually unheard of and both infants died intraoperatively from uncontrollable blood loss.

A recent review proposes a practical four-category classification based on the angle of union (vertical or angular) and the degree to which the dural venous sinuses are shared.⁴⁰ Conjoined cerebral tissue may present an important technical challenge, but preservation of the venous drainage of the brain has emerged as one of the most critical determinants of outcome following separation. Various surgical approaches have been reported.⁴¹

In managing the 5 ischiopagus twin pairs and 2 pygopagus twin pairs reported in this series, it has become apparent that these conjoined twins may also have involvement of the central nervous system. One pair of pygopagi had back-to-back fusion of the conus medullaris resulting in a wishbone configuration to the spinal cords (Fig. 6). One pair of ischiopagi had end-to-end fusion of the spinal cords while another had a fused dural sac. In cases such as these, careful consideration must be given to the sequence of separation as it may be preferable to open the dura and separate the neural elements before the bowel is opened. Division of neural tissue is based on anatomical factors as well as the preoperative neurological status of the children. A particularly important consideration in reconstruction is avoidance of a CSF leak, and various strategies have been described.^{42,43} An important observation is the fact that 9 of these 12 children (75%) had bony abnormalities of the spine such as hemivertebrae remote from the area of conjunction, putting them at risk for progressive spinal deformity and scoliosis.

Four of the asymmetrical cases reported early in this series had the parasite attached to the spine.³ The relationship between such cases and complex spinal dysraphism remains unclear, as the latter may also have elaborate appendages resembling vestigial limbs.

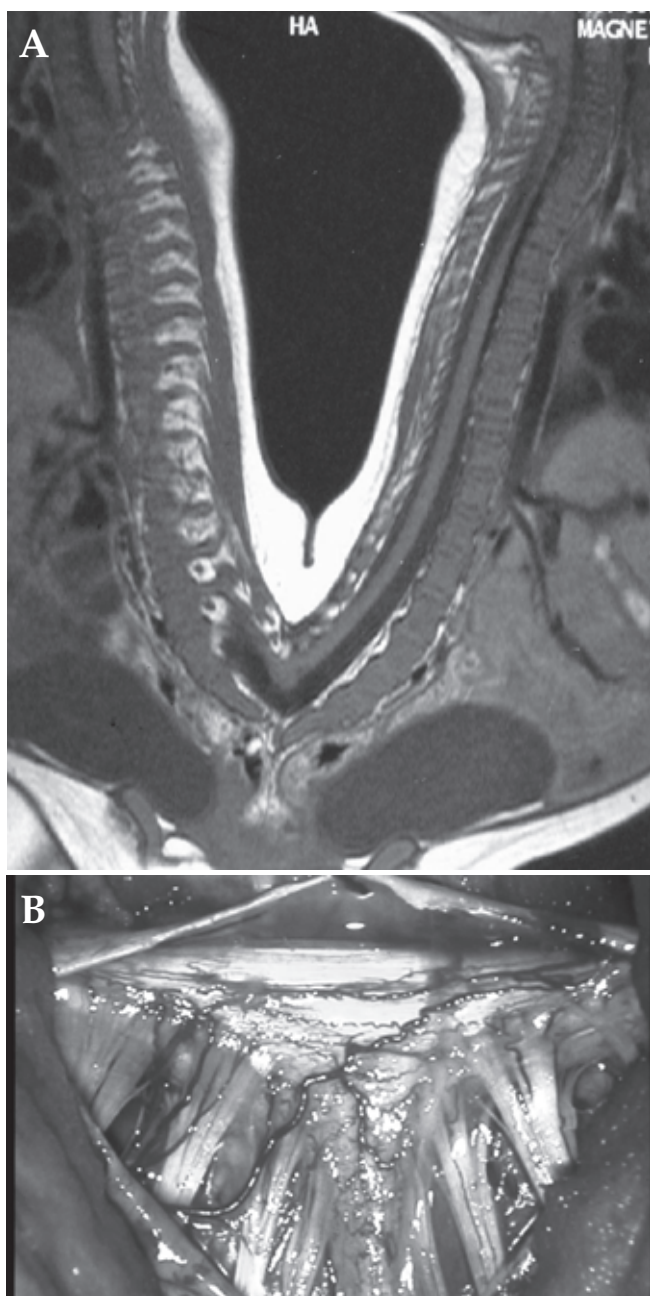


Fig. 6. Conjoined spinal cords in pygopagus twins. A. Preoperative sagittal T1 MRI scan showing the cords to unite distally. B. After removal of the caudal laminae and opening of the dura, the terminal spinal cords were found to be fused back-to-back with the shortened cauda equine nerve roots readily identified. As both children had virtually normal neurological function, the division was made strictly in the midline and there was no new postoperative deficit.⁴³

Musculoskeletal system

The orthopaedic surgeon is predominantly involved early in the separation of ischiopagus twins.^{44,45} Three-dimensional reconstruction CT scans of the pelvis are most helpful in

ascertaining the anatomical configuration of the pelvic ring and the possible junction of the vertebral columns. Diastasis of the pelvis is due to external rotation of the posterior segment. Posterior osteotomies rotate acetabula and the whole pelvis into normal alignment, which facilitates anterior abdominal wall closure and urogenital closure, and renders stability to the perineum. It also prevents delayed diastasis of the symphysis pubis, reconstructs pelvic anatomy and corrects acetabular retroversion to anteversion. The commonly encountered postoperative 30 - 50° flexion deformities of the hips usually resolve within 6 months. In 62% of ischiopagus twins there were associated spinal and cord and lower limb abnormalities. Correction of the pelvic abnormalities ensured that all 6 ischiopagus children became community walkers.⁴⁴

As mentioned above, children with hemivertebrae, asymmetrical or diminutive chest cavities and even those with caudal junction are prone to develop scoliosis. Progressive scoliosis in non-paralytic patients will not affect the hips – it is more a cosmetic deformity or affects respiratory capacity. Long-term follow-up is mandatory as rotational abnormalities, contractures and dislocation of the hips together with progressive scoliosis can occur. The importance of this problem is underscored by the data in Table III. Ischiopagus and pygopagus twins together represent only 19% of all symmetrical twins in this series, but comprise 45% of all long-term survivors.

Postoperative management

Cardiovascular and respiratory failure remain the most frequent causes of death in the immediate postoperative period. Further operations may be required for secondary wound closure or dehiscences and skin grafting. There is also hidden long-term morbidity and mortality. A number of infants died later from factors such as unresolved aspiration, bronchopneumonia, cerebral anoxia and malaria.

Conclusion

We have been extremely fortunate and privileged at Red Cross War Memorial Children's Hospital to have had referred – and to have managed – the largest number of conjoined twins in the world. With this experience, we have formulated what we believe is the optimal strategy in the approach to their surgical separation. This remains at all times a multidisciplinary team effort.

Prenatal diagnosis allows careful planning for delivery and for preoperative assessment. Emergency surgery may be required, but it is preferable to delay surgery to allow growth and the completion of investigations. Inevitably, the ultimate prognosis will depend on the state of the conjoined organs and the potential for successful separation. Tragically, in some cases separation will not be possible. Detailed preoperative



assessment is essential to determine the best surgical approach, reconstruction methods and ultimate outcome. Despite successful separation, some children are left crippled and disabled, requiring lifelong follow-up and care.

References

1. Mayer A. The Monstrous Birth: The Theory of Maternal Impression and Congenital Malformations. Proceedings of the 10th Annual History of Medicine Days. 2001; 48-52.
2. Bondeson J. The Biddenden maids: a curious chapter in the history of conjoined twins. *J R Soc Med* 1992; **85**: 217-221.
3. Cywes S, Millar AJW, Rode H, Brown RA. Conjoined twins – the Cape Town experience. *Pediatr Surg Int* 1997; **12**: 234-248.
4. Hall JG. Twinning. *Lancet* 2003; **362**: 735-743.
5. Viljoen DL, Nelson MM, Beighton P. The epidemiology of conjoined twinning in Southern Africa. *Clin Genet* 1983; **24**: 15-21.
6. MacKenzie TC, Crombleholme TM, Johnson MP. The natural history of prenatally diagnosed conjoined twins. *J Pediatr Surg* 2002; **37**: 303-309.
7. Spencer R. Theoretical and analytical embryology of conjoined twins: Part 1: embryogenesis. *Clin Anat* 2000; **13**: 36-53.
8. Spencer R. Theoretical and analytical embryology of conjoined twins: Part 2: adjustments to union. *Clin Anat* 2000; **13**: 97-120.
9. Kaufman MH. The embryology of conjoined twins. *Childs Nerv Syst* 2004; **20**: 508-525.
10. Spencer R. Anatomic description of conjoined twins: a plea for standardized terminology. *J Pediatr Surg* 1996; **31**: 941-944.
11. Magnus KG, Millar AJW, Sinclair-Smith CC, Rode H. Intrahepatic fetus in fetu: A case report and review of the literature. *J Pediatr Surg* 1999; **34**: 1861-1864.
12. Spencer R. Conjoined triplets and beyond. In: *Conjoined Developmental Malformations and Clinical Implications*. Baltimore: Johns Hopkins University Press; 2003: 376-391.
13. Spitz L. Surgery for conjoined twins. Hunterian Lecture. *Ann R Coll Surg Engl* 2003; **85**: 230-235.
14. Spitz L, Kiely EM. Conjoined twins. *JAMA* 2003; **289**: 1307-1310.
15. Cywes S, Davies MRQ, Rode H. Conjoined twins – the Red Cross War Memorial Children's Hospital experience. *S Afr J Surg* 1982; **20**: 105-118.
16. Spitz L, Kiely EM. Success rate for surgery of conjoined twins. *Lancet* 2000; **356**: 1965.
17. Raffensperger J. A philosophical approach to conjoined twins. *Pediatr Surg Int* 1997; **12**: 249-255.
18. Holye RM. Surgical separation of conjoined twins. *Surg Gynecol Obstet* 1990; **170**: 549-562.
19. O'Neill JA. Conjoined twins. In: O'Neill JA, Rowe M, Grosfeld JL, Fonkalsrud EW, Coran AG, eds. *Pediatric Surgery*. 5th ed. St Louis: Mosby; 1998: 1925-1938.
20. Lobe TE, Oldham KT, Richardson CJ. Successful separation of a conjoined biliary tract in a set of omphalopagus twins. *J Pediatr Surg* 1989; **24**: 930-932.
21. Filler RM. Conjoined twins and their separation. *Semin Perinatol* 1986; **10**: 82-91.
22. Pepper CK. Ethical and moral considerations in the separation of conjoined twins. *Birth Defects Original Article Series* 1967; **3**: 128-134.
23. Spitz L. *Med Sci Law* 2002; **42**: 284-287.
24. Gray CN, Nix NG, Wallace AJ. Thoracopagus twins: prenatal diagnosis. *Radiology* 1950; **54**: 398-.
25. Maggio M, Callen NA, Hamod KA, Sanders RC. The first-trimester ultrasonographic diagnosis of conjoined twins. *Am J Obstet Gynecol* 1985; **152**: 833-835.
26. Harper RG, Kenigsberg K, Sia GS, Horn D, Stern D, Bongiovi V. Xiphopagus conjoined twins: a 300-year review of the obstetric, morphopathologic, neonatal and surgical parameters. *Am J Obstet Gynecol* 1980; **137**: 617-629.
27. Kingston CA, McHugh K, Kumaradevan J, Kiely EM, Spitz L. Imaging in the preoperative assessment of conjoined twins. *Radiographics* 2001; **21**: 1187-1208.
28. Mann MD, Coutts JP, Kaschula ROC, Fraser CB, Fisher RM, Cywes S. The use of radionuclides in the investigation of conjoined twins. *J Nucl Med* 1984; **24**: 479-484.
29. Fitzpatrick C. Psychosocial study of a surviving conjoined twin. *Clin Child Psychol Psychiatr* 2000; **5**: 513-519.
30. Thomas JM, Lopez JT. Conjoined twins – the anaesthetic management of 15 sets from 1991 – 2002. *Pediatric Anesthesia* 2004; **14**: 117-129.
31. Diaz JH, Furman EB. Peri-operative management of conjoined twins. *Anesthesiology* 1987; **76**: 965-973.
32. Hisano K, Nakamura K, Okada M, Iwai S. Separation of conjoined twins using chest wall prosthesis. *J Pediatr Surg* 1989; **24**: 928-929.
33. Spitz L, Capps SNJ, Kiely EM. Xiphoomphaloischiopagus tripus conjoined twins: successful separation following abdominal wall expansion. *J Pediatr Surg* 1991; **26**: 26-29.
34. Ricketts RR, Zubowicz VN. Use of tissue expansion for separation and primary closure of thoracopagus twins. *Pediatr Surg Int* 1987; **2**: 365-368.
35. Andrews RE, McMahon CJ, Yates RWM. Echocardiographic assessment of conjoined twins. *Heart* 2006; **92**: 382-387.
36. Spitz L, Crabbe DCG, Kiely EM. Separation of thoraco-omphalopagus conjoined twins with complex hepato-biliary anatomy. *J Pediatr Surg* 1997; **32**: 787-789.
37. Wilcox DT, Quinn FM, Spitz L, Kiely EM, Ransley PG. Urological problems in conjoined twins. *Br J Urol* 1998; **81**: 905-910.
38. McLorie GA, Khoury AE, Alphin T. Ischiopagus twins: an outcome analysis of urological aspects of repair in 3 sets of twins. *J Urol* 1997; **157**: 650-653.
39. Hsu H-S, Duckett JW, Templeton JM, O'Neill JA. Experience with urogenital reconstruction of ischiopagus conjoined twins. *J Urol* 1995; **154**: 563-567.
40. Stone JL, Goodrich JT. The craniopagus malformation: classification and implications for surgical separation. *Brain* 2006; **129**: 1084-1095.
41. Peter JC, Fieggen AG, eds. Conjoined twins and the central nervous system. *Childs Nerv Syst* 2004; **20**: 503-651.
42. Fieggen AG, Dunn RN, Pitcher RD, Millar AJW, Rode H, Peter JC. Ischiopagus and pygopagus conjoined twins: neurosurgical considerations. *Childs Nerv Syst* 2004; **20**: 640-651.
43. Fieggen G, Millar AJW, Rode H, Ngiloi P, Andronikou S, Peter J. Spinal cord involvement in pygopagus conjoined twins: case report and review of the literature. *Childs Nerv Syst* 2003; **19**: 183-187.
44. Verrier MD, Hastings CJ, Hoffman EB. Posterior iliac osteotomy in ischiopagus tetrapagus twins. *J Pediatr Orthop* 2000; **20**: 807-811.
45. Albert MC, Drummond DS, O'Neill J, Watts H. The orthopedic management of conjoined twins: a review of 13 cases and report of 4 cases. *J Pediatr Orthop* 1992; **12**: 300-307.

Accepted 15 June 2006.