

# Intra-orbital knife blade foreign body: A case series

**S Ballim**,<sup>1</sup> MB ChB, Dip Opth (SA), FCOpth (SA); **B Gundry**,<sup>2</sup> MB ChB, FCOpth (SA);  
**S Mahomed**,<sup>3</sup> MB ChB, Dip HIV Man (SA), FCPHM (SA), MMed (PHM);  
**L Visser**,<sup>1</sup> MB ChB, MMed (Opth), FCS (Opth) (SA)

<sup>1</sup> Department of Ophthalmology, Nelson R Mandela School of Medicine, University of KwaZulu-Natal, Durban, South Africa

<sup>2</sup> Durban Retinal Associates, Entabeni Hospital, Durban, South Africa

<sup>3</sup> Medical Microbiology and Infection Prevention and Control, College of Health Sciences, University of KwaZulu-Natal, Durban, South Africa

**Corresponding author:** S Ballim (shaheerballim@gmail.com)

**Objective.** To describe cases of intra-orbital knife blade foreign body following stabs to the orbit, together with a novel technique for removal.

**Methods.** Retrospective case series of 3 patients.

**Results.** All 3 patients had knife blades embedded in the orbit as a result of assault. The blades assumed the same direction within the orbit with varying degrees of depth, one causing serious vascular injury. In 2 cases the globes were intact after foreign body removal, with good visual outcomes. The third patient required enucleation. Two of the 3 knife blades were removed using a 'double bone nibbler' technique. The third was embedded without a handle and required removal with minor manipulation of the globe.

**Conclusions.** Thorough investigation for vascular injury must be done before any attempted surgical removal. Visual outcomes can be good after removal of a knife blade foreign body. The double bone nibbler technique is promising for the controlled removal of embedded blades that are rigidly fixed.

*S Afr J Surg* 2013;51(4):134-137. DOI:10.7196/SAJS.1667



Trauma is one of the commonest causes of monocular blindness in developing countries.<sup>[1]</sup> Ocular injuries are most common in males and young adults. Case reports of penetrating orbital

injuries with foreign bodies show a predominance of left eye involvement,<sup>[2,3]</sup> suggestive of right-hand-dominant assailants. In a series of 179 cases of stabs to the head at Groote Schuur Hospital, Cape Town, South Africa, 9 injuries were isolated to the orbit.<sup>[4]</sup>

Occasionally the knife blade is retained in the orbit. We describe a series of 3 such injuries managed in eThekweni district, KwaZulu-Natal, South Africa, and a novel technique for removal of the knife blade.

## Case reports

### Case 1 (Fig. 1)

A 28-year-old man presented to a regional hospital casualty department. He had been stabbed in the left orbit 2 days previously. Further history was unavailable, as he was intoxicated. He complained of pain and poor vision in the left eye and dysphagia.

On examination, the patient had no cardiovascular instability. The Glasgow Coma Scale (GCS) was 15/15. Visual acuity (VA) in the left eye was counting fingers with no afferent pupillary defect (APD). He had full-thickness lacerations of the upper and lower lids, a conjunctival laceration, chemosis and a corneal abrasion. Fundal examination showed mild macular oedema and a pink, non-swollen disc with cup/disc ratio of 6:10. The intra-ocular pressure in the left eye was 18 mmHg. There was marked proptosis with eye movements 2/4 in all directions. The right eye and ocular adnexae were normal.

Radiological investigations showed a large radio-opaque foreign body suggestive of a knife blade tip embedded in the retrobulbar space of the left orbit, penetrating the orbital floor, traversing part of the maxillary sinus and abutting the soft palate. A computed tomography (CT) scan excluded involvement of the cranial fossae. A CT angiogram excluded major blood vessel involvement.

Removal of the blade and eyelid repair were done under general anaesthesia by a combined otorhinolaryngology and

ophthalmology team. The tip of the blade was palpated in the inferolateral orbit, identified and removed. No active bleeding was noted. The wound was then sutured and the eyelids were repaired.

Postoperatively the intra-ocular pressure remained normal and the macular oedema settled. Two months after surgery, eye movements had improved to 4/4 and vision was 6/6 unaided.

### Case 2 (Fig. 2)

A 24-year-old man was referred to the vascular surgeons from a district hospital following an isolated stab injury to the left orbit the day before. General examination revealed no cardiovascular instability, dysphagia or airway compromise, and the GCS was 15/15. There was a large knife in the left eye, embedded up to the handle. The blade abutted the globe with nasal dystopia. VA was counting fingers with no APD. Extra-ocular movements were 1/4 in all directions. Intra-ocular pressure was digitally elevated. Tonometry and fundoscopy were not possible.

Radiological investigations revealed the blade traversing the orbit and orbital floor, with the tip resting approximately 1 cm from the C1 vertebral body. An angiogram revealed spasm of the ophthalmic artery and excluded injury to vital blood vessels. A CT scan showed no intracranial involvement.

Forced ductions were 1/4 in all directions under general anaesthesia. Manual removal of the blade was unsuccessful, as the blade was rigidly fixed to the bony orbit. Successful removal of the blade was achieved using the 'double bone nibbler' technique described below. Thereafter forced ductions were 3/4 in all directions and proptosis improved markedly.

Postoperatively, the patient recovered well with a good cosmetic outcome, no proptosis, and VA of 6/6 in the left eye.

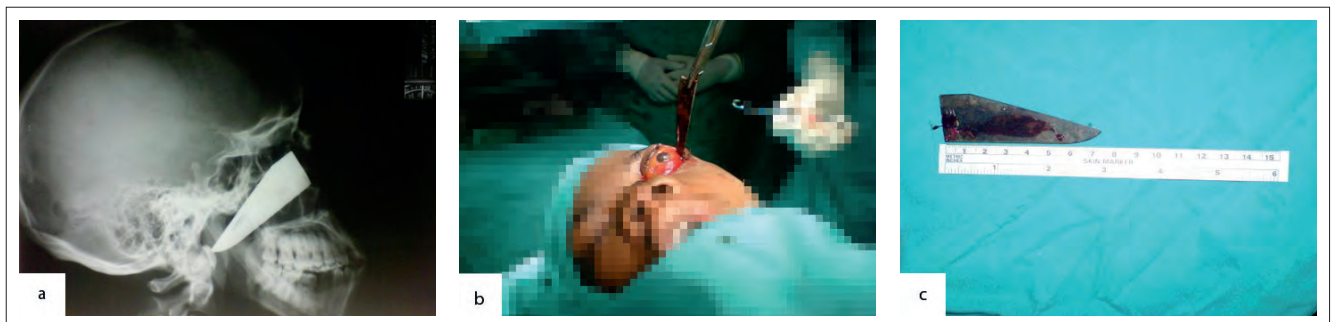


Fig. 1. Case 1. (a) Skull radiograph, (b) intra-operative removal of the knife blade, and (c) size of the knife blade.



Fig. 2. Case 2. (a) Clinical presentation, (b) skull radiograph, and (c) knife blade.

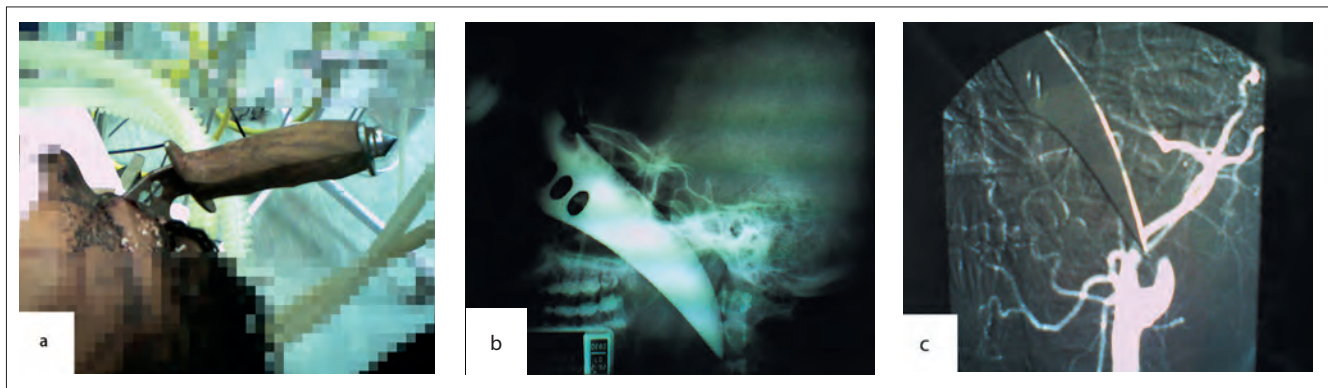


Fig. 3. Case 3. (a) Clinical presentation, (b) skull radiograph, and (c) angiogram.

### Case 3 (Fig. 3)

A 19-year-old man sustained a stab injury to the left orbit with involvement of a major blood vessel, warranting emergency vascular intervention. Owing to the severity of the injury and the urgent need to operate, he was assessed ophthalmologically for the first time in theatre, prior to anaesthesia. A large knife traversed the upper eyelid medially and was embedded in the left orbit. The left globe was transected with extensive vitreous and uveal prolapse.

Normal ocular anatomy was poorly identified. Vision was nil perception of light with relative APD. The right eye appeared normal.

Radiological investigations revealed a large knife blade embedded in the left orbit, extending into the neck. An angiogram revealed that the blade had penetrated the left internal carotid artery.

Intra-operative neck dissection revealed the knife tip within a thrombosed left internal carotid artery, which was then repaired. Attempts to remove the blade by the vascular surgeons were unsuccessful. The knife was then extracted in a controlled fashion with minimal to no further trauma to surrounding tissues, using the double bone nibbler technique. The embedded segment of the blade measured approximately 15 cm. Enucleation was performed thereafter.

The patient was managed by the vascular surgery department and subsequently lost to follow-up.

### The double bone nibbler technique

1. Exclude frontal bone/sinus fractures.
2. Approach the blade from the head end of the patient.
3. Place the first bone nibbler over the patient's intact forehead (Fig. 4(a), instrument in the left hand). This instrument should remain stationary throughout the removal and act as a fulcrum upon which the second instrument will lever. Any instrument with adequate thickness and rigidity can be used for this purpose.
4. The second bone nibbler is placed across the first at right angles (Fig. 4(a), instrument in the right hand).
5. This second bone nibbler is used to grip the exposed blade while aiming the tip of the instrument diagonally downward (Fig. 4(b)). This action allows the downward pressure applied to the handle to translate into an upward (extraction) force on the blade in a see-saw like manner.

6. After the downward force is applied, partial extraction of the blade will be achieved, with the tip of the bone nibbler now facing diagonally upwards (Fig. 4(c)). The blade can be released and re-gripped lower down the shaft to repeat the above process until it is no longer rigidly fixed.

### Discussion

All three patients had knife blades embedded in the left orbit as a result of assault. The blades all assumed the same direction within the orbit: inferiorly through the orbital floor towards the cervical spine, with varying degrees of depth, in one case causing serious vascular injury. Two of the 3 blades were removed using the double bone nibbler technique.

In intra-orbital injuries, the entrance wound may be small and inconspicuous, and even hidden in a fornix or by chemosis or subconjunctival haemorrhage, as in case 1. Depending on the velocity and sharpness of the instrument, the globe may be displaced and uninjured during the assault, further adding to the tendency to underestimate the severity of the injury.<sup>[5]</sup> Possible ocular and peri-ocular injuries include corneal lacerations, scleral lacerations, globe rupture, optic nerve avulsion, extra-ocular muscle damage, and damage to the lacrimal apparatus and lacrimal gland. Cranial nerve injury, cerebrovascular damage, brain cortex injury (frontal, temporal and even occipital lobes), intracranial haemorrhage, carotid-cavernous fistula and false aneurysm are also possible.

The direction of the trajectory determines whether the stab will fracture the orbit or extend through a foramen/fissure. The lateral wall of the orbit may direct an object across the vertical midline posteriorly and cause contralateral damage.<sup>[5,6]</sup> Our series demonstrates a common tendency for the weapon to be directed downwards through the orbital floor, possibly guided by the inferior orbital fissure, towards the cervical spine. This could also be explained by a presumed downward trajectory of attack from the assailant's flexed elbow position, making this phenomenon unique to knife blade foreign bodies resulting from assault. It is possible that in cases where the blade passes posteriorly through the apex, the immediate mortality is high owing to intracranial involvement, so these patients do not present to ophthalmology departments.

In cases where there is suspected vascular or cerebral injury, the knife blade should be removed under direct vision.<sup>[7,8]</sup> One technique described is tapping the clamp holding the blade with a surgical hammer. However, a concern with this technique is the

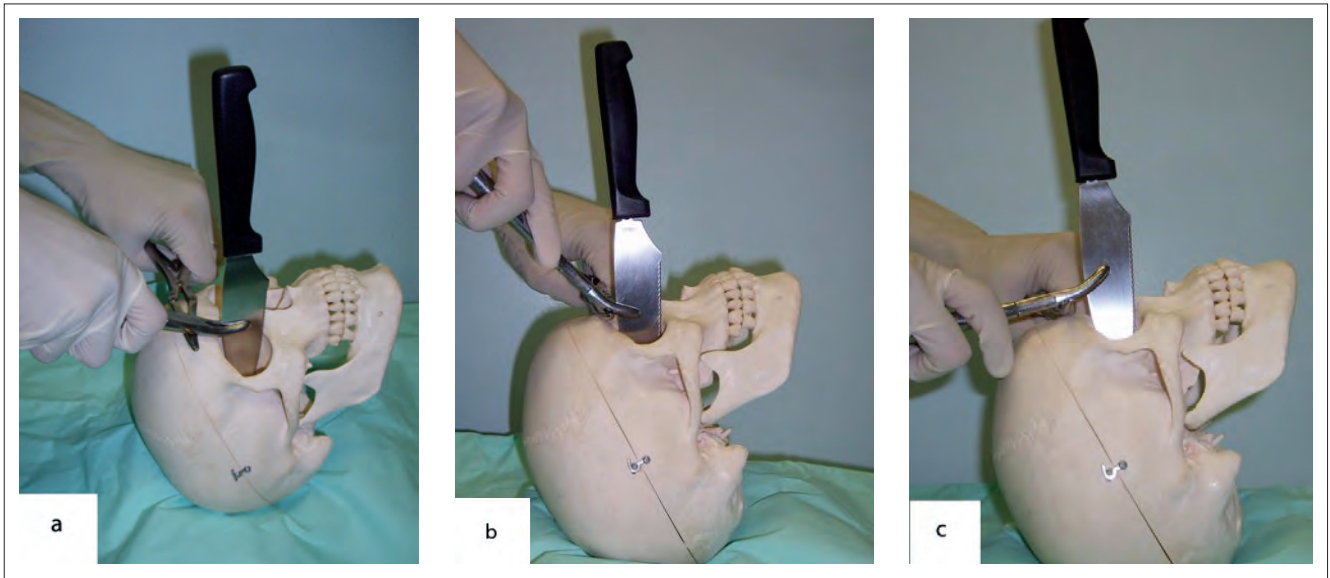


Fig. 4. The 'double bone nibbler' technique. (a) Placement of the first (left hand) and second (right hand) bone nibblers. (b) The second bone nibbler is used to grip the exposed blade while aiming the tip of the instrument diagonally downward. Downward pressure applied to the handle translates into an upward (extraction) force on the blade in a see-saw-like manner. (c) Partial extraction of the blade has been achieved, with the tip of the bone nibbler now facing diagonally upwards.

possibility that the knife may recoil or exit with an uncontrolled jerk.<sup>[9]</sup> Removal should be done by a combined team of neurosurgeons, vascular surgeons and ophthalmologists. Our double bone nibbler technique has not been described previously.

Two of the cases reported here had good visual outcomes, as have been described in other studies.<sup>[6,10,11]</sup> Injuries following the same intra-orbital course into the antrum as we have described in our cases have also been reported.<sup>[12]</sup>

## Conclusion

The 3 cases described reflect the violence prevalent in South Africa. Injuries of this sort are often sustained by members of the economically active population, placing unnecessary financial stress on families. Visual outcomes can vary after removal of a knife blade foreign body, from normal VA to loss of an eye. The double bone nibbler technique is promising for the controlled removal of embedded blades that are rigidly fixed.

## REFERENCES

- Whitcher JP, Srinivasan M, Upadhyay MP. Corneal blindness: A global perspective. *Bull World Health Organ* 2001;79(3):214-221. [http://www.who.int/bulletin/archives/79\(3\)214.pdf](http://www.who.int/bulletin/archives/79(3)214.pdf) (accessed 26 September 2013).
- Bulbulia A, Roux P, Asholi A, Bulbulia N. An unusual case of a penetrating wound of the orbit. *South African Optometrist* 2006;65(2):75-77.
- Louw JG. A knife blade in the orbit. *Suid Afrikaanse Tydskrif vir Geneeskunde* 1950;24:151-151.
- Exadaktylos AK, Stettbacher A, Bautz PC, Terries J. The value of protocol-driven CT scanning in stab wounds to the head. *Am J Emerg Med* 2002;20(4):295-297. [<http://dx.doi.org/10.1053/ajem.2002.33784>]
- De Villiers JC, Sevel D. Intracranial complications of transorbital stab wounds. *Br J Ophthalmol* 1975;59(1):52-56. [<http://dx.doi.org/10.1136/bjo.59.1.52>]
- MacEwen CJ, Fullarton G. A penetrating orbitocranial stab wound. *Br J Ophthalmol* 1986;70(2):147-149. [<http://dx.doi.org/10.1136/bjo.70.2.147>]
- Bullock R, van Dellen JR. Acute carotid-cavernous fistula with retained knife blade after transorbital stab wound. *Surg Neurol* 1985;24(5):555-558. [[http://dx.doi.org/10.1016/0090-3019\(85\)90273-3](http://dx.doi.org/10.1016/0090-3019(85)90273-3)]
- Okay O, Daglioglu E, Ozdol C, Uckun O, Dalgic A, Ergungor F. Orbitocerebral injury by a knife: Case report. *Neurocirugia (Astur)* 2009;20(5):467-479. [<http://dx.doi.org/10.4321/S1130-14732009000500005>]
- Chrcanovic BR, Souza LN, Freire-Maia B. Migration of tip knife blade through middle-third facial tissues. *Oral Maxillofac Surg* 2009;13(1):41-44. [<http://dx.doi.org/10.1007/s10006-009-0144-x>]
- Moehrlen U, Meuli M, Khan N, Gitzelmann CA. An orbitocranial knife injury without functional deficit in a child. *J Trauma* 2004;57(2):396-398. [<http://dx.doi.org/10.1097/01.TA.0000042170.26772.BB>]
- Lichter H, Snir M, Segal K, Yassur Y. Penetrating orbitocranial knife injury. *J Pediatr Ophthalmol Strabismus* 1999;36(1):44-46.
- Salinger S. Stab wound of orbit and antrum. *Arch Otolaryngol* 1948;47(4):503-504. [<http://dx.doi.org/10.1001/archotol.1948.00690030525015>]