

A tale of two appendices – an unexpected finding

M Heetun, V Stavrinides, B Keeler, D Phillips, A Taylor

Department of General Surgery, Milton Keynes Hospital NHS Foundation Trust, UK
M Heetun

Oxford Radcliffe Hospitals, Oxford, UK
V Stavrinides

Department of General Surgery, Milton Keynes Hospital NHS Foundation Trust, UK
B Keeler
D Phillips
A Taylor

Corresponding author: M Heetun (mheetun@gmail.com)

Anomalies of the appendix are uncommon and are usually discovered incidentally during surgery for appendicitis. We present a rare case of appendiceal duplication, which can have serious consequences if overlooked during an operation.

S Afr J Surg 2013;51(1):32-33. DOI:10.7196/SAJS.1217

Anomalies of the appendix are rare, and usually discovered by chance during surgery for appendicitis. We present a case of appendiceal duplication, which can have serious consequences if overlooked during an operation.

Case report

A 36-year-old man presented with a 1-day history of right iliac fossa pain. Clinical examination and raised inflammatory markers supported a diagnosis of acute appendicitis and the patient underwent an uncomplicated laparoscopic appendicectomy, although it was noted that the appendix appeared macroscopically normal at the time of the procedure. No other abnormalities were seen, and he was discharged 4 days later.

The patient presented again 7 days later with a 3-day history of lower abdominal pain, vomiting and abdominal distension. On examination, he was febrile, tachycardic and appeared unwell. Inflammatory markers were again elevated. A computed tomography scan revealed a small collection containing gas and fluid just inferior to the third part of the duodenum with a thin tubular structure extending from this collection and ending in the terminal ileum. This raised the possibility of Meckel's diverticulitis with a localised perforation at the tip. The patient underwent a second laparoscopy, which proved inconclusive, and a laparotomy was performed. This revealed a retro-caecal abscess surrounding a second (necrotic and friable) appendix arising from the base of the caecum, which was excised. The appendix stump from the first appendicectomy appeared unremarkable with an intact vicryl suture tied at its base. The patient's postoperative stay was prolonged due to ileus and pain, and he was discharged

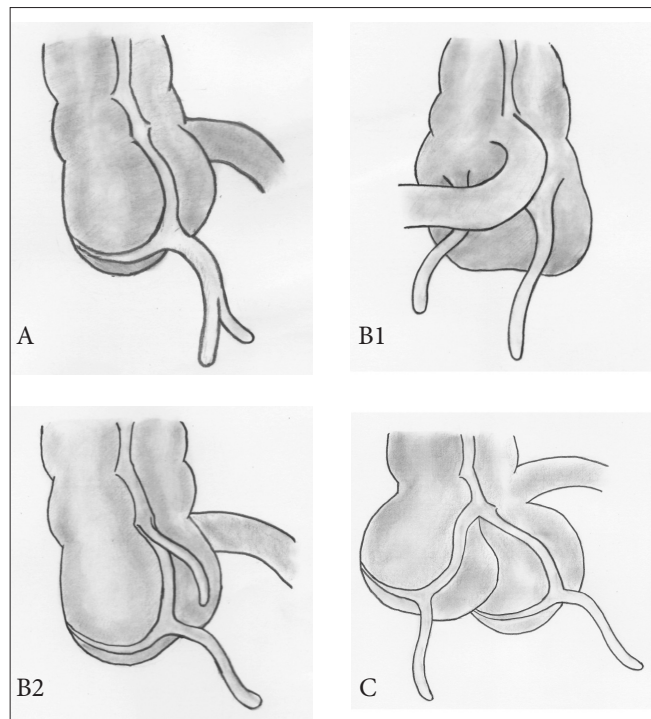


Fig. 1. Cave-Wallbridge classification. Type A: Single caecum with one normally localised appendix exhibiting partial duplication. Type B1: Two appendices located symmetrically on either side of the ileocaecal valve. Type B2: One appendix arises from the caecum at the usual site and the second branches at varying distances along the taenia from the first. Type C: Double caecum, each bearing its own appendix.

10 days later. Histological examination showed a gangrenous appendix, and review of the first resected specimen confirmed a histologically normal appendix.

Discussion

Although variation in the size and position of the appendix is common, duplication is rare and may be associated with other congenital abnormalities.^[1] Examination of 50 000 histological appendix specimens revealed just two instances of congenital duplication.^[2] The true incidence of duplicated appendix is estimated at 0.004%.^[1,3] This condition must be distinguished from a solitary diverticulum of the caecum, which is found on the inner aspect of the ileocaecal angle and does not contain lymphoid tissue histologically.⁴

The Cave-Wallbridge classification^[4] is based on reported cases and divides appendix duplications into three types (Fig. 1):

Type A: Single caecum with one normally localised appendix exhibiting partial duplication.

Type B: Single caecum with two completely separate appendices and divided into two further subgroups. **Type B1 ('bird-like type')**: two appendices located symmetrically on either side of the ileocaecal valve, resembling the normal arrangement in birds. **Type B2 ('taenia coli' type)**: one appendix arises from the caecum at the

usual site, and the second branches at varying distances along the lines of the taenia from the first.

Type C: Double caecum, each bearing its own appendix.

Our case was type B2, the most frequently encountered duplication.

Although duplicate appendix is rare, missing a case may have serious and even life-threatening complications for the patient. In the case described, the patient experienced significant morbidity in terms of readmission to hospital, further surgical procedures and prolonged hospital stay. Surgeons performing appendicectomies should be aware of the possibility of a duplicate appendix, particularly in the context of an unwell patient with clinical features highly suggestive of acute appendicitis, but with a macroscopically normal appendix at the time of operation. The caecum should therefore always be inspected carefully to exclude appendiceal abnormalities.

REFERENCES

1. Bluett MK, Halter SA, Salhany KE, et al. Duplication of the vermiform appendix mimicking adenocarcinoma of the colon. *Arch Surg* 1987;122:817-820.
2. Collins DC. A study of 50,000 specimens of human vermiform appendix. *Surg Gynecol Obstet* 1955;101:437-445.
3. Fallbericht DW, Hentshel LM. Double appendix: Report of a case and review of the literature. *Excerpta Med (Surgery)* 1969;40:565-567.
4. Wallbridge PH. Double appendix. *Br J Surg* 1963;50(221):346. [<http://dx.doi.org/10.1002/bjs.18005022124>]

