

# Predisposing factors for developing gastric volvulus and the role of imaging

A O Krim, S Andronikou, G Rubin

Department of Radiology, Faculty of Health Sciences, University of the Witwatersrand, Johannesburg

A O Krim, MB ChB

S Andronikou, MB ChB, FCRad, FRCR (Lond), PhD

G Rubin, MB BCh, FCRad (Diag) (SA), MMed

Corresponding author: A O Krim ([krim6224@yahoo.com](mailto:krim6224@yahoo.com))

Two cases of gastric volvulus are presented to highlight the predisposing factors, mechanism and different types of volvulus, and the role of imaging in making the diagnosis.

Eventration of the diaphragm and hiatus hernia are precipitating factors for developing organo-axial and mesentero-axial volvulus. Imaging is key to making the diagnosis and distinguishing the types of volvulus in order to decide on management.

*S Afr J Surg* 2012;50(4):131-133. DOI:10.7196/SAJS.1218

Eventration of the diaphragm and hiatus hernia are factors that can precipitate development of gastric volvulus. Radiological features can clarify the diagnosis and distinguish between the two types of gastric volvulus. We present 2 cases of different types of gastric volvulus and highlight the predisposing factors.

## Case reports

### Case 1

A 55-year-old man with a history of chronic obstructive airways disease, ischaemic heart disease and a hiatus hernia diagnosed 3 years previously presented with shortness of breath, cough, epigastric pain and left upper quadrant pain.

Chest examination revealed decreased breath sounds at the left base. Abdominal examination elicited epigastric tenderness. A chest radiograph (Fig. 1) demonstrated elevation of the left hemidiaphragm, which prompted fluoroscopic evaluation of the diaphragm. The fluoroscopic 'sniff test' demonstrated paradoxical movement of the left hemidiaphragm, in keeping with diaphragmatic eventration.

A barium upper gastrointestinal tract study demonstrated a sliding hiatus hernia, mesentero-axial gastric volvulus and no outlet obstruction (Fig. 2a and b), accounting for the presenting symptoms. The patient was referred for decompression of the stomach and surgery to address the underlying cause of the gastric volvulus.

### Case 2

A 44-year-old man presented with severe epigastric pain, melaena, fatigue, weakness and significant weight loss. On the examination he was pale and had epigastric tenderness. Digital rectal examination revealed black stool. Haematological and biochemical investigations showed a low haemoglobin concentration and a slightly increased white cell count.

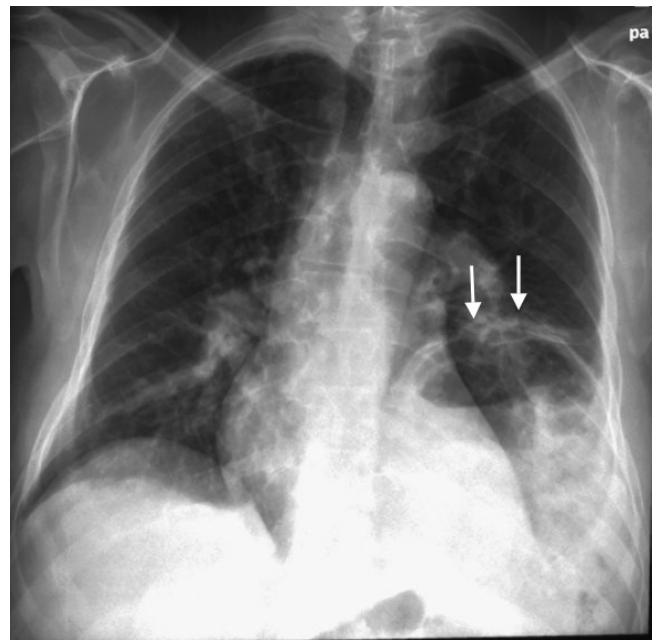


Fig. 1. Frontal chest radiograph demonstrating an elevated left hemidiaphragm (arrows) in keeping with eventration.

Upper gastrointestinal tract endoscopy showed pan-gastritis with multiple ulcerations involving the lesser curvature. A barium upper gastrointestinal tract study demonstrated a rolling (para-oesophageal) hiatus hernia with organo-axial gastric volvulus and no outlet obstruction (Fig. 3).

A laparoscopic Nissen fundoplication was performed, with subsequent admission to the intensive care unit. The patient suffered a pulmonary embolism during his stay in the ICU but recovered fully and was discharged from the hospital in good

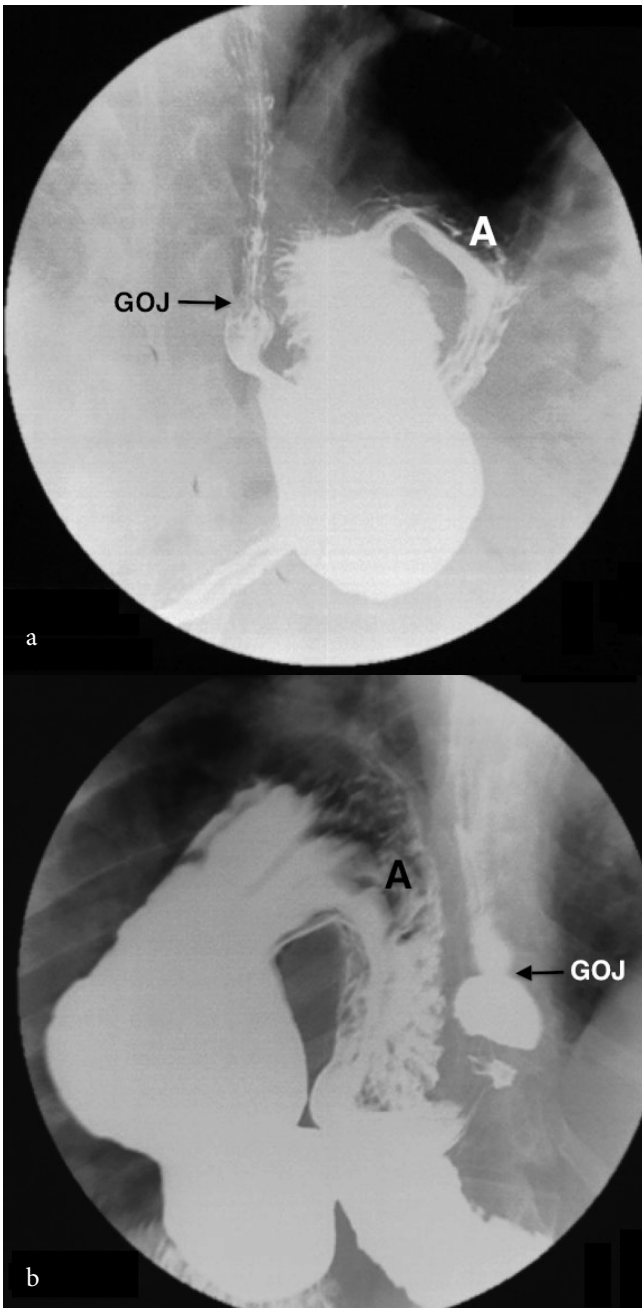


Fig. 2 (a and b). Barium upper gastrointestinal tract study demonstrating mesentero-axial volvulus and hiatus hernia. The antrum (A) characteristically lies above the gastro-oesophageal junction (GOJ, arrow).

condition; a barium study confirmed that the operation had been successful (Fig. 4).

## Discussion

Eventration of the diaphragm is defined as abnormal elevation of an intact diaphragm. It is usually a congenital abnormality caused by a developmental defect of the diaphragm musculature, the so-called congenital eventration.<sup>1</sup> Acquired eventration may occur due to trauma to the phrenic nerve resulting from birth injury, external trauma, neoplastic or inflammatory processes or operative injury.<sup>2</sup>

The abnormally wide subdiaphragmatic space resulting from diaphragmatic eventration creates the potential for pathological

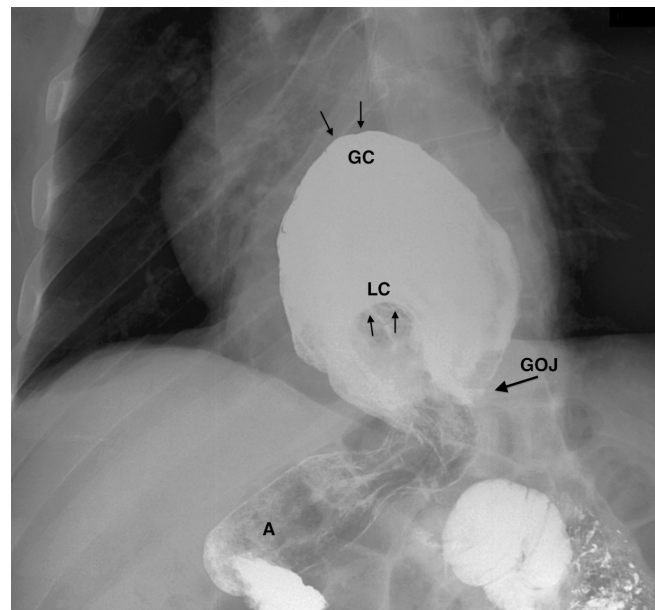


Fig. 3. Barium upper gastrointestinal tract study demonstrating organo-axial volvulus and para-oesophageal hiatus hernia. The greater curvature (GC, arrows) is superior to the lesser curvature (LC, arrows). The gastro-oesophageal junction (GOJ, arrow) and the antrum (A) are in the normal position.

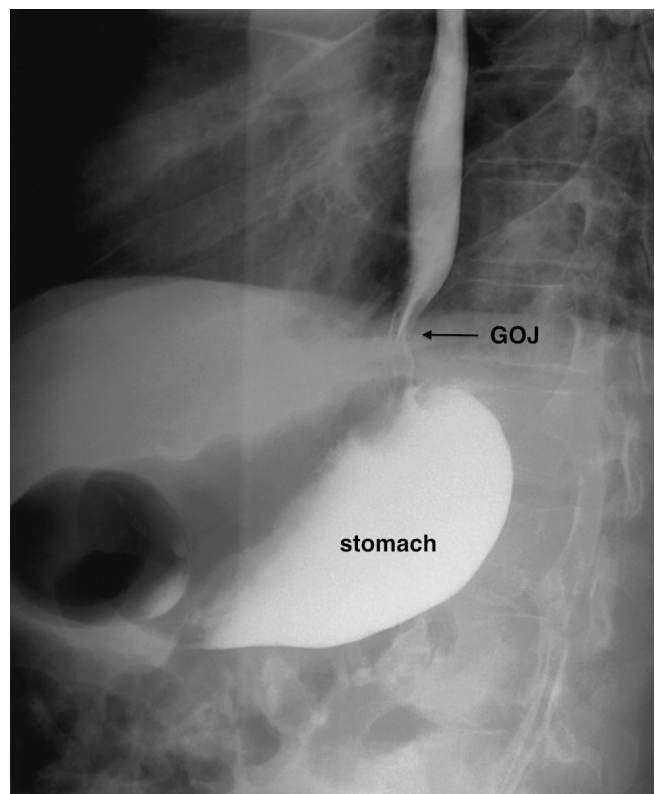


Fig. 4. Barium upper gastrointestinal tract study in case 2, confirming the successful surgery, with the gastro-oesophageal junction (GOJ, arrow) and the stomach in the normal position.

rotation of the stomach around itself, known as gastric volvulus.<sup>1</sup> Gastric volvulus is a rare condition that presents with epigastric pain. There are different types of gastric volvulus. Organo-axial volvulus is the most common, while mesentero-axial volvulus

is less common and combined organo-axial and mesentero-axial volvulus the least common type. Most cases of gastric volvulus occur in association with either eventration of the left hemidiaphragm (as in case 1) or a hiatus hernia (as in cases 1 and 2).<sup>1,2</sup>

Organo-axial volvulus is defined as rotation of the stomach around its longitudinal axis, which extends from the gastro-oesophageal junction to the pylorus (Fig 5, a).<sup>3,4</sup> In adults, organo-axial volvulus most commonly occurs either after trauma or in association with a para-oesophageal hernia, as in our second case, which allows the stomach to move abnormally around its long axis. The diagnostic feature on barium studies is demonstration of the greater curvature superior to the lesser curvature.<sup>3</sup>

Mesentero-axial volvulus (as in our first patient) is defined as rotation of stomach around its short axis, which extends from the lesser curvature to the greater curvature. This axis makes a right angle with the longitudinal axis. When the stomach rotates along the short axis there is resultant displacement of the antrum above the gastro-oesophageal junction, which is a diagnostic feature on barium studies (Fig. 5, b).<sup>3,4</sup>

Gastric volvulus may be complete, presenting with acute abdominal symptoms such as an acute abdomen. The clinical triad of complete volvulus may be present – a sudden onset of epigastric pain, unproductive retching, and inability to pass a nasogastric tube.<sup>4,5</sup>

Chronic nonspecific upper abdominal pain, as was experienced by our patients, and respiratory symptoms may be the presenting features when gastric volvulus is associated with diaphragmatic eventration and para-oesophageal hernia, representing partial volvulus. Our second patient additionally presented with features of gastric ulceration as a complication of the volvulus.

Diagnosis of gastric volvulus is not easy and is mainly based on barium studies and plain radiographs; computed tomography is also used in diagnosis and for pre-operative evaluation (as in our case 2), while magnetic resonance imaging has also been used for diagnosis in some patients.

Treatment of gastric volvulus depends on the presentation. Acute presentation is treated as a surgical emergency to prevent complications such as perforation, peritonitis, strangulation, shock and death. Patients with chronic presentation require nasogastric tube decompression of the stomach and elective treatment of any underlying cause, such as hernia repair.

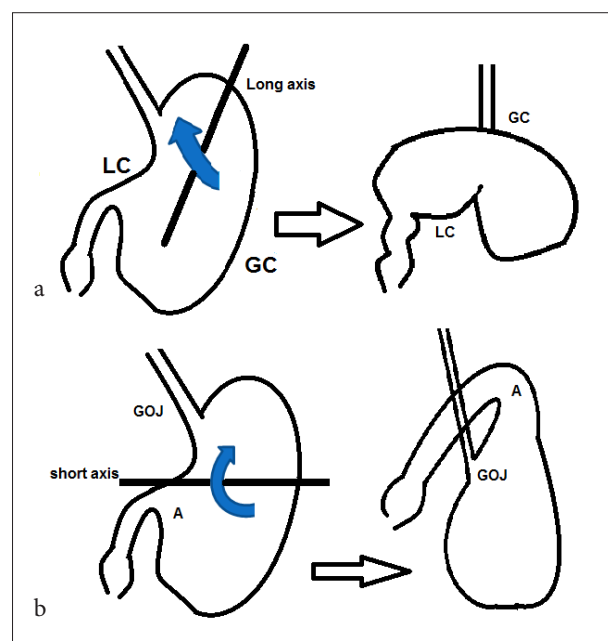


Fig. 5. Schematic representation of (a) organo-axial volvulus and (b) mesentero-axial volvulus, demonstrating the short and long axes as well as rotation of the stomach, respectively. GOJ = gastro-oesophageal junction; GC = greater curvature; LC = lesser curvature; A = antrum.

## Conclusion

Radiological imaging plays a significant role in diagnosis of gastric volvulus. Recognition of the typical types of gastric volvulus will result in prompt management of patients to relieve both acute and chronic presenting symptoms.

## REFERENCES

1. Shah NN, Mohsin M, Khursheed SQ. Eventration of diaphragm with gastric volvulus: a case report. *Cases Journal* 2008;1:404. [http://dx.doi.org/10.1186%2F1757-1626-1-404]
2. Ghatak S. Gastric volvulus with diaphragmatic hernia presenting with unexplained weight loss: a delayed diagnosis: a case report. *Singapore Med J* 2011;52:e4-e6.
3. Peterson CM, Anderson JS, Hara AK, Carezza JW, Menias CM. Volvulus of the gastrointestinal tract: Appearances at multimodality imaging. *Radiographics* 2009;29:1281-1293. [http://dx.doi.org/10.1148%2Frg.295095011]
4. Shivanand G, Seema S, Srivastava DN. Gastric volvulus: Acute and chronic presentation. *Clinical Imaging* 2003;27:265-268. [http://dx.doi.org/10.1016%2FS0899-7071%2802%2900549-1]
5. Kotobi H, Auber F, Otta E. Acute mesenteroaxial gastric volvulus and congenital diaphragmatic hernia. *Pediatr Surg Int* 2005;21:674-676. [http://dx.doi.org/10.1007%2Fs00383-005-1437-2]