

Beware the left-sided gallbladder

S Alharthi, MB ChB, FCS (SA)

M Bernon, MB ChB, FCS (SA)

J E J Krige, MB ChB, MSc, FACS, FRCS, FCS (SA)

Department of Surgery, Faculty of Health Sciences, University of Cape Town, and Surgical Gastroenterology Unit, Grootte Schuur Hospital, Observatory, Cape Town

A left-sided gallbladder is a rare biliary anomaly with a prevalence of 0.2%. Its identification is important because of the numerous and potentially hazardous associated biliary and vascular anomalies that may be encountered during surgery.

S Afr J Surg 2012;50(3):88-89. DOI:10.7196/SAJS.1301

A left-sided gallbladder (LSGB) is a rare biliary anomaly with a prevalence of 0.2%, and is defined as a gallbladder located to the left of the ligamentum teres and the falciform ligament.¹ LSGB was first described by Hochstetter in 1886, and its identification is important because of the numerous and potentially hazardous associated biliary and vascular anomalies that may be encountered during surgery.²

Case report

A 55-year-old woman presented with a 3-month history of colicky epigastric pain that had become progressively worse and radiated to her back and right flank. There was no loss of weight, fever, rigors or jaundice. Clinical examination was unremarkable apart from an increased body mass index. A full blood count and liver function tests were normal. An abdominal ultrasound scan showed multiple stones in the gallbladder with no evidence of acute cholecystitis and a common bile duct (CBD) diameter of 4 mm. Owing to the atypical nature of her pain, a computed tomography (CT) scan was requested which showed a left-sided gallbladder containing gallstones (Fig. 1). At operation and after insertion of a 10 mm umbilical camera port, the gallbladder was found to be attached to the inferior surface of segment 3 and to the left of a well-formed falciform ligament (Fig. 2). No situs inversus was present and the rest of the abdominal organs were normally positioned. A 10 mm working port was inserted below the xiphoid process and directed to the left of the falciform ligament, and two lateral 5 mm subcostal ports were placed in the left mid-clavicular and left anterior axillary lines in mirror-image positions to normal port placement. The surgeon and camera assistant operated from the patient's left side. An intra-operative cholangiogram confirmed an intact extrahepatic biliary system with an anomalous insertion of the segment 6 duct into the left hepatic duct (Fig. 3). The cholecystectomy was uncomplicated and the patient was discharged the next day. Histological examination showed a chronically inflamed gallbladder with gallstones.

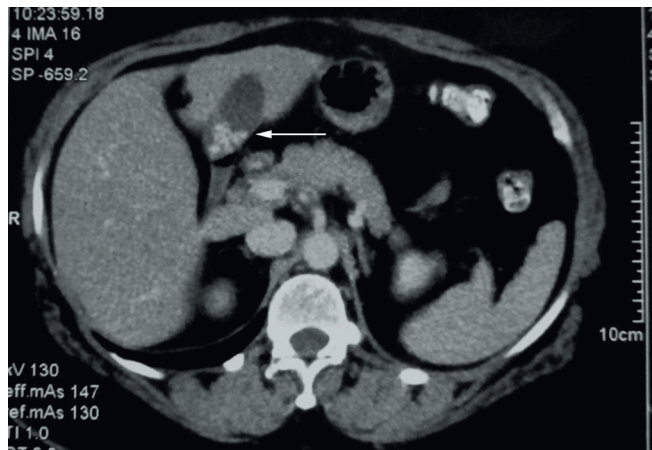

Fig. 1. CT scan showing gallstones (arrow) in a left-sided gallbladder.

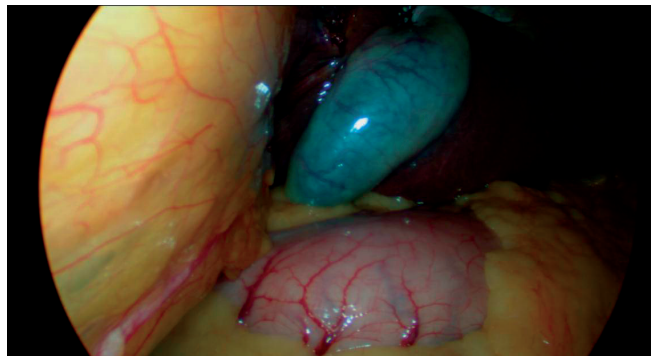


Fig. 2. Gallbladder located to the left of the falciform ligament on the undersurface of segment 3.

Discussion

Despite common variations in biliary, portal venous and hepatic arterial anatomy, congenital anomalies of gallbladder position are rare in the absence of total situs inversus or liver-only transposition.² Two types of gallbladder malposition, medioposition and sinistroposition, are described.¹ In medioposition, the gallbladder is displaced medially to the base of the quadrate lobe (segment 4) but remains to the right of the round ligament. In sinistroposition, the gallbladder is located at the base of segment 3 to the left of the round ligament. This variant is a true left-sided gallbladder in which the cystic artery always crosses in front of the CBD from right to left. The cystic duct may join the left or the right side of the common hepatic duct or may join the left hepatic duct directly.

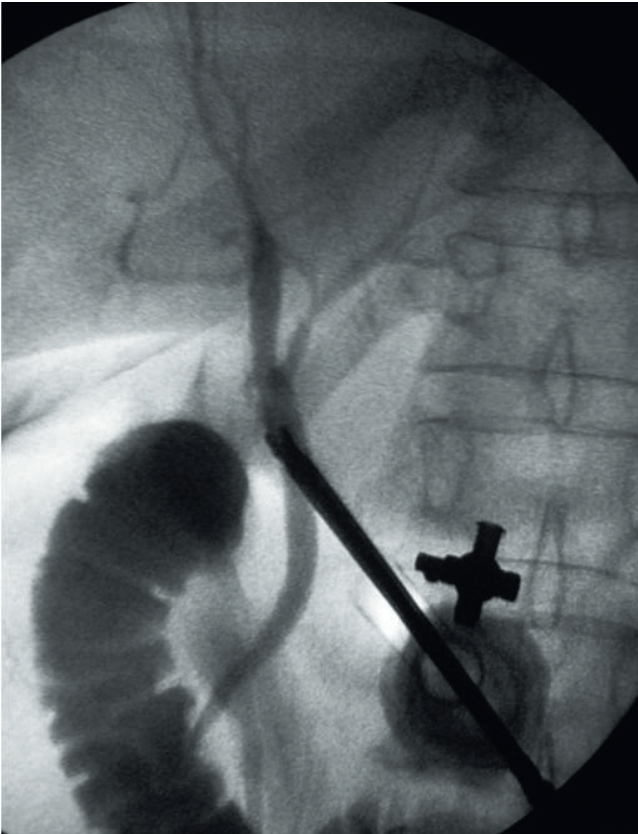


Fig. 3. Intra-operative cholangiogram showing an anomalous segment 6 insertion into the left hepatic duct.

An LSGB may occur either as a single anomaly or in association with one or more congenital abnormalities, including complete or partial situs inversus, hypoplastic bile ducts, a bile duct confluence

in the umbilical fissure or an anomalous pancreaticobiliary junction.³ An LSGB may also be associated with other significant liver and vascular anomalies including a preduodenal portal vein, azygous continuation of the inferior vena cava, anomalous intrahepatic branching of the portal vein, absence of the quadrate lobe or an accessory liver.¹⁻³ These complex and unusual alterations in anatomy are of considerable relevance and importance during biliary surgery for complicated cholelithiasis or hepatolithiasis, liver resection for left lobe tumours, and live donor liver transplantation.¹⁻³

Recent data indicate that routine ultrasonography in patients with gallstone disease may fail to identify LSGB disease, which was the situation in our patient.

Laparoscopic cholecystectomy is the treatment of choice for a left-sided gallbladder, with minor technique modifications in patients with total situs inversus or liver-only transposition, in whom the biliary anatomy is a mirror image of normality. In the sinistroposition illustrated in our patient, the surgeon needs to be mindful of the spectrum of biliary and vascular anomalies that may occur and should exercise great care, with a low threshold for conversion to open surgery, especially if the anatomy is unclear or distorted by inflammation.¹⁻⁵

REFERENCES

1. Hsu SL, Chen TY, Huang TL, et al. Left-sided gallbladder: its clinical significance and imaging presentations. *World J Gastroenterol* 2007;13:6404-64049.
2. Idu M, Jakimowicz J, Iuppa A, Cuschieri A. Hepatobiliary anatomy in patients with transposition of the gallbladder: implications for safe laparoscopic cholecystectomy. *Br J Surg* 1996;83:1442-1443.
3. Wong LS, Rusby J, Isamil T. Left-sided gallbladder: a diagnostic and surgical challenge. *Australian and New Zealand Journal of Surgery* 2001;71:557-558.
4. Nagai M, Kubota K, Kawasaki S, Takayama T, Bandai Y, Makuuchi M. Are left-sided gallbladders really located on the left side? *Ann Surg* 1997;225:274-280.
5. Maetani Y, Itoh K, Kojima N, et al. Portal vein anomaly associated with deviation of the ligamentum teres to the right and malposition of the gallbladder. *Radiology* 1998;207:723-728.