

Jejuno-jejunal intussusception secondary to small-bowel lipomatosis: A case report

V. S. Karthikeyan, M.B.B.S., M.S. (General Surgery)

Department of Surgery, Jawaharlal Institute of Postgraduate Medical Education and Research, Puducherry, India

P. Dhanasekar, M.B.B.S., M.S. (General Surgery), D.N.B. (General Surgery)

Department of Surgical Oncology, Tata Memorial Hospitals, Mumbai, India

Sarath Chandra Sistla, M.B.B.S., M.S. (General Surgery)

Manwar S. Ali, M.B.B.S., M.S. (General Surgery)

G. Balasubramaniam, M.B.B.S., M.S. (General Surgery)

N. Rajkumar, M.B.B.S., M.S. (General Surgery)

Department of Surgery, Jawaharlal Institute of Postgraduate Medical Education and Research, Puducherry, India

Summary

Intussusception is usually a disease of children aged between 6 months and 4 years, in which a part of a bowel telescopes into another part of the bowel. We report a case in a 60-year-old man who required resection and anastomosis. Although intussusception is unusual in adults, awareness of the differences in symptoms and causes should be borne in mind when adults present with intestinal obstruction.

S Afr J Surg 2012;50(2):43-44.

Intussusception is usually a disease of children aged between 6 months and 4 years, in which a part of a bowel (intussusceptum) telescopes into another part of the bowel (intussusciens). In this age group, there is usually no lead point, and the cause is thought to be a viral infection that results in either enlarged ileocolic lymph nodes or bowel-wall inflammation.¹ Entero-enteric intussusceptions are rare in children. Intussusceptions are much less common in adults, who account for 10% of all cases; unlike in children, a lead point is usually found. In adults intussusceptions may be ileocolic, colocolic, entero-enteric or jejuno-gastric, and there is no anatomical predilection.¹

Lipomas are the most common benign tumours of the intestines. Symptoms occur in less than one-third of affected patients, and are most often experienced when the lipoma is more than 2 cm in size. Most intestinal lipomas are solitary and submucosal in location. Intestinal lipomatosis is a very rare condition. Lipomatosis of the intestine causing intussusception and intestinal obstruction is even rarer.²

We present a case of jejuno-jejunal intussusception in a 60-year-old man who presented with acute intestinal obstruction.

Case report

A 60-year-old man presented to surgical casualty with complaints of abdominal pain, vomiting and distension of the abdomen. The abdominal pain had been of acute onset, and was a generalised dull ache with no radiation. Vomiting had then ensued; the vomitus was bilious with no haematemesis. The symptoms were of 3 days'

duration, and the patient had not passed stools or flatus for the past 2 days. He did not have any history of similar episodes in the past, had not undergone any previous abdominal surgery, and had no co-morbid illnesses.

On examination the patient was moderately built and mildly dehydrated. The vital signs were stable. Examination of the abdomen showed generalised distension, with all quadrants moving well and no visible peristaltic waves. Palpation revealed diffuse guarding and generalised tenderness. The abdomen was resonant on percussion. Bowel sounds were sluggish. Digital rectal examination showed liquid staining of the glove finger.

After basic blood investigations, the results of which were normal, the patient was sent for an abdominal radiograph. This revealed multiple air/fluid levels involving small-bowel loops in the left upper quadrant of the abdomen. An ultrasound scan of the abdomen showed jejuno-jejunal intussusception with a sandwich sign, pseudo-kidney sign, doughnut sign and target sign.

We decided on a trial of conservative management, and the patient was kept *nil per os* with continuous Ryle's tube aspiration and intravenous fluid therapy. After 12 hours there was no clinical improvement, so an exploratory laparotomy was done.

The small bowel was found to be dilated and studded with multiple sub-serosal lipomas of varying sizes (Fig. 1). There was an intussuscepted mass about 1.5 m distal to the duodenojejunal flexure. The intestine 30 cm proximal to the mass was pregangrenous. A trial of reduction by milking failed, so resection and anastomosis of the mass and the gangrenous bowel segment was done (Fig. 2). The patient had an uneventful postoperative course and was discharged on the 10th postoperative day.

Discussion

Diffuse lipomatous involvement of the gastrointestinal tract is a rare condition, with less than a dozen reported cases.³ Intussusception in adulthood is unusual,⁴ with an incidence of approximately 2 - 3 cases per 1 000 000 per year.⁵ The clinical picture of intussusception in adults is subtle and the diagnosis is therefore elusive.^{1,2,4} Intussusceptions account for 1% of all adult intestinal obstructions.⁴ Neoplasms are the most frequent causes of adult intussusception. The likelihood of malignancy varies according to the site of the intus-

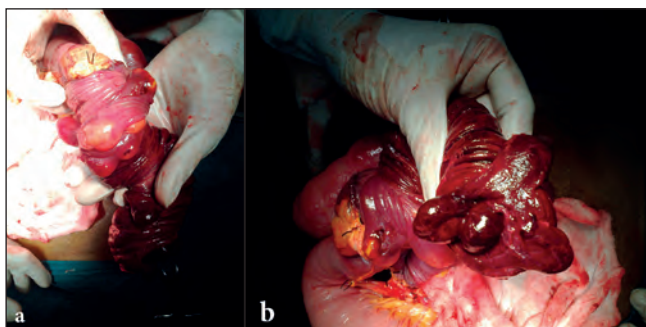


Fig. 1. (a) Intra-operative photograph showing the gangrenous small-bowel segment with lipomatosis; (b) a closer view of the gangrenous small bowel.

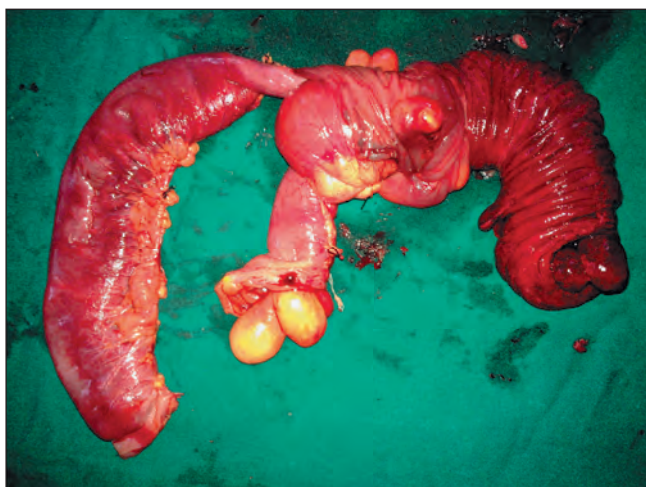

Fig. 2. Resected segment of jejunum with intestinal lipomatosis.

susception, with colocolonic intussusception reported as having a neoplasm as lead point in 69% of cases, and 70% of cases being due to malignant disease.⁴ Benign lesions acting as lead points of intussusceptions are most commonly pedunculated, such as adenomatous polyps in the colon, Peutz-Jeghers polyps in the small bowel, and lipomas. Less common causes include postoperative factors (adhesions, suture lines, intestinal tubes) and Meckel's diverticulum, coeliac sprue, HIV infection and intramural haematoma.^{6,7}

Gastrointestinal lipomas are rare benign tumours, and intussusception due to a gastrointestinal lipoma is infrequent.⁴ They are the second most common benign small-bowel tumours, leiomyomas being the most frequent,⁵ and are usually located in the ileum (50%), with the jejunum the least common site. They

are most common in the 6th - 7th decades of life and in females.⁵ Adult intussusception differs from the childhood type with regard to symptoms as well as causes. In contrast to the acute presentation of childhood intussusception, that in adults usually has a subacute or chronic onset. Fewer than 20% of cases present acutely with complete bowel obstruction.⁴

Imaging studies aid the diagnostic process. Plain abdominal films are nonspecific and commonly demonstrate the presence of multiple air/fluid levels suggestive of mechanical obstruction.⁴ Ultrasound is often the first modality to be recruited and is a very useful bedside diagnostic modality.⁸ It may evaluate acute abdominal complaints and bowel obstruction in both children and adults in the emergency room. Intussusception can be diagnosed based on the findings of the 'target' sign, the 'doughnut' sign when the transducer is orientated transversely to the intussusception, the 'trident' sign when the transducer is positioned longitudinally, and the 'pseudo-kidney' sign when it is visualised obliquely.⁹⁻¹¹ We used ultrasound only, but barium meal examination and computed tomography are useful in the elective setting.²

Treatment of adult intussusception consists of segmental resection and primary restoration of the continuity of the gastrointestinal tract, given the high incidence of structural causes and the 6 - 30% prevalence of malignant lesions in adults.⁴ All surgeons agree that reduction should not be attempted if there are signs of irreversible bowel ischaemia or inflammation, or when malignancy is suspected.^{4,6}

REFERENCES

1. Ross GJ, Amilineni V. Case 26: Jejunojejunal intussusception secondary to a lipoma. *Radiology* 2000;216:727-730.
2. Hong C-Y, Tzeng W-S, Chang Y-K, Wu R-H, Hou C-C. Jejunojejunal intussusception due to intestinal polypoid lipomatosis: a case report. *Chin J Radiol* 2006;31:255-259.
3. Yen AC, Saremi F. Gastrointestinal lipomatosis. *Internet Journal of Radiology* 2006;5(1).
4. Manouras A, Lagoudianakis EE, Dardamanis D, et al. Lipoma induced jejunojejunal intussusception. *World J Gastroenterol* 2007;13:3641-3644.
5. Brayton D, Norris WJ. Intussusception in adults. *Am J Surg* 1954;88:32-43.
6. Eisen LK, Cunningham JD, Aufses AH Jr. Intussusception in adults: institutional review. *J Am Coll Surg* 1999;188:390-395.
7. Azar T, Berger DL. Adult intussusception. *Ann Surg* 1997;226:134-138.
8. Chen KC, Hung TY, Wang TH, Wang TL, Chong CF. Rapid diagnosis of jejunojejunal intussusception by an emergency physician-performed bedside ultrasound. *Am J Emerg Med* 2010;28:117.e5-7.
9. Boyle MJ, Arkell LJ, Williams JT. Ultrasonographic diagnosis of adult intussusception. *Am J Gastroenterol* 1993;88:617-618.
10. Alessi V, Salerno G. The 'hay-fork' sign in the ultrasonographic diagnosis of intussusception. *Gastrointest Radiol* 1985;10:177-179.
11. Anderson DR. The pseudokidney sign. *Radiology* 1999;211:395-397.