

# Exciting times: Towards a totally minimally invasive paediatric urology service

JOHN LAZARUS, M.B. CH.B., M.A., F.C.UROL. (S.A.), M.MED. (UROL.)

Division of Urology, Red Cross War Memorial Children's Hospital, University of Cape Town

## Summary

Following on from the first paediatric laparoscopic nephrectomy in 1992, the growth of minimally invasive ablative and reconstructive procedures in paediatric urology has been dramatic. This article reviews the literature related to laparoscopic dismembered pyeloplasty, optimising posterior urethral valve ablation and intravesical laparoscopic ureteric reimplantation.

*'These are exciting times to be a surgeon'* – Joseph Lister (1908)

Joseph Lister was the pioneer of antiseptic surgery (Fig. 1). In the late 19th century, postoperative sepsis accounted for the death of almost half of the patients undergoing major surgery.



Fig. 1. Sir Joseph Lister (1827 - 1912), the father of modern surgery.

Building on the work of Pasteur, Lister promoted the use of carbolic acid when operating. Antiseptic surgery became the norm and earned him the title 'Father of Modern Surgery'. Just as antiseptic surgery revolutionised what was possible then, so has laparoscopy positioned us in 'exciting times' today.

Urologists have admittedly been relatively late adopters of laparoscopy. Ironically, our beginnings as a specialty made minimally invasive surgery (MIS) possible via Max Nitze's invention, also in the late 19th century, of the cystoscope (Fig. 2). Nitze, a Berliner, 'established the specialty of urology and [has] a legitimate claim as the father of urology'. Nitze's genius lay in his lifelong pursuit of better methods to diagnose and treat patients with urological diseases and in teaching others the practical use and value of cystoscopy.<sup>1</sup>



Fig. 2. Max Nitze (1848 - 1906) and the cystoscope he invented.

MIS has revolutionised the surgery of genito-urinary disorders in children. While comparatively difficult technically, it is evolving from purely diagnostic and ablative procedures to challenging reconstructive surgery. The literature claims success rates similar to those of open surgery, but with the benefits of more delicate tissue handling, reduced postoperative pain and improved cosmesis. This paper focuses on three paediatric urological MIS procedures: dismembered pyeloplasty, posterior urethral valve ablation, and ureteric reimplantation.

### Dismembered pyeloplasty

Locally we have been slow to embark on laparoscopic pyeloplasty, as most prospective patients are young infants and Brock cautions that 'potential benefits of laparoscopic pyeloplasty may recede in younger age groups'.<sup>2</sup> Tan, in the earliest series of laparoscopic pyeloplasty, also warned against this technique in patients aged <6 months.<sup>3</sup> Nevertheless, more recent series have included infants, with good outcomes.<sup>4</sup>

Open pyeloplasty has an excellent track record with limited morbidity and a success rate of 90 - 100%.<sup>5</sup> Laparoscopically, the procedure has a steep learning curve and requires fine intracorporeal suturing. Other MIS options include endopyelotomy and retrograde techniques using the cutting Accusize balloon. The success of these two procedures is inferior to that of conventional open dismembered pyeloplasty.<sup>5</sup>

### Diagnosis and indications for surgery

Pelvi-uterine junction (PUJ) obstruction is the most common cause of hydronephrosis in children. About 1% of antenatal ultrasound scans detect hydronephrosis and half of these are secondary to PUJ obstruction. It is more common in boys with left kidney predominance, and 10 - 30% of cases are bilateral. Symptoms of PUJ obstruction are only seen in older children and include flank pain, mass, haematuria and pyelonephritis. Ultrasonography and a diuretic renogram are the investigations of choice. A micturating cysto-urethrogram (MCUG) is indicated in bilateral cases or where there is diagnostic doubt. Indications for surgery include pain, recurrent urinary tract infections, a renogram of <40% differential function or progressive hydronephrosis.

### Surgical technique

Peters, a pioneer of paediatric urological laparoscopy in the USA, performed the first laparoscopic pyeloplasty in a child in 1995.<sup>6</sup> Both trans- and retroperitoneal approaches are used. The latter provides a very limited working space, a video of which can be seen on the WebSurg website.<sup>7</sup>

In our series of 4 cases we have used the transperitoneal Anderson-Hynes pyeloplasty. All the patients have done well at a minimum of 6 months' follow-up, with stable renogram function and reduced pelvic diameter. One case was complicated by a prolonged urine leak that settled with drainage.

In laparoscopic pyeloplasty we have striven to mimic the open operation. Patients are placed in an open lateral decubitus position, catheterised and firmly strapped to the bed to allow tilting. We use the Bailez technique to establish a pneumoperitoneum at the umbilicus.<sup>8</sup> Triangulation is used for the remaining two 3 mm ports. The colon and duodenum are

reflected using the harmonic scalpel. While a transmesenteric approach is an attractive option on the left, we have not used it.<sup>9</sup> Careful dissection of the PUJ is done with hook cautery. A 'hitch stitch' stabilises the pelvis during the initial partial dimemberment and repair (Fig. 3). Particular attention is paid to spatulating the distal ureter until an adequate calibre is reached. A reduction pyeloplasty is done. The anastomosis is performed with continuous 5-0 Vicryl. All patients operated on laparoscopically had antegrade placement of a double-J stent,<sup>10</sup> although we do not use stents in open cases. Stent placement in the bladder must be confirmed using methylene blue instilled into the bladder or via cystoscopy. Reports of stentless laparoscopic pyeloplasty have been published.<sup>11</sup> A drain is placed; the 5 mm camera port is formally closed and only Steristrips are used for the 3 mm ports.

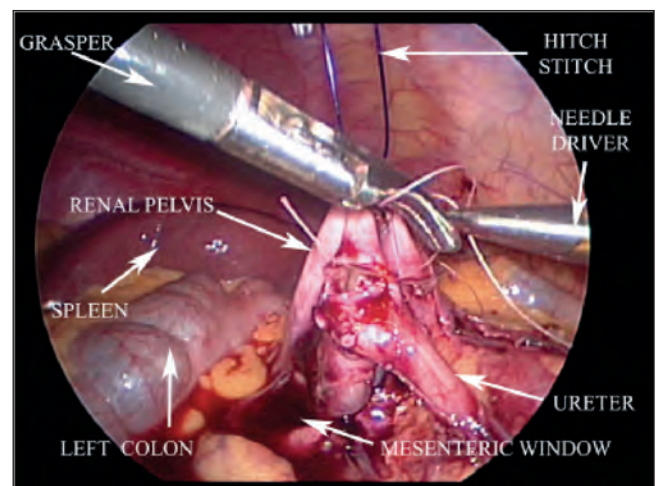


Fig. 3. Transperitoneal, trans-mesocolon dismembered pyeloplasty making use of the 'hitch stitch' (adapted from Casale<sup>21</sup>).

### Comparison with open pyeloplasty

Various published series of laparoscopic pyeloplasty have shown it to be comparable to the open operation, but it takes significantly longer.<sup>12</sup> The advantages are less pain, quicker convalescence and excellent cosmesis.

A preliminary report of a prospective randomised trial of laparoscopic versus open pyeloplasty in children has recently been published.<sup>13</sup> In a series of 20 patients laparoscopic pyeloplasty appeared to be a safe and effective alternative to open pyeloplasty.

### Posterior urethral valve ablation

Dewan of Melbourne has significantly rewritten the story of posterior urethral valves. His historical/anatomical study asserted that 'Young's original classification is incorrect' and proposed an embryological explanation for his new designation of 'congenital obstructive posterior urethral membrane' or COPUM.<sup>14,15</sup>

Dewan's later video-endoscopic study of COPUM also produced practice-changing information. By doing interval re-look cystoscopy, he demonstrated that '47% of those who had a severe COPUM required re-do fulguration'.<sup>16</sup> We have therefore moved away from post-ablation MCUG, preferring

re-do cystoscopy at 6 weeks and resection of any remaining valve tissue. The decision to omit the follow-up MCUG has been supported by data from the Great Ormond Street group.<sup>17</sup> They retrospectively reviewed the post-ablation MCUG in 31 boys and its value in predicting residual valve at re-look cystoscopy and concluded: 'We found repeat MCUG alone imprecise in excluding residual valve tissue and recommend check cystoscopy in all.'

A recent addition to the COPUM literature that also has an important impact on practice is that of bladder neck incision (BNI). In a well-controlled trial from Iran, 46 boys all had pre-ablation urodynamic (UDS) evaluation.<sup>18</sup> The UDS findings were used to assign the groups to undergo either ablation alone or ablation plus BNI. The endpoint of the study was UDS functioning at 5 years. The ablation plus BNI group had statistically superior urodynamic functioning. These data are compelling, and we now include a BNI at re-look cystoscopy.

BNI in this setting is not without its concerns,<sup>19</sup> which include retrograde ejaculation and incontinence, necessitating more trials before BNI becomes the standard of care. We have, however, been persuaded by the conclusions that the 'combination of BNI and PUV ablation seems to confer better bladder and (possibly) renal function outcomes compared to simple valve ablation'.<sup>19</sup>

## Ureteric reimplantation

The traditional modes of investigation and management of primary vesico-ureteric reflux (VUR) are undergoing dramatic revision. Called the 'prostate cancer' of paediatric urology, VUR has been over-investigated and perhaps in some cases over-treated.

Paquin first proposed that a short intramural ureteric tunnel accounted for 'lateral ectopia', and this is what we define as primary VUR.<sup>20</sup> It is estimated that as many as 8% of girls and 2% of boys will have a urinary tract infection (UTI) by the age of 7 years.<sup>21</sup> A third of these are associated with VUR.<sup>22</sup> In Africa the incidence of VUR is thought to be lower than this, as American data suggest that black children have a 10-fold lower VUR incidence than white children.

Traditional approaches to the investigation of VUR place emphasis on the MCUG in what has been termed the 'bottom up approach'. Evidence has accumulated that instead supports a 'top down approach'. Here renal status via nuclear imaging is prioritised. Fig. 4 illustrates our local investigation algorithm.

## Management of VUR

Traditionally VUR management required long-term antibiotic prophylaxis with open ureteric reimplantation reserved for failures of conservative treatment. This has undoubtedly resulted in over-treatment of some children, and raises the question of how to select the few children in whom surgery is appropriate.

Antibiotic prophylaxis provides marginal benefit for most children, particularly those with low-grade VUR.<sup>22</sup> The recently published Swedish Reflux Study has provided the most useful information for the surgeon caring for children with VUR.<sup>23</sup> The trial randomised 600 patients (66% girls) who had proven

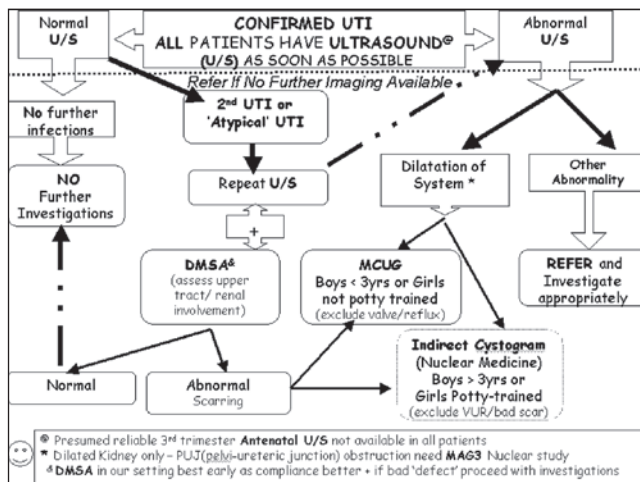


Fig. 4. Red Cross War Memorial Children's Hospital urinary tract infection investigation protocol. Emphasis is placed on the need to confirm a UTI before investigation and a renal ultrasound scan in all patients, but further imaging is reserved for those with abnormalities on the scan or recurrent UTIs.

dilating (grade 3 - 5) VUR to prophylaxis, surveillance alone or a STING (endoscopic ureteric bulking) procedure. Resolution of VUR at 2 years was 40%, 48% and 71% ( $p=0.0002$ ), respectively. UTIs recurred in 19%, 57% ( $p=0.0002$ ) and 23%, respectively. The authors concluded that STING or prophylaxis is better than surveillance. Both febrile UTIs and renal scars were more common in the surveillance arm, particularly in girls.

The Swedish Reflux Study is important, because unlike previous studies that compared antibiotics only with open surgery, it concluded that there is an important role for the STING procedure. Endoscopic treatment has good long-term results in preventing febrile UTIs. Stenberg followed up STING patients for 7 - 12 years after treatment and found a UTI incidence of only 3.4%.<sup>24</sup>

While endoscopic treatment is a good choice to prevent UTIs and resultant scarring, enthusiasm for the STING procedure in the developing world needs to be tempered by its cost. Hence there remains an ongoing role for open surgical reimplantation, particularly in Africa. Joe Cohen, originally of Johannesburg, pioneered what has become the most popular open reimplantation operation and the commonest of all operations performed by paediatric urologists in North America before the Food and Drug Administration approval of dextranomer/hyaluronic acid (Dx/HA) co-polymer (Deflux) in the last decade.<sup>25</sup>

Early attempts at laparoscopic Cohen cross-trigonal ureteroneocystostomy by Gill from the Cleveland Clinic produced mixed results.<sup>26</sup> While the extravesical approach (Lich-Gregoir) undoubtedly yields good results,<sup>27</sup> we have preferred the intravesical method, encouraged by the excellent results of Yeung.<sup>28</sup>

## Surgical technique

We follow the detailed technical description of Yeung.<sup>29</sup> Additionally, Valla's video is most useful.<sup>30</sup> We have performed four such laparoscopic transvesical pneumovesicium procedures. The key difficulty is maintaining port position in



the bladder. Yeung's traction suture is essential, as is the use of Covidien's STEP ports rather than standard ports. No balloon-tipped ports, which would be useful in this setting, are currently available in paediatric sizes.

## Conclusion

The spectrum of laparoscopic urological surgery in children has developed dramatically over the last decade. We are fortunate to practise in these 'exciting times' and to contribute to endeavours to further the role for minimally invasive surgery.

## REFERENCES

- Herr HW. Max Nitze, the cystoscope and urology. *J Urol* 2006;176(4, Pt 1):1313-1316.
- Brock JW 3rd. A comparison of open vs laparoscopic pediatric pyeloplasty using the pediatric health information system database – do benefits of laparoscopic approach recede at younger ages? *J Urol* 2008;180:1479-1485.
- Tan HL. Laparoscopic Anderson-Hynes dismembered pyeloplasty in children. *J Urol* 1999;162:1045-1047.
- Traxel EJ, Minevich EA, Noh PH. A review: The application of minimally invasive surgery to pediatric urology: upper urinary tract procedures. *Urology* 2010;76:122-133.
- Ahmed S, Crankson S, Sripathi V. Pelviureteric obstruction in children: conventional pyeloplasty is superior to endo-urology. *Aust N Z J Surg* 1998;68(9):641-642.
- Peters CA, Schluskel RN, Retik AB. Pediatric laparoscopic dismembered pyeloplasty. *J Urol* 1995;153:1962-1965.
- [http://www.websurg.com/ref/toc-Genitourinary-3\\_2\\_0\\_0\\_v.htm](http://www.websurg.com/ref/toc-Genitourinary-3_2_0_0_v.htm) (accessed 22 December 2010).
- Gonzalez R. Experience with the Bailez technique for laparoscopic access in children. *J Urol* 2003;170:936-938.
- Romero FR, Wagner AA, Kavoussi LR, et al. Transmesenteric laparoscopic pyeloplasty. *J Urol* 2006;176(6 Pt 1):2526-2529.
- Mandhani A, Goel S, Bhandari M. Is antegrade stenting superior to retrograde stenting in laparoscopic pyeloplasty? *J Urol* 2004;171(4):1440-1442.
- Kumar V, Mandhani A. Laparoscopic stentless pyeloplasty: An early experience. *Indian J Urol* 2010;26(1):50-55.
- Smaldone MC, Sweeney DD, Ost MC, Docimo SG. Laparoscopy in paediatric urology: present status. *BJU Int* 2007;100:143-150.
- Penn HA, Gatti JM, Hoestje SM, DeMarco RT, Snyder CL, Murphy JP. Laparoscopic versus open pyeloplasty in children: Preliminary report of a prospective randomized trial. *J Urol* 2010;184:690-695.
- Dewan PA, Zappala SM, Ransley PG, Duffy PG. Endoscopic reappraisal of the morphology of congenital obstruction of the posterior urethra. *Br J Urol* 1992;70(4):439-444.
- Dewan PA. Congenital obstructing posterior urethral membranes (COPUM): Further evidence for a common morphological diagnosis. *Paed Surg Int* 1993;8(1):45-50.
- Imaji R, Dewan PA. Congenital posterior urethral obstruction: re-do fulguration. *Pediatr Surg Int* 2002;18(5-6):444-446.
- Smeulders N, Duffy PG, Cuckow PM, Mushtaq I, et al. The predictive value of a repeat micturating cystourethrogram for remnant leaflets after primary endoscopic ablation of posterior urethral valves. *J Pediatr Urol* (in press).
- Kajbafzadeh A-M, Payabvash S, Karimian G. The effects of bladder neck incision on urodynamic abnormalities of children with posterior urethral valves. *J Urol* 2007;178:2142-2149.
- Bhandari M, Siva S. Re: The effects of bladder neck incision on urodynamic abnormalities of children with posterior urethral valves. *J Urol* 2008;179(6):2486-2487; author reply 2487-2488.
- Paquin AJ. Ureterovesical anastomosis: The description and evaluation of a technique. *J Urol* 1959;82:573-583.
- Craig JC, Simpson JM, Williams GJ, et al. Antibiotic prophylaxis and recurrent urinary tract infection in children. *N Engl J Med* 2009;361:1748-1759.
- Williams G, Fletcher JT, Alexander SI, Craig JC. Vesicoureteral reflux. *J Am Soc Nephrol* 2008;19:847-862.
- Holmdahl G, Brandström P, Läckgren G, et al. The Swedish Reflux Trial in Children: II. Vesicoureteral reflux outcome. *J Urol* 2010;184(1):280-285.
- Stenberg A. Commentary to 'Controversies in the management of vesicoureteral reflux. The rationale for the RIVUR study'. *J Pediatr Urol* 2009;5:344.
- Cohen SJ. Ureterozystoneostomie. Eine neue Antirefluxtechnik. *Akt Urol* 1975;6:1-7.
- Gill IS, Ponsky LE, Desai M, Kay R, Ross JH. Laparoscopic cross-trigonal Cohen ureteroneocystostomy: novel technique. *J Urol* 2001;166(5):1811-1814.
- Lakshmanan Y, Fung LC. Laparoscopic extravesicular ureteral reimplantation for vesicoureteral reflux: recent technical advances. *J Endourol* 2000;14(7):589-593; discussion 593-594.
- Yeung CK, Sihoe JD, Borzi PA. Endoscopic cross-trigonal ureteral reimplantation under carbon dioxide bladder insufflation: a novel technique. *J Endourol* 2005;19(3):295-299.
- <http://www.ncbi.nlm.nih.gov/pmc/articles/PMC2517844/> (accessed 21 December 2010).
- <http://www.websurg.com/ref/search-vdo1en2053.htm> (accessed 21 December 2010).
- Casale P. A review of pediatric laparoscopic pyeloplasty. *UroToday International Journal* 2009;2(1). doi:10.3834/uij.1944-5784.2008.12.09