

Preduodenal portal vein: A potential laparoscopic cholecystectomy nightmare

N. BHORAT, M.B. B.CH.

Department of Surgery, Nelson R Mandela School of Medicine, University of Natal, Durban

S. R. THOMSON, CH.M., F.R.C.S. (EDIN. & ENG.)

F. ANDERSON, F.C.S. (S.A.), M.MED.

Department of Surgery, Addington Hospital and Nelson R Mandela School of Medicine, University of Natal, Durban

Summary

Variations of biliary anatomy are well described. Those of most relevance to the operative surgeon are the variations of the extrahepatic ducts and their relationships to the right hepatic artery and its branches. We describe another even rarer congenital anomaly of a preduodenal portal vein. Its embryological derivation and presentation are discussed to heighten awareness of its recognition and reduce the potential of a serious operative misadventure.

Case report

A 45-year-old woman presented for an elective laparoscopic cholecystectomy following resolution of an episode of acute cholecystitis. She had well-controlled hypertension and diabetes. Her vital signs were unremarkable and an ultrasound scan confirmed cholelithiasis as the only abnormality.

At surgery a fibrotic shrunken gallbladder was found. During the dissection of Calot's triangle, the cystic duct was seen to disappear behind a 'blue' tubular structure that was traced inferiorly and seen to run anterior to the first part of the duodenum and then disappear into the retroperitoneum. The uncertainty of the anatomy resulted in the operation being converted to an open procedure. A Kocher incision was made and the finding of a preduodenal portal vein confirmed (Fig. 1). A cholecystectomy was performed. No other abnormalities of the foregut were identified. The patient subsequently made an uneventful recovery apart from minor wound sepsis.

Discussion

Preduodenal portal vein (PDPV) is a rare congenital anomaly first described in 1912 by Begg¹ in a pig embryo. In 1921 Knight² described this anomaly in a human for the first time, having seen it during an autopsy, and in 1926 Schnitzler³ was the first to operate on a case of duodenal obstruction caused by a PDPV. An understanding of the embryological development of the portal vein is essential in understanding how this anomaly may arise.

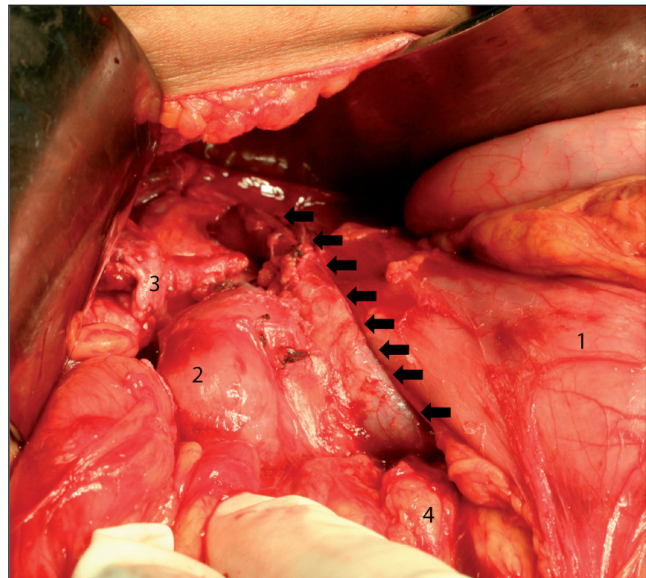


Fig. 1. Intraoperative picture. The PDPV is outlined by the black arrows. Also note the gallbladder neck disappearing underneath the portal vein (1 = stomach; 2 = duodenum; 3 = gallbladder; 4 = pancreas).

In the 5th week of embryological development, the left and the right vitelline (omphalomesenteric) veins are distinguishable as separate entities.⁴ These veins form a plexus around the duodenum before entering the sinus venosus (Fig. 2a). This plexus comprises three cross-anastomoses between the left and the right vitelline veins – the superior anastomosis within the liver, the middle anastomosis posterior to the duodenum, and the inferior anastomosis that lies preduodenal.

The 8th to 12th weeks of development see parts of this plexus atrophy (Fig. 2b). The superior and the inferior anastomosis atrophy, followed by the proximal part of the left and the distal parts of the right vitelline vein. This leaves the anastomotic network around the duodenum with one vessel, the portal vein. This vein lies posterior to the duodenum.

In order to explain the anomaly of a preduodenal portal vein, one of two possible events can occur (Figs 2b and 2c). Either the middle anastomosis atrophies and the inferior pre-

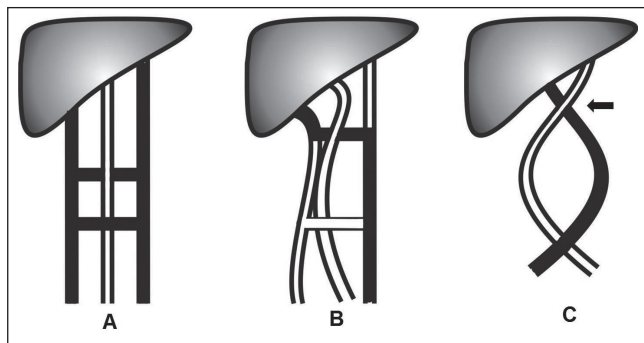


Fig. 2a. Schematic diagram of portal vein embryology. The left and right vitelline veins (coloured black) form a ladder-like cross-anastomosis around the primitive foregut seen in A. In B the middle posterior anastomosis remains patent (coloured black) and the remainder of the anastomosis atrophies, resulting in the normal posterior position of the portal vein (black arrow).

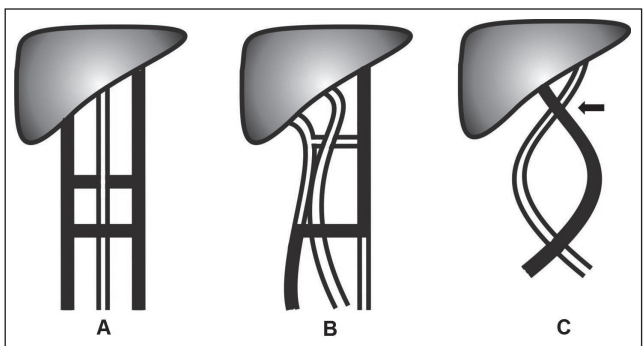


Fig. 2b. A schematic representation of PDPV development without malrotation. Note that the inferior preduodenal anastomosis remains patent (B) resulting in a pre-duodenal position of the portal vein (black arrow) (C).

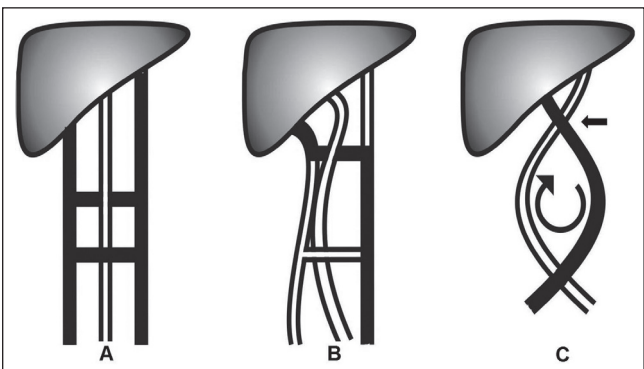


Fig. 2c. PDPV development with malrotation. Steps A and B are the same as in Fig. 2a; however, malrotation of the primitive gut results in a PDPV.

duodenal anastomosis remains patent, resulting in a preduodenal position of the portal vein, or the portal vein develops

normally but an associated malrotation of the foregut, e.g. situs inversus of the stomach and the duodenum, can result in a PDPV.

In our case there was no evidence of malrotation, so the preduodenal portal vein (PDPV) is most likely to have developed by means of the former process.

In 1974, Braun *et al.*⁵ reviewed the literature and found only 41 reported cases of PDPV from 1921 to 1974. Of those reported, 27 were in children younger than 10 years of age and 12 were in adults. In 2 cases the ages were unknown. Thirty-four (83%) of these cases were associated with other multiple congenital malformations. Intestinal malrotation was associated with 80% of these cases, situs inversus with 40%, pancreatic malformations with 33%, and biliary atresia, duodenal stenosis or atresia with 13%. In the majority of these cases it was the associated malformation and not the PDPV that was the primary reason for operative intervention.

Ishizaki *et al.*⁶ reviewed 11 cases, of which 6 were reported after Braun's 1974 review. Of these new cases, 4 had associated congenital anomalies; only one was symptomatic and presented with duodenal stenosis.

Other rare and interesting presentations of PDPV have been described. Snavelly and Breakell⁷ reported a patient with portal hypertension secondary to stenosis of a PDPV. This patient died from bleeding oesophageal varices. Bernard *et al.*⁸ reported a case with dual complications. This patient had duodenal stenosis and an anterior duodenal ulcer that penetrated the portal vein causing a massive upper gastrointestinal haemorrhage.

PDPV usually presents in the paediatric population as it is the associated congenital anomalies that draw attention to its presence.⁵ In adults it is usually asymptomatic and is an incidental finding at elective surgery for an unrelated condition.

As rare as PDPV may be, the surgeon has to be aware of its possible presence as injury to the portal vein can result in disastrous consequences. In our patient we resorted to open surgery, and we believe this to be the safest approach to delineate the abnormality and avoid inadvertent portal vein injury.

REFERENCES

1. Begg AS. Anomalous persistence in embryos of parts of peri-intestinal rings formed by vitelline veins. *Am J Anat* 1912; 13: 103-110.
2. Knight HO. An anomalous portal vein with its surgical dangers. *Ann Surg* 1921; 192: 174: 697-699.
3. Schnitzler J. Ueber Eine Cigentumliche 'Missbildung mit Stenosierung des Mlagenausgangs'. *Med Klin* 1926; 22: 723.
4. Sadler TW. *Medical Embryology*. 6th ed. Baltimore: Williams & Wilkins, 1990: 214-217.
5. Braun P, Collin PP, Ducharme JC. Preduodenal portal vein: A significant entity? Report of 2 cases and review of the literature. *Can J Surg* 1974; 17: 316-319.
6. Ishizaki Y, Tanaka M, Okuyama T. Surgical implications of preduodenal portal vein in the adult. *Arch Surg* 1994; 129: 773-775.
7. Snavelly JG, Breakell ES. Fatal hemorrhage from esophageal varices due to malformations and congenital stenoses in the portal venous system. *Am J Med* 1954; 16: 459.
8. Bernard LJ F, Perry A, Walker M. Preduodenal portal vein causing duodenal obstruction with bleeding duodenal ulcer: a case report. *Ann Surg* 1959; 150: 909-912.