

Laparoscopic repair of Morgagni diaphragmatic hernia in children

M. L. VAN NIEKERK, M.B. CH.B., M.MED. (SURG.), F.C.S. (S.A.)

Department of Paediatric Surgery, University of Pretoria

Summary

Minimal invasive surgery allows for excellent visualisation of the diaphragm, and is increasingly used for the repair of diaphragmatic hernias in children. This report describes laparoscopic repairs between 2001 and 2007 of four Morgagni hernias in children. All defects were treated successfully using the laparoscopic method, with no recurrences. The laparoscopic method is an ideal way to treat this type of diaphragmatic hernia.

Anomalies in the sternal insertion of the diaphragm result in congenital retrosternal diaphragmatic hernias. The defect is located on either side of the junction of the septum transversum and the thoracic wall. A defect to the right of the sternum is referred to as a Morgagni hernia, and one to the left as a hernia of Larrey.¹ There is no clinical difference between the two hernias, and the term Morgagni hernia is usually used for both.

Retrosternal hernias are uncommon and account for only 1 - 2% of all congenital diaphragmatic hernias.¹⁻³ Most hernias are asymptomatic and are discovered incidentally on chest X-rays. Although strangulation or incarceration is unusual, surgical treatment is recommended in all patients with Morgagni hernias, under elective conditions.^{1,4} These hernias can be closed primarily or a patch can be used. This study is a retrospective review of our experience of 4 laparoscopic repairs of Morgagni hernias.

Patients and methods

The patients were 2 boys and 2 girls whose ages ranged from 1 to 9 years (Table I). The hernias of 3 patients were diagnosed incidentally; in the fourth, the mother had complained about gurgling sounds in the child's chest. A primary repair in 3 patients was done with interrupted, non-absorbable sutures. One patient had a large defect, and a patch was necessary to close it.

Surgical technique

Primary repair

The patient was placed in a supine position at the foot of the bed, with the lower legs hanging over the edge. A 3-port technique was used. A 5 mm telescope was inserted through the umbilical port, and two 5 mm ports were placed to the right and left of the midline in the upper abdomen. The falciform ligament was separated from the anterior abdominal wall with a Ligasure to allow better visualisation of the hernia. In 2 patients, the transverse colon was reduced from the hernia sac (Fig. 1); the sac was easily everted and resected in all 4 patients, using the Ligasure. A 2.0 Ethibond (Johnson & Johnson) suture was passed through the abdominal wall, and then passed through the posterior wall of the hernia. The needle was cut off and removed through one of the ports. An Endoclose device (Tyco Medical; Mansfield, Mass.) was passed through the abdominal wall and grasped the end of the suture, which was then pulled to the outside. Between 4 and 6 sutures were used in each case. When all the sutures

TABLE I. CLINICAL DETAILS OF CHILDREN PRESENTING WITH MORGAGNI HERNIA

Patient	Age	Clinical presentation	Method	Operating time	Complications	Discharge
1	12 months	Nonspecific respiratory symptoms	PTFE patch	105 minutes		Day 4
2	9 years	Nonspecific respiratory symptoms	Primary suture	83 minutes		Day 2
3	12 months	Nonspecific respiratory symptoms	Primary suture	72 minutes	Port hernia	Day 2
4	24 months	Mother heard gurgling sounds in chest	Primary suture	76 minutes		Day 2

were placed, they were pulled up together (Fig. 2). The closure of the defect was visualised by laparoscopic camera. The intra-abdominal pressure was then lowered, and the sutures tied in the subcutaneous tissue.

Prosthetic patch technique

A 1 mm polytetrafluoroethylene (PTFE) patch (Gore Flagstaff A2) was used to close a large hernia in one patient. A 3-port technique was used. The vertical and horizontal diameters of the defect were measured, using a piece of suture. The patch was then cut to size so that it overlapped the edges of the defect by about 10 mm. It was then rolled up tightly and placed into the abdomen through the right 5 mm working port. The patch was unrolled and the four corners were sutured first, using 2.0 Ethibond. Additional sutures were then placed to close the remaining open spaces.

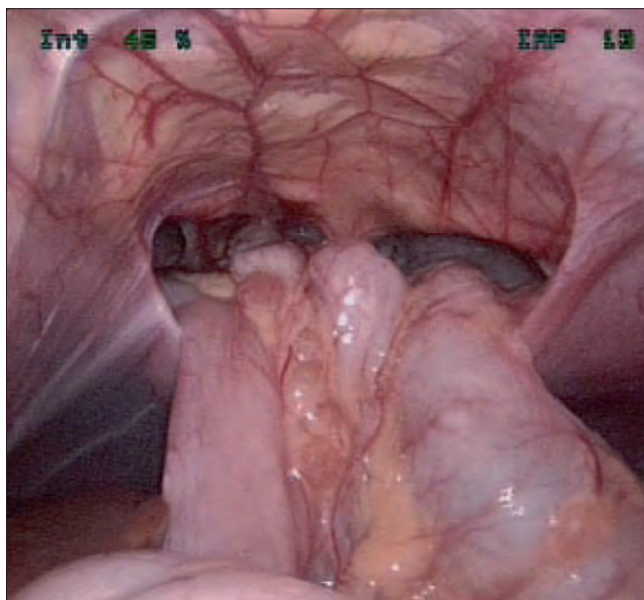


Fig. 1. Laparoscopic view of transverse colon in Morgagni hernia.

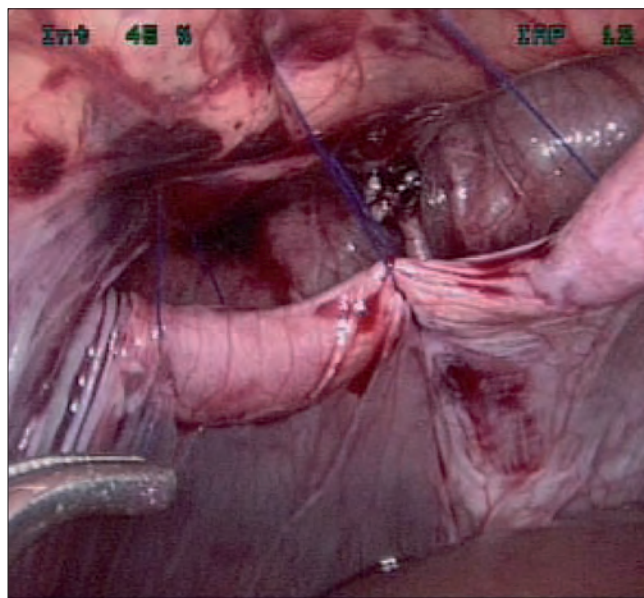


Fig. 2. Interrupted sutures before tying.

Results

All the operations were completed successfully, with no intra-operative complications. The operative times ranged from 72 to 105 minutes, with an average time of 84 minutes. The first patient was discharged on the 4th postoperative day. This was the first laparoscopic Morgagni hernia repair in South Africa. The first article in the literature on a laparoscopic patch repair, as used in this patient, was published only 2 years later.⁵ The other 3 patients were all discharged on the 2nd postoperative day. Chest X-rays of all 4 patients were taken after a month; all were normal. Follow-up has been from 24 to 88 months. One patient developed a port hernia, which was repaired 3 months after the initial hernia repair. All 4 patients are currently asymptomatic, without any chest wall deformity.

Discussion

Giovanni Morgagni, an 18th-century anatomist, together with Dominique Larrey, Napoleon's war surgeon, gave the name to this type of diaphragmatic hernia, known as the Morgagni-Larrey hernia.⁶ It is a retrosternal hernia, covered with a sac in almost all cases. The contents of the hernia typically include the colon, small bowel, omentum and sometimes part of the liver. Retrosternal hernias are more common in children with Down's syndrome.⁷

A Morgagni hernia is mostly discovered incidentally, but is more symptomatic in children with a risk of incarceration and strangulation.³ The diagnosis is usually made incidentally from a chest X-ray (Fig. 3). A barium swallow or contrast

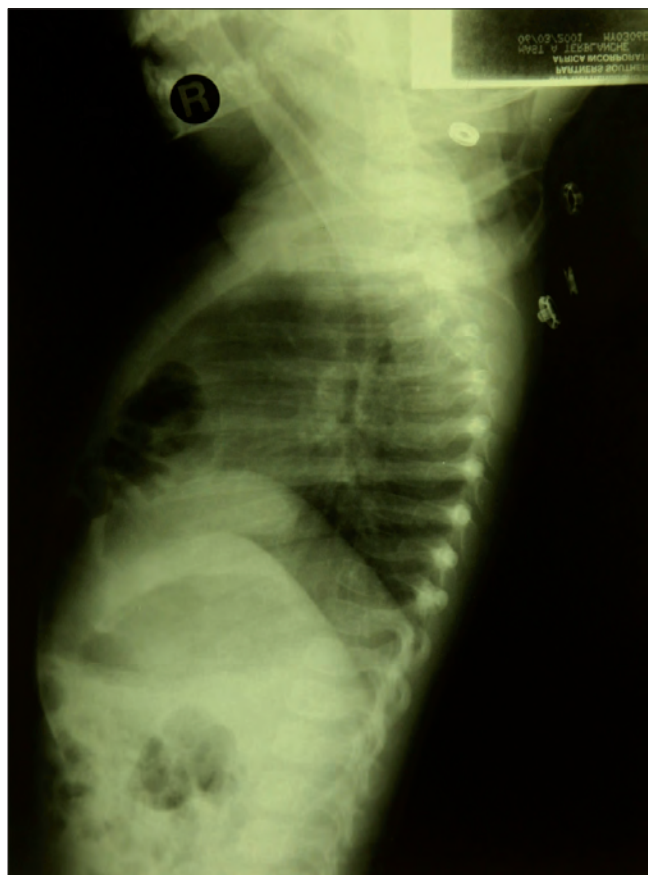

Fig. 3. Lateral chest X-ray showing bowel in a Morgagni hernia.

enema can confirm the presence of the colon or small bowel in this hernia. A computed tomography (CT) scan or magnetic resonance imaging (MRI) scan may provide additional information about the size of the hernia, its relationship to adjacent structures, and the contents of the hernia.⁸

Surgery of these hernias is necessary even if they are asymptomatic, to prevent future complications. The minimal invasive approach continues to gain popularity, and the Morgagni hernia is ideally suited for this method. In recent years, various reports have been published on the use of minimal invasive surgery to repair these defects. The techniques used were either primary closure with interrupted, non-absorbable sutures, or the use of a prosthetic patch.^{2,5,9}

In our first patient, a 1 mm polytetrafluoroethylene (PTFE) patch (Gore Inc.; Flagstaff, AZ) was used to bridge the defect in a large Morgagni hernia. Primary suture closure, using the full-thickness anterior abdominal approach, was done in the other 3 patients with Morgagni hernias. There are many variations on the technique of primary closure, but we find this method easy to perform and well tolerated by patients. The fact that the transverse diameter of a Morgagni hernia is substantially more than its anteroposterior diameter makes this hernia amenable to this technique.²

The choice between resecting and leaving the hernia sac is controversial. Some surgeons prefer to leave the sac because of the risk of complications such as tension pneumothorax, bleeding or pleural or pericardial injuries. Liquid accumulation in the sac may occur postoperatively, but it seems that this resolves over time.¹ Although there is a theoretical risk of cyst formation from the retained intrathoracic sac, there is no evidence in the literature to support this. In all cases, we were able to pull the sac down gently with grasping forceps and

remove it with the Ligasure. However, one should not remove the sac at all costs if dense adhesions prevent its inversion.

We feel that laparoscopic repair is the ideal method to repair Morgagni hernias. The laparoscopic technique allows an excellent view of the surgical field once the falciform ligament is split. Suturing the posterior rim of the defect to the full thickness anterior abdominal wall is our method of choice. Patches are seldom necessary but are sometimes used in large hernias, especially in older children.

In conclusion, minimal invasive surgery is the treatment method of choice for Morgagni hernia. The operating time is as quick as the open method, and it is easy to perform. It has a low morbidity, and the cosmetic result is excellent.

REFERENCES

1. Korkmaz M, Geiveng H. Minimal access surgical repair of Morgagni hernia: The fate of the unresected sac. *J Lap Adv Surg Tech* 2007; 17: 833-836.
2. Azzie G, Maoate K, Beasley S, et al. A simple technique of laparoscopic full-thickness anterior abdominal wall repair of retrosternal (Morgagni) hernias. *J Ped Surgery* 2003; 38: 768-770.
3. Lima M, Domini M, Libri M, et al. Laparoscopic repair of Morgagni-Larrey hernia in a child. *J Ped Surgery* 2000; 35: 1266-1268.
4. Kiiç D, Nadir A, Döner E, et al. Transthoracic approach in surgical management of Morgagni hernia. *Eur J Cardiothorac Surg* 2001; 20: 1016-1019.
5. Arca MJ, Barnhart DC, Lelli JL, et al. Early experience with minimally invasive repair of congenital diaphragmatic hernias: Results and lessons learned. *J Ped Surgery* 2003; 38: 1563-1568.
6. Zani A, Cozzi D, Giovanni Battista. Morgagni and his contribution to pediatric surgery. *J Ped Surg* 2008; 43: 729-733.
7. Stafford PW. Thoracoscopy for disorders of the diaphragm. *Ped Endosurg Innov Tech* 2001; 5: 175-181.
8. Percivale A, Stella M, Durante V, et al. Laparoscopic treatment of Morgagni-Larrey hernia: Technical details and report of a series. *J Lap Adv Surg Tech* 2005; 15: 303-307.
9. Knight CG, Gidell KM, Lanning D, et al. Laparoscopic Morgagni hernia repair in children using robotic instruments. *J Lap Advanced Surg Tech* 2005; 15: 482-486.